

NADİR BİR OLGU SUNUMU: PRİMER SKROTAL LİPOM

REPORT OF A RARE CASE: PRIMARY SCROTAL LIPOMA

Cem Nedim YÜCETÜRK¹, Muhammet Fatih KILINÇ¹, Berat Cem ÖZGÜR¹, Elif ÖZER², Ali AYYILDIZ¹

¹Department of Urology, Ankara Training and Research Hospital

²Department of Pathology, Ankara Training and Research Hospital

Ankara Eğt. Arş. Hast. Derg. (Med. J. Ankara Tr. Res. Hosp.) Cilt / Volume: 52 Sayı / Number: 1 Yıl / Year: 2019 ISSN:1304-6187 Sayfa/Page :90-92

Geliş Tarihi / Submitted : Ocak 2018 / January 2018

Kabul Tarihi / Accepted : Şubat 2019 / February 2019

ABSTRACT

Intrascrotal primary lipomas, arising from the subcutaneous adipose tissue of the scrotal walls, are rarely seen and vary in size. Here our aim was to present a patient with painless mass on the left scrotum diagnosed primary scrotal lipoma histopathologically.

Key Words: Extratesticular lipoma, scrotal lipoma, scrotal mass, scrotal swelling

ÖZET

İntraskrotal lipomlar skrotum duvarının subkutan yağ dokusundan köken alır. Nadir görülür ve değişik boyutlarda olabilir. Burada sol skrotumda ağrısız şişliği olan ve histopatolojik olarak primer skrotal lipom tanısı alan bir hastayı sunmayı amaçladık.

Anahtar Kelimeler: Ekstratestiküler lipom, skrotal lipom, skrotal kitle, skrotal şişlik

INTRODUCTION

Lipomas have usually occurred in the scrotum and especially originate and develop in the spermatic cord. But sometimes lipomas arise from adiposites of the subcutan tissues of the scrotal walls and called as primary scrotal lipoma(1). Intrascrotal primary lipoma is a benign mesenchymal tumour and its size is variable. We present here a patient with a three-year history of a painless left-sided scrotal mass which was reported as primary lipoma of the scrotum.

CASE

A 41 year-old man was referred to our outpatient clinic with the complaint of a swelling on the left scrotal region of three years duration. The swelling continuously started growing the last four months. The patient had no history of trauma to the scrotum, nausea, vomiting, constipation or heavy weight lifting. Physical examination revealed that the patient had an elastic, soft, single and regularly shaped mass on the left scrotum of size 9x5x7 cm. The mass had no tender or fluctuation and it was not possible to reduce. Detailed examination showed that it was found only in the scrotum and not extending to the left testicle. Both testicles and spermatic cords were normal. Considering that mass could be a malign testicle tumour, tumour markers such as beta human chorionic gonadotropin

(β HCG) and alpha fetoprotein(α FP) were required and viewed as normal. The patient's laboratory results were within normal limits. Scrotal ultrasonography revealed a heterogeneous hyperechoic mass of ~6-7 cm in size, isoechoic with adipose tissue and was standing apart from the left testicle.

Following an informed consent from the patient, we performed an operation using a left scrotal incision. A well encapsulated lipoma located within the scrotal wall was observed and dissected easily (Fig 1a,1b,1c). After the hemostasis, a penrose drain was placed insitu and layers were closed in anatomical plan.

The pathology report revealed benign scrotal lipoma with regular capsule. The dissected specimen weighed 250 gr. On macroscopic pathological examination, an encapsulated mass measuring 9x5x7 cm with yellow coloured and uniform fatty cut surface with lobulated pattern were observed. Microscopic report stated the specimen as primary scrotal lipoma surrounded with fibrous capsule, consisting of mature adipose cells and fibrous septation between them (Fig 2a,2b,3).

DISCUSSION

Lipomas are benign neoplasms and most commonly occurred in intrascrotal tissues and spermatic cord(1).

Sorumlu Yazar / Corresponding Author:

Cem Nedim YÜCETÜRK

Sukriye Mahallesi, Ulucanlar Caddesi, Ankara, Turkey

Tel: +90 312 595 37 09 Gsm: +90 532 257 69 67 Faks: +90 312 363 33 96 E-posta: tuncal@mynet.com

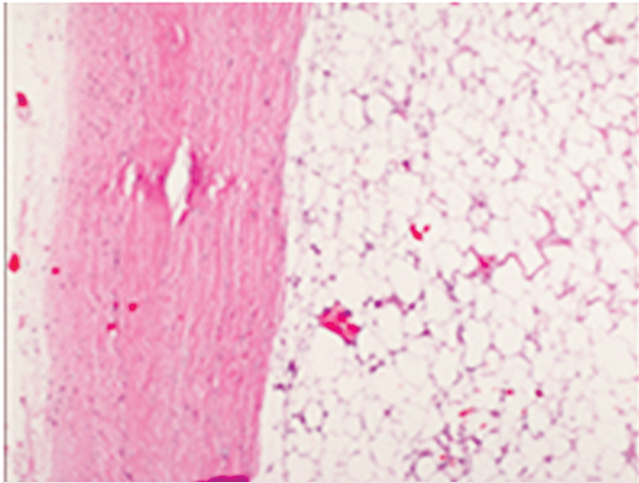
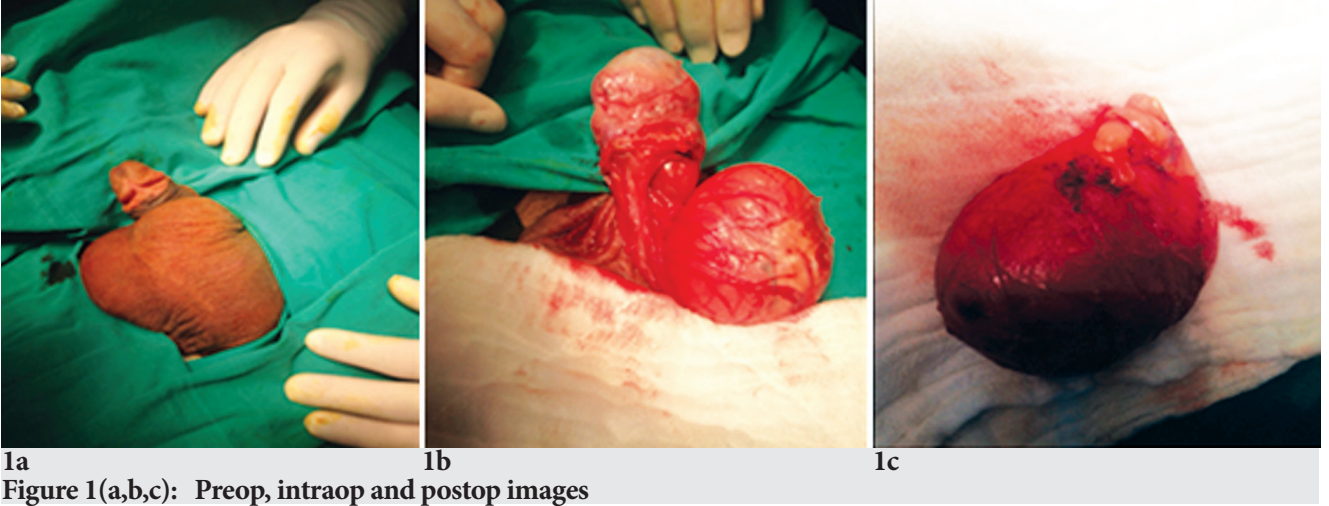


Figure 2 (a,b): Lipoma surrounded by fibrous capsule (H&E stain, 50x, 100x)

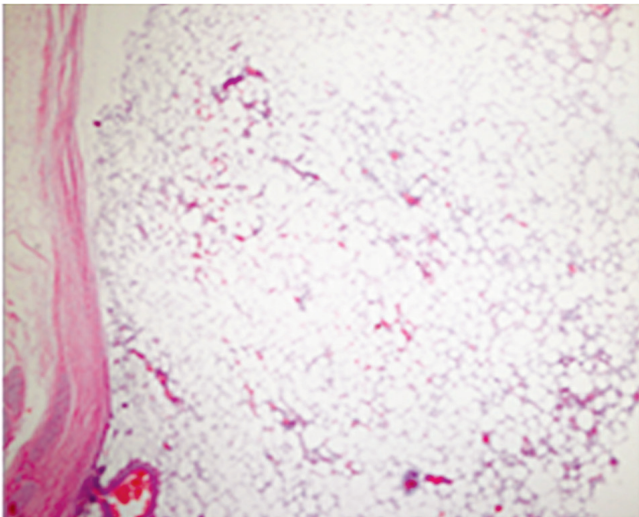
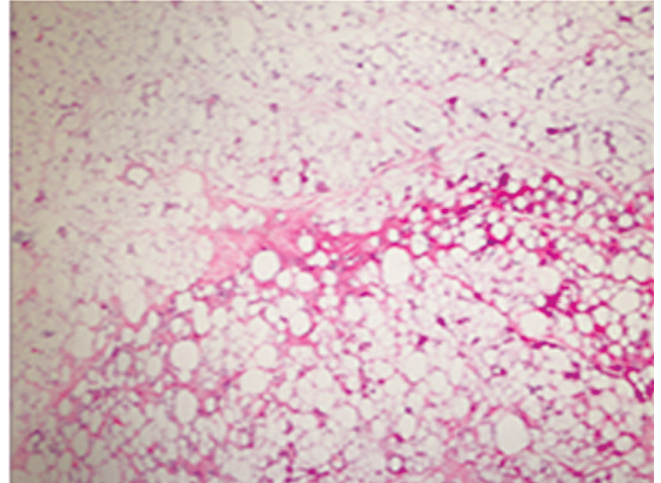


Figure 2 (a,b): Lipoma surrounded by fibrous capsule (H&E stain, 50x, 100x)

Leyson et al divided these tumours into two categories (paratesticular and extratesticular) with many subgroups, according to their location(2). Paratesticular lipomas arise from spermatic cord, epididymis, tunica vaginalis and testicle, while extratesticular lipomas are from a) properitoneal, preperitoneal or subperitoneal fat herniation, b) subserous fat around inguinal ring, fascia and transversalis muscle of perineal area, c) perineum and isolated fat lobules from subcutaneous tissue of the scrotal wall (2,3). However this classification seems to be difficult to replace a case of a lipoma in one of these categories. Fujimura et al. have been reported three types of intrascrotal lipomas that might help to overcome this situation. Scrotal lipomas originating from a) the subcutaneous tissue posterior to the spermatic cord and growing towards the scrotum, b) spermatic cord and tunica vaginalis tumours arising from the fat tissue within or outside the spermatic cord and c) primary scrotal lipomas arising from fat lobules of the tunica dartos layer of the scrotum which are rarely seen(4). From our opinion, this classification is much more easier

to place our case and in this context, our case could be classified as a primary scrotal lipoma. Size of the primary scrotal lipomas are highly variable and may become quite large (225g to 9 kg)(2). Our specimen was 250 g and compatible with the data from the literature.

Lipoma is being the most common tumour of the extratesticular structure, generally arise from the spermatic cord and is usually benign(5). They are mimicing clinically inguinal hernias but by observing an intact external inguinal ring on physical examination, the differential diagnosis is made very easily.

Scrotal ultrasonography, computerizing tomography (CT) and magnetic resonance imaging (MRI) scan play an important role in the evaluation of scrotal masses. Ultrasonography determines the localization of the mass and detects whether the appearance of the mass is cystic or solid nature. Although the most of solid extratesticular masses are benign, malignancy should be distinguished in such cases that when a mass can not be shown to be a lipoma. When determining any painless echogenic mass with heterogeneous structure on ultrasound and a relatively low vascularity, we should suspect from a liposarcoma and have to be much more careful(6). CT and MRI imaging are useful techniques in difficult cases especially to find out the difference between fat and other soft tissue components and simultaneously ruling out true lipoma and omental herniae (7).

The histopathology of primary scrotal lipoma can be confused with lipomatosis, lipoblastoma and liposarcoma. Lipoblastoma is generally seen in early childhood. Lipomatosis may induce proliferation of nature adipose tissue and infiltration to surrounding tissues whereas the lipomas are encapsulated . Although primary scrotal liposarcoma is rare, sometimes lipoma like well-differentiated liposarcoma can be seen and the diagnosis is complicated(8).

Scrotal or combined scrotal and inguinal incision seems to be the best treatment approach in these cases. Although many extratesticular lesions are benign, when masses are large, heterogeneous and infiltrate other scrotal structures, sarcomas must be kept in mind and all efforts have to be focused on this malignancy.

CONCLUSION

When evaluating a scrotal mass, a careful history and physical inguinoscrotal examination are essential. For all scrotal masses, such important requirements like serum tumour markers, a scrotal ultrasound and a specialist consultation must be done not to miss any details.

Acknowledgement: None

Conflict of Interest: None

No competing financial interests exist.

REFERENCES

- 1.)Karandikar S,Ansari S, Shaikh T, Mandhane N, Deolekar S. Rare paratesticular lipoma:The largest one reported till date. Int J Res Med Sci 2015;3: 1798-1800
- 2.)Florante J, Leyson J, Doroshow LW, Robbins MA. Extratesticular lipoma: report of 2 cases and a new classification. J Urol 1976 ;116: 324-326
- 3.)Greeley DJ Jr1, Sullivan JG, Wolfe GR. Massive primary lipoma of the scrotum. Am Surg 1995; 61:954-955.
- 4.)Fujimura N, Kurokawa K. Primary lipoma of the scrotum. Eur Urol 1979;5:182-183.
- 5.)Maximilian B, Joachim T, Sebastian M. Liposarcoma of the spermatic cord: Report of two cases and review of the literature. Internet Journal of Urology 2005;3:1
- 6.)Cardenosa G, Papanicolaou N, Fung CY, Tung GA, Yoder IC, Althausen AF, Shipley WU. Spermatic cord sarcomas: sonographic and CT features. Urol Radiol 1990;12:163-167.
- 7.)Patel NG, Rajagopalan A, Shrotri NS. Scrotal liposarcoma - a rare extratesticular tumour. JRSM Short Rep 2011; 2:93
- 8.)Lander EB, Lee I. Giant scrotal lipomatosis. J Urol 1996; 156:1773.