



Kinking; A Rare Complication of Sleeve Gastrectomy

Sleeve Gastrektominin Nadir Tanımlanan Bir Komplikasyonu; Kinkleşme

Mutlu Ünver¹, Türker Karabuğa², Şafak Öztürk¹, İsmail Özsan¹, Zafer Önen¹, Ünal Aydın³

¹İzmir Medicalpark Hospital, General Surgery Department; ²İzmir Sada Hospital, General Surgery Department, İzmir;

³Gayrettepe Florence Nightingale Hospital, General Surgery Department, İstanbul, Turkey

ABSTRACT

Aim: Our aim was to emphasize an uncommon complication of sleeve gastrectomy.

Material and Method: Sixty-two morbidly obese patients underwent laparoscopic sleeve gastrectomy. All patients were required to have psychological, routine laboratory examination, upper gastrointestinal endoscopy, pulmonary function studies and a medical evaluation. All patients were preoperatively evaluated by a dietician. The procedure was performed by a standard technique.

Results: A total of 62 patients (43 females, 19 males) underwent laparoscopic sleeve gastrectomy. Four of the 62 patients (1 male, 3 female) were admitted with a complaint of nausea, vomiting and liquid intolerans 7 to 10 days after discharge. Upper gastrointestinal contrast swallow study revealed "Kinking" of the remnant stomach.

Conclusion: Kinking is a complication to be known and rather than management, prevention of this complication must be supplied by further efforts.

Key words: kinking; sleeve gastrectomy; vomiting; complication

ÖZET

Amaç: Bu çalışmadaki amacımız sleeve gastrektominin nadir görülen bi komplikasyonuna vurguda bulunmaktır.

Materyal ve Metot: Laparoskopik sleeve gastrektomi uygulanan 62 hastanın tamamına; psikiatri konsültasyonu, rutin biyokimya ve endokrinolojik testler, üst gastrointestinal sistem endoskopisi ve pulmoner fonksiyon testleri uygulandı. Standart cerrahi teknik uygulandı.

Bulgular: 62 (43 kadın, 19 erkek) hastamızın tamamına sleeve gastrektomi uygulandı. Hastalarımızdan 4 (1 erkek, 3 kadın)'ü ameliyat sonrası 7. ve 10. günler arasında bulantı, kusma ve sıvı alım intoleransı ile başvurdu. Hastalara uygulanan oral kontrastlı skopi-lerde kinkleşme olduğu saptandı.

Sonuç: Kinkleşme sleeve gastrektomi için bilinmesi gereken bir komplikasyondur. Postoperatif dönemde bu komplikasyonun yönetimi yerine engellemeye çalışılması gerekmektedir.

Anahtar kelimeler: kinkleşme; sleeve gastrektomi; kusma; komplikasyon

Introduction

Laparoscopic sleeve gastrectomy (LSG), also known as longitudinal or vertical gastrectomy, is a relatively new and effective surgical option for the management of morbid obesity. Laparoscopic sleeve gastrectomy was subsequently found to be effective as a single procedure for the treatment of morbid obesity¹. Although LSG functions as a restrictive procedure, it may also cause early satiety by removing the ghrelin-producing portion of the stomach².

The known complications of this procedure can be divided into two subgroups as acute and chronic complications. Acute complications are bleeding, staple line leak and abscess, chronic complications are stricture, nutritional deficiencies and gastroesophageal reflux disease (GERD).

Here we aimed to emphasize a complication which is avoided to define and based on four of our patients, a literature review was made up.

Material and Method

Between March 2010 and September 2011, sixty-two morbidly obese patients underwent laparoscopic sleeve gastrectomy in our surgical department. The patients' demographic data is given in Table 1. All patients were required to have psychological screening, routine laboratory examination, electrocardiogram, upper gastrointestinal endoscopy, pulmonary function studies and a medical evaluation. All patients were preoperatively evaluated by a dietician and also by related specialties based on their individual needs. All patients were scheduled for sleeve gastrectomy as a primary definitive procedure. Informed consent was provided by all patients and laparoscopic sleeve gastrectomy was performed as described in surgical technique section.

Table 1. Patient demographics

Patients	Female	Male
n (62)	43 (% 69.3)	19 (% 30.7)
Median age: years (range)	39.6 (25–58)	43.3 (27–62)
Median BMI: kg/m ² (range)	44.6 (38–55)	46.9 (41–58)

Surgical technique

the patients are placed in a steep reverse Trendelenburg position with the surgeon standing between the legs, the camera surgeon on the left, and the assistant surgeon to the right of the primary surgeon. The first 10 mm trocar is inserted by camera guided blunt dissection and carbon dioxide pneumoperitoneum is done at a pressure of 15 mmHg. A Nathanson liver retractor (Cook Incorporated, Bloomington, IN, USA) is placed through the epigastric port and the left lateral segment of the liver is elevated. Additional three trocars were positioned in the usual manner. Using a 10-mm LigaSure device (Covidien), the greater curvature of the stomach was mobilized, starting from a point 6 cm proximal to the pylorus, staying close to the wall of the stomach all the way up the greater curvature to the angle of His.

It is important to identify and mobilize the angle of His with exposure of the left crus of the diaphragm to facilitate the complete resection of the fundus. Once the stomach was completely mobilized, a 32-French orogastric tube was inserted orally into the pylorus. This calibrated the size of the gastric sleeve, prevented constriction at the gastroesophageal junction and provided a uniform shape to the entire stomach. Gastric transection was started at a point 6 cm proximal to the pylorus, leaving the antrum and preserving gastric emptying. We staple the greater curvature strictly along the stomach tube using a 60-mm Endo-GIA stapler (Ethicon Endo-Surgery). The starting point is 5–6 cm prepyloric to the point of the angle of His. It is important to inspect the stomach anteriorly and posteriorly to ensure that there is no redundant posterior stomach. Typically, four to five staple-lines are needed. The dissected part of the stomach is withdrawn from the left lateral 15 mm trocar. The possible areas of bleeding are clipped by 10 mm medium size laparoscopic clip. Intraoperative leak test was employed with methylene blue. Closed suction drains were routinely used. An upper gastrointestinal

contrast swallow study with Gastrographin was performed on postoperative day 1 (Fig. 1), and if it was negative, the patient was put on liquid diet. Patients were discharged on postoperative day 3 or 4.

Results

A total of 62 patients (43 female, 19 male) underwent laparoscopic sleeve gastrectomy between March 2011 and September 2012. There were no need for conversion to open surgical procedure. Patients were discharged on postoperative day 3 or 4. There was no perioperative mortality. Four of the 62 patients (1 male, 3 female) were admitted with a complaint of nausea, vomiting and liquid intolerans 7 to 10 days after discharge from hospital. The patients were hospitalized, oral fluid and food intake was stopped and parenteral nutrition was admitted. Upper gastrointestinal contrast swallow study revealed “Kinking” of the remnant stomach (Fig. 2). Kinking can be defined as the organo-axial rotation due to the laxation of the stomach with the greater curvature moving inferior over antrum. Non operative observation were decided and after three days of conservative treatment with fluid resuscitation, a control contrast study was carried out and the passage of the contrast to the duodenum was verified. Oral liquid intake was started and four of the patients were discharged on fourth day of the rehospitalization. A slight intolerans to liquids continued for two or three months but the patients were adapted and no endoscopic or surgical intervention was carried out for this complication.

Discussion

Laparoscopic sleeve gastrectomy was initially described as the first step of a staged procedure for super morbidly obese patients followed by biliopancreatic diversion with duodenal switch or laparoscopic Roux-en-Y gastric bypass (LRYGB)^{3,4}. It has been reported in many studies as an excellent procedure for weight loss and resolution of comorbidities^{5,6}. Some of the benefits of LSG over other procedures are; because the intestinal passage is still intact after LSG endoscopy of the remaining stomach and access to the duodenum is still possible, the risk of internal hernias is absent. In case of insufficient weight loss, LRYGB or biliopancreatic diversion with duodenal switch can be performed as a second-stage procedure. However, LSG is not free of complications. The most frequent complications are leaking, hemorrhage, abscess,

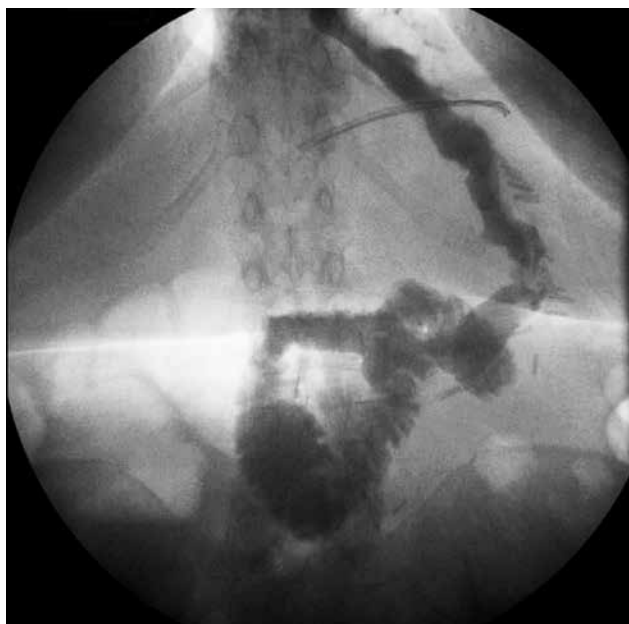


Figure 1. Contrast swallow study on postoperative day 1.

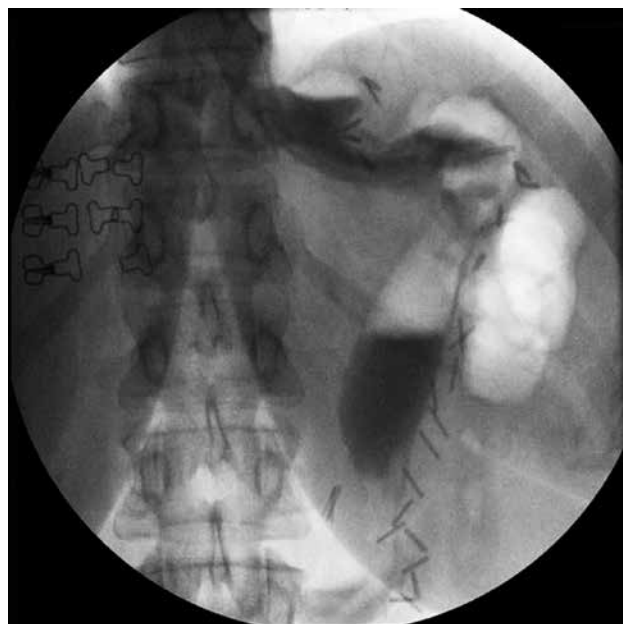


Figure 2. Contrast swallow study demonstrating the 'kinking'.

splenic injury, sleeve stenosis, and GERD. Fridman et al. reported a study consisting 2199 bariatric procedures and 619 of them was LSG. They reported a leak rate of 0.3% and 1.8% of complication or failure related reoperations. Stenosis was found to be the most common reason of reoperation in LSG group. The other complications were hiatal hernia, weight regain and leakage⁷. In a prospective randomized trial⁸, the complication rate was found to be 8.4% among 107 patients of LSG. There was no leak or bleeding but a severe obstruction which required reoperation. Other complications such as dysphagia and GERD was classified as minor complications. Noel et al. proposed a 3 port technique for LSG among 750 consecutive patients. The complication rate was 4.8% overall. The rate of leak was 2.4% in their whole series (18 cases). Hematoma and stricture were the other observed complications. They did not mentioned any minor or different complications such as liquid intolerance, dysphagia vs. in their study⁹. Kueper et al. described the preliminary early results of their study over 16 LSG procedure. Only two patients, one with wound infection and the other with bleeding requiring relaparoscopy, had complications¹⁰.

The most common surgical emergencies after bariatric surgery were reviewed by Companile et al¹¹. The data of this review confirmed that the suture line leakage

rate ranges between 0.7 and 7% depending on the series and the patient characteristics¹². Midgastric stenosis was another complication of LSG with an incidence of 0.7–4% due to calibrating on a too narrow tube or over sewing of the staple line¹³. Postoperative hemorrhage and staple line leakage are reported to be the major and GERD to be minor complication by Mittermair et al.¹⁴. Weiner et al. described the early postoperative complications in a retrospective study consisting of 686 LSG procedure. Complication rate was 7.14% (49/686). The most common complications were reported to be staple line leakage and bleeding. Elevated inflammatory markers, respiratory complications, wound infections, intolerans to oral fluids and trocar site hernia were less common complications. Postoperative dysphagia and fluid intolerance were managed by oral corticosteroid preparations for subsequent follow-up¹⁵. Although there are some uncommon complications reported in the literature. Alharbi described a case of gastrobronchial fistula which occurred in late period after laparoscopic sleeve gastrectomy¹⁶. Del Castillo Dejardin et al. described an unusual case of gastric volvulus after sleeve gastrectomy¹⁷. They mentioned that sleeve gastrectomy leaves the stomach with no fixations along the entire great curvature, which may predispose to volvulus. As this complication were not reported

before they could not recommend any maneuver to fix tubularized stomach. As seen in the literature review the most common severe complications are bleeding, staple line leakage and stricture. Besides that there are various problems observed postoperatively called as minor complications. We especially aimed to emphasize the 'liquid intolerance' symptom. It is usually recognized as a simple symptom but according to our opinion it can be the first sign of 'kinking' and must be verified with a contrast swallow study. It does not life threatening but impairing the quality of life. Knowledge of the type of bariatric procedure performed and the post-surgical anatomical variations of the gastro-intestinal tract is key to the management of patients presenting with postoperative complications. Further efforts and studies are needed to avoid 'kinking' rather than the postoperative management.

References

1. Moon Han S, Kim WW, Oh JH. Results of laparoscopic sleeve gastrectomy (LSG) at 1 year in morbidly obese Korean patients. *Obes Surg* 2005;15:1469–75.
2. Gumbs AA, Gagner M, Dakin G, Pomp A. Sleeve gastrectomy for morbid obesity. *Obes Surg* 2007;17:962–9.
3. Regan JP, Inabnet WB, Gagner M, Pomp A. Early experience with two-stage laparoscopic Roux-en-Y gastric bypass as an alternative in the super-super obese patient. *Obes. Surg* 2003;13:861–4.
4. Lee CM, Cirangle PT, Jossart GH. Vertical gastrectomy for morbid obesity in 216 patients: report of two-year results. *Surg Endosc* 2007;21:1810–16.
5. Trieu HT, Gonzalvo JP, Szomstein S, Rosenthal R. Safety and outcomes of laparoscopic gastric bypass surgery in patients 60 years of age and older. *Surg Obes Relat Dis* 2007;3:383–6.
6. Arias E, Martinez PR, Li VKM, Ka Ming Li V, Szomstein S, Rosenthal RJ. Mid-term follow-up after sleeve gastrectomy as a final approach for morbid obesity. *Obes Surg* 2009;19:544–8.
7. Fridman A, Moon R, Cozacov Y, Ampudia C, Lo Menzo E, Szomstein S, et al. Procedure-Related Morbidity in Bariatric Surgery: A Retrospective Short- and Mid-Term Follow-Up of a Single Institution of the American College of Surgeons Bariatric Surgery Centers of Excellence. *J Am Coll Surg* 2013;217(4):614–20.
8. Peterli R, Borbely Y, Kern B, Gass M, Peters T, Thurnheer M, et al. Early Results of the Swiss Multicentre Bypass or Sleeve Study (SM-BOSS) A Prospective Randomized Trial Comparing Laparoscopic Sleeve Gastrectomy and Roux-en-Y Gastric Bypass. *Annals of Surgery* 2013;258(5):690–5.
9. Noel P, Iannelli A, Sejour E, Schneck AS, Gugenheim J. Laparoscopic Sleeve Gastrectomy: How I Do It. *Surg Laparosc Endosc Percutan Tech* 2013;23(1):14–6.
10. Kueper MA, Kramer KM, Kirschniak A, Konigsrainer A, Pointner R, Granderath FA. Laparoscopic Sleeve Gastrectomy: Standardized Technique of a Potential Stand-alone Bariatric Procedure in Morbidly Obese Patients. *World J Surg* 2008;32:1462–65.
11. Campanile FC, Boru CE, Rizzello M, Puziello A, Copaescu C, Cavallaro G, et al. Acute complications after laparoscopic bariatric procedures: update for the general surgeon. *Langenbecks Arch Surg* 2013;398:669–686.
12. Tan JT, Kariyawasam S, Wijeratne T, Chandraratna HS. Diagnosis and management of gastric leaks after laparoscopic sleeve gastrectomy for morbid obesity. *Obes Surg* 2010;20(4):403–9.
13. Dapri G, Cadière GB, Himpens J. Laparoscopic seromyotomy for long stenosis after sleeve gastrectomy with or without duodenal switch. *Obes Surg* 2009;19(4):495–9.
14. Mittermair R, Sucher R, Perathoner A. Results and complications after laparoscopic sleeve gastrectomy. *Surg Today* 2013.
15. Weiner RA, El-Sayes IA, Theodoridou S, Weiner SR, Scheffel O. Early Post-operative Complications: Incidence, Management, and Impact on Length of Hospital Stay. A Retrospective Comparison Between Laparoscopic Gastric Bypass and Sleeve Gastrectomy. *Obes. Surg* 2013.
16. Alharbi SR. Gastrobronchial fistula a rare complication postlaparoscopic sleeve gastrectomy. *Ann Thorac Med* 2013;8(3):179–80.
17. Del Castillo Dejardin, Pereferrer FS, Gonzalez MH, Blasco SB, Vilanova AC. Gastric volvulus after sleeve gastrectomy for morbid obesity. *Surgery* 2013;123(3):431–3.