

# The Happy End of Tragic Story: Recycling of Avulsed Teeth

## Trajik Hikayenin Mutlu Sonu: Avülse Dişlerin Yeniden Kullanımı

Zuhal Kırzioğlu<sup>1</sup>, K. Görkem Ulu Güzel<sup>2</sup>, Hüseyin Karayılmaz<sup>3</sup>, Mehmet Mustafa Özarslan<sup>4</sup>, Mehmet Ali Altay<sup>5</sup>

<sup>1</sup>Süleyman Demirel University Faculty of Dentistry, Department of Pediatric Dentistry, Isparta, Turkey

<sup>2</sup>Adnan Menderes University Faculty of Dentistry, Department of Pediatric Dentistry, Aydın, Turkey

<sup>3</sup>Akdeniz University Faculty of Dentistry, Department of Pediatric Dentistry, Antalya, Turkey

<sup>4</sup>Akdeniz University Faculty of Dentistry, Department of Prosthodontics, Antalya, Turkey

<sup>5</sup>Akdeniz University Faculty of Dentistry, Department of Oral and Maxillofacial Surgery, Antalya, Turkey



### Abstract

Recurrent traumatic injury to immature permanent teeth and environmental tissue may result in extraction of teeth. Due to the growing process of young patients is not completed, until the completion of this process and the fixed prosthesis is fabricated, space maintenance should be prepared for aesthetic and function. This case report presents the use of the clinical crown of failed teeth as the part of partial space maintenance and its beneficial effect on the patient who had multiply dental trauma many times from seven years of age.

### Öz

Genç daimi dişlerin ve çevre dokularının tekrarlayan travmatik yaralanmaları diş kayıpları ile sonuçlanabilir. Hastaların büyüme gelişimlerinin tamamlanmaması nedeniyle, bu süreç tamamlanıp, daimi restorasyonlar yapıncaya kadar, hazırlanacak yer tutucular ile estetik ve fonksiyon sağlanmalıdır. Bu olgu sunumunda, kaybedilen dişlerin yer tutucuda kullanımı ve bunun yedi yaşından bu yana, birden fazla dişsel travma geçiren hastaya sağladığı olumlu etkiler anlatılmaktadır.

### Keywords

Avulsion, space maintenance, multiple dental trauma

### Anahtar Kelimeler

Avülsiyon, yer tutucu, tekrarlayan dişsel yaralanma

Received/Geliş Tarihi : 11.04.2016

Accepted/Kabul Tarihi : 18.04.2016

doi:10.4274/meandros.2618

### Address for Correspondence/Yazışma Adresi:

K. Görkem Ulu Güzel MD,  
Adnan Menderes University Faculty of  
Dentistry, Department of Pediatric Dentistry,  
Aydın, Turkey

E-mail : gorkemulu@yahoo.com

Presented in: Aegean Region Chamber  
of Dentists 6<sup>th</sup> International Scientific  
Congress, 1-3 December 2006.

©Meandros Medical and Dental Journal,  
published by Galenos Publishing.

©Meandros Medical and Dental Journal,  
Galenos Yayınevi tarafından basılmıştır.

### Introduction

Traumatic injury to immature permanent teeth and environmental tissue is a serious issue with possible multiple complications. Prompt and appropriate management is necessary to significantly improve the prognosis for continued vitality (1). Successful treatment options can be used to conserve the tooth after trauma. However, there are requirements where loss of the traumatized tooth is necessary in recurrent traumas. Factors such as patient information, filling therapy and follow-ups, especially when the same teeth are traumatized again, contribute to increased cost (2). In this paper, we present a 24-year-old girl who had multiple dental traumas since 7 years of age and lost her anterior teeth. This case report explains to use of the clinical crown of failed teeth as a part of partial space maintenance and its beneficial psychological effect on the patient and her family until the fixed treatment was done.

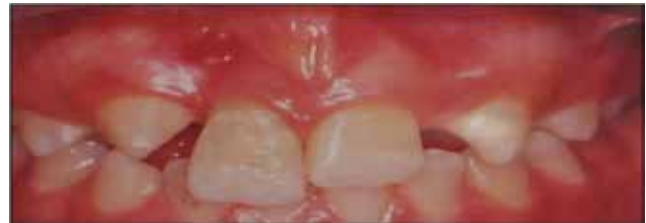## Case Report

A healthy 11-year-old girl with a complaint of pain of the right upper central incisor was referred to the Pediatric Dentistry Department of Süleyman Demirel University, Faculty of Dentistry in February 2003. The extra-oral and intra-oral examination revealed an asymmetry on the upper lip, opaque white area on incisor-cusps of the teeth and excessive mobility and fistula of the right upper central incisor. However, incisal edge of the right tooth was at least 2 mm below the occlusal plane relative to the adjacent teeth (Figure 1). Radiographic examination showed the loss of periodontal bone and internal-external resorption of the right upper central incisor and pulpal obliteration, expansion of lamina dura, and external resorption of the left upper central incisor (Figure 2). In addition, the x-ray showed congenital loss of the two upper lateral incisors. The parents reported that she had experienced a bicycle accident that resulted in avulsion of her right central incisor at the age of seven years. At the time of injury, the child was taken to a local hospital in which the tooth was kept in dry storage condition; reimplanted 60 minutes later and root-canal therapy was performed and sutured. Both clinical and radiographic findings suggested the extraction of the traumatized right incisor and endodontic treatment for the left incisor. The patient and her parents were informed about the alternative treatment after extraction of the right incisor. The parents were unwilling to let their child undergo extraction and they wanted to try to retreatment of the right tooth. After the right root canal were prepared and sterilized, calcium hydroxide + iodoform root canal filling materials (Vitapex, Neo Dental International Inc., Federal Way, WA, USA) were used. Root canal treatment of the left maxillary central incisor was completed (Figure 3). Since the canines had not completed their eruption in the mouth, the composite+wire splint did not involve these teeth to allow their eruption and the splint was applied only to the maxillary central incisors. Thereafter, prolonged maxillary central incisor had reduced in length. Premature contacts were eliminated and avoidance of biting with upper incisors was suggested and oral hygiene instructions were given. Control examination was performed at two weeks interval and due to continuation of mobility of the right tooth, the splint

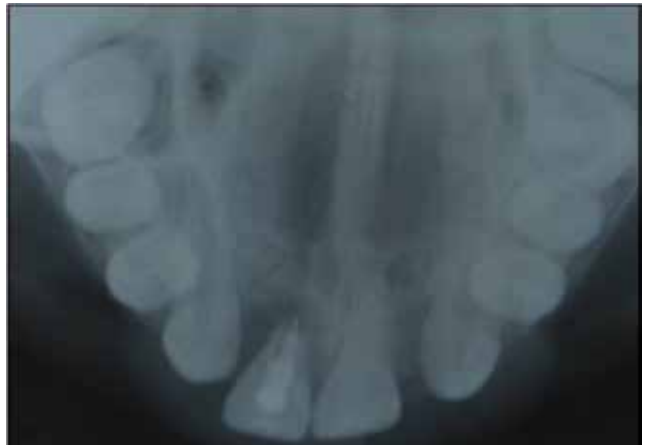was not removed and endodontic treatment of the right incisor was not performed.

### Second Trauma

The patient was re-referred to our clinic with a second trauma owing to fall to the ground in April 2003. In the clinical examination, both incisors showed mobility. The upper central teeth were splinted with composite+wire again, the right root canal was sterilized and the gingiva showed hyperemia and oedema. The patient and her parents were informed about both decoronation and extraction of the right



**Figure 1.** Clinical view of the patient at first visit



**Figure 2.** Radiographic view of the patient at first visit

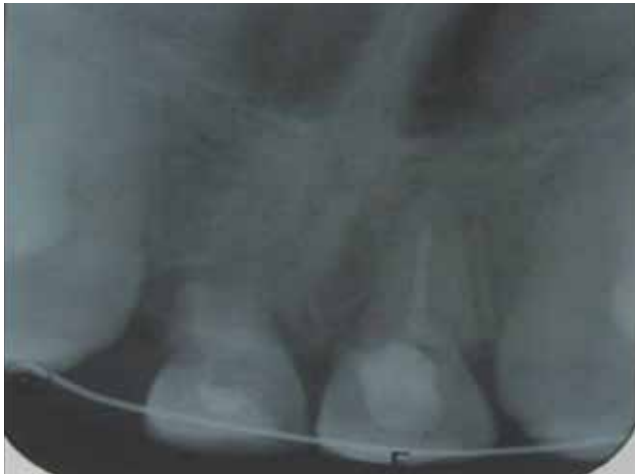

**Figure 3.** Radiographic view of teeth after filling with calcium hydroxide+iodoform root canal material

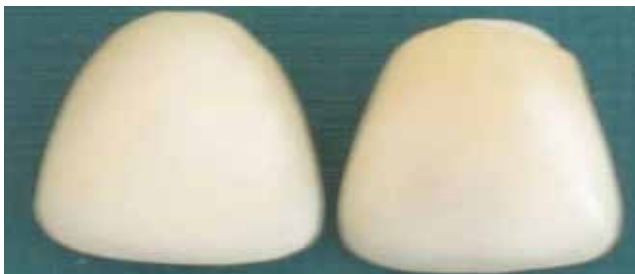incisor. The parents were unwilling to let their child undergo extraction again, thus, it was decided to follow up. The splint which was lengthening between canine-canine relation for fixation didn't remove for two years.

### Third Trauma

On October 2005, the patient presented with third trauma by colliding with her school mate. On the clinical examination, increased sensitivity and resorption of the right central incisor, and coronal and apical root fragment part of 1/3 of the left central teeth were observed. Both of the central teeth showed excessive mobility (Figure 4). Clinical and radiographic findings required extraction of the traumatized incisors, following extraction of the anterior tooth, fabrication of partial space maintenance for the aesthetics and function. The patient and the parents approved the usage of clinical crowns for the space maintenance. Due to color change, the tooth was bleached by sodium perborate. Simultaneously, tooth surfaces were total-etched with 37% phosphoric acid. An adhesive (Dentsply, Konstanz, Germany) was applied to the etched surfaces in accordance with the



**Figure 4.** Radiography of the patient after third trauma

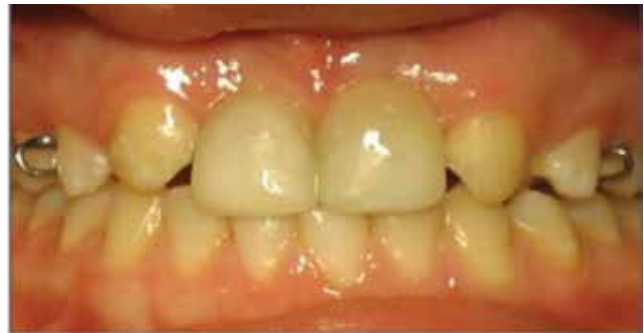

**Figure 5.** View of the natural crowns after composite application

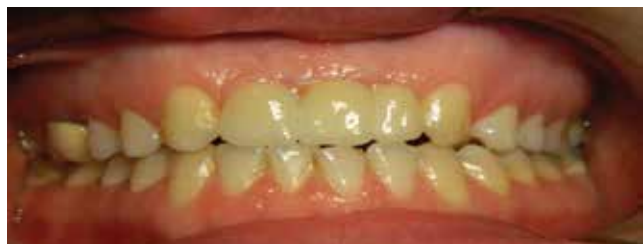manufacturer's recommendations. After that, a thin layer resin composite material (Valux, 3M) was placed into the crown and light cured for 40 seconds each (Figure 5). Oral hygiene instructions were given to both the patient and parents. The use of the appliance apparently caused no lack of comfort and the patient was highly motivated by the esthetic result as well as enhanced ease of biting (Figure 6). Until the fixed prosthesis was fabricated, space maintenance was repeated for two times. When the patient was 21 years old; implant-supported fixed prostheses were placed for the maxillary anterior region (Figure 7, 8).

### Discussion

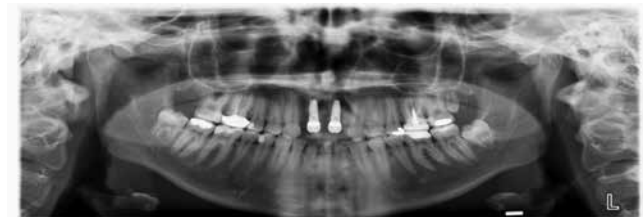
The incidence of more than one trauma in Southern Turkey is 5% (3). In their study, Andreasen et al. (4) have reported that 7.5% of patients had multiple traumas during the healing process, and thus, repeated traumas caused new fractures and affected the



**Figure 6.** Intraoral view of the space maintenance



**Figure 7.** Clinical view of the fixed prosthesis



**Figure 8.** Radiographic view of the fixed prosthesis

healing process and prognosis negatively and finally, the teeth were extracted. Following extraction, space maintenance was performed by using clinical crown of the extracted teeth. Currently, there is no standard treatment for the management of anterior teeth that are lost due to trauma, especially in cases occurring during child development (5). Generally many children and adolescents lose their anterior teeth due to various accidents. Dental implant is usually an ideal treatment for these patient. The use of dental implants is generally not recommended for children in growth period. The dental implant must be delayed to the age 15 in female patients and 17 in male patients. Early implants may act as ankyrotic teeth and fail to move together with the other teeth and structures, which produce an infraocclusion leading to difficulties with prosthetics (6,7). When using natural crown, the patient can better tolerate the effect of tooth failure (8). It provides the maximum shape, color, size, alignment and preserves of natural crown structure. This is of great psychological benefit to the child and adds to her self-esteem. Management of trauma can be as challenging as the treatment of the traumatic injury itself. The space maintenance which replaces the failed teeth crown is an effective treatment option until the permanent treatment is done. It can provide esthetics and function, while being non-invasive, hygienic and long-term provisional treatment without causing any risk of limiting growth. Moreover, at the present day, improvements in restorative materials and various treatment alternatives will also be considered for patients who have difficulties in meeting the treatment disbursement.

#### **Ethics**

**Informed Consent:** Consent form was filled out by all participants.

**Peer-review:** Internal peer-reviewed.

#### **Authorship Contributions**

**Surgical and Medical Practices:** Mehmet Mustafa Özarlan, Mehmet Ali Altay, **Concept:** Zuhar Kırzioğlu, Hüseyin Karayılmaz, K. Görkem Ulu Güzel, **Design:** Hüseyin Karayılmaz, K. Görkem Ulu Güzel, **Data Collection or Processing:** K. Görkem Ulu Güzel, **Analysis or Interpretation:** K. Görkem Ulu Güzel, **Literature Search:** K. Görkem Ulu Güzel, **Writing:** K. Görkem Ulu Güzel.

**Conflict of Interest:** No conflict of interest was declared by the authors.

**Financial Disclosure:** The authors declared that this study has received no financial support.

#### **References**

1. Lin S, Emodi O, El-Naaj I. Splinting of an injured tooth as part of emergency treatment. *Dent Traumatol* 2008; 24: 370-2.
2. Glendor U, Koucheiki B, Halling A. Risk evaluation and type of treatment of multiple dental trauma episodes to permanent teeth. *Endod Dent Traumatol* 2000; 16: 205-10.
3. Kırzioğlu Z, Özay Ertürk SM, Karayılmaz H. Traumatic injuries of the permanent incisors in children in southern Turkey: a retrospective study. *Dent Traumatol* 2005; 21: 20-5.
4. Andreasen JO, Andreasen FM, Mejare I, Cvek M. Healing of 400 intra-alveolar root fractures. 1. Effect of pre-injury and injury factors such as sex, age, stage of root development, fracture type, location of fracture and severity of dislocation. *Dent Traumatol* 2004; 20: 192-202.
5. Ulusoy AT, Cehreli ZC. Provisional use of a natural tooth crown following failure of replantation: a case report. *Dent Traumatol* 2008; 24: 96-9.
6. Ulu KG, Kırzioğlu Z. Büyüme ve gelişimi devam eden bireylerde implant uygulamaları. *Türkiye Klinikleri J Dental Sci* 2010; 16: 67-73.
7. Mishra SK, Chowdhary N, Chowdhary R. Dental implants in growing children. *J Indian Soc Pedod Prev Dent* 2013; 31: 3-9.
8. Ashley M, Holden V. An immediate adhesive bridge using the natural tooth. *Br Dent J* 1998; 184: 18-20.