

Coexistence of Diffuse Idiopathic Skeletal Hyperostosis and Late-Onset Ankylosing Spondylitis in a Sixty-year-old Patient

Diffüz İdiyopatik Skeletal Hiperostozis ve Geç Başlangıçlı Ankilozan Spondilit Birlikteliği Altmış Yaşında Bir Olgu

Zeliha Ünlü¹, Gülgün Yılmaz², Aslıhan Ulusoy¹

¹Celal Bayar University Faculty of Medicine, Department of Physical Therapy and Rehabilitation, Manisa, Turkey

²Celal Bayar University Faculty of Medicine, Department of Radiology, Manisa, Turkey



Abstract

Diffuse idiopathic skeletal hyperostosis (DISH) and ankylosing spondylitis (AS) are two diseases characterized by ossification of the ligaments and tendons in both the axial skeleton and peripheral sites with very different pathologies. Coexistence of DISH and AS is a rare condition and there are relatively few cases in the English-language literature. In this paper, we report a human leukocyte antigen-B27-negative patient who presented with the typical appearance of DISH on the dorsal radiograph and also had sacroileitis, suggesting AS. We discussed prognosis of the late-onset case and the interaction of two diseases in this coexistence.

Öz

Diffüz idiyopatik skeletal hiperostozis (DİSH) ve ankilozan spondilit (AS) aksiyel iskelet ve periferik bölgelerde birbirlerinden farklı patolojiler sonucunda gelişen, ligaman ve tendonlarda ossifikasyon ile karakterize iki ayrı hastalıktır. DİSH ve AS birlikteliği nadir görülen bir durumdur ve İngilizce literatürde de bu duruma dikkat çeken olgu sayısı oldukça azdır. Bu olgu sunumunda sakroileit varlığı yönünden AS, dorsolomber omurga grafi bulguları yönünden ise DİSH için tipik görünüme sahip olan ve İnsan (human) lökosit antijeni-B27 negatif bir olgu sunuldu. Olgunun semptomlarının geç başlangıçlı olması, her iki hastalığın birbirleri ile etkileşimi ve bu durumun prognoza etkisi literatür ışığında tartışıldı.

Keywords

Diffuse idiopathic skeletal hyperostosis, ankylosing spondylitis, sacroileitis

Anahtar Kelimeler

Diffüz idiyopatik skeletal hiperostozis, ankilozan spondilit, sakroileit

Received/Geliş Tarihi : 22.11.2013

Accepted/Kabul Tarihi : 14.10.2014

doi:10.4274/meandros.1733

Address for Correspondence/Yazışma Adresi:

Zeliha Ünlü MD,
Celal Bayar University Faculty of Medicine,
Department of Physical Therapy and
Rehabilitation, Manisa, Turkey
E-mail : zelihaunlu@yahoo.com

©Meandros Medical and Dental Journal, Published by Galenos Publishing.

Introduction

Diffuse idiopathic skeletal hyperostosis (DISH) and ankylosing spondylitis (AS) are two of the most common diseases characterized by ossification of the ligaments and tendons in the axial skeleton and peripheral sites, both. The radiographic appearance of AS and DISH is very similar, but the underlying pathology differs (1). DISH has been referred to be “senile AS”, several years ago (2). Symptoms of AS, such as inflammatory spinal pain and stiffness and decreasing range

of spinal motion begin at younger ages and AS can result in characteristic postural abnormalities after many years. In contrast, DISH affects middle-aged and elderly persons and is often asymptomatic, or associated with mild dorso-lumbar pain and/or some restriction in spinal mobility (3).

DISH and AS can rarely be detected in the same patient. Only 16 patients with coexistence of the two diseases have been reported in the literature, so far (4). In this case report, we reviewed the differential diagnosis of AS and DISH and discussed a 60-year-old female patient who demonstrated clinical and radiological features of both diseases.

Case Report

A 60-year-old woman applied to our department with the complaint of low back pain for 6 years. The pain involved inflammation and intensified at rest and subsided with motion while increasing at night. She also suffered morning stiffness for 10 minutes. In addition, she described heel pain for 4 months which regressed spontaneously. She had diabetes mellitus (DM) for 2.5 years that was regulated with oral antidiabetics.

Range of spinal motions was painful, limited and lumbar lordosis was decreased during the inspection in the physical examination. There was paralumbar painful muscle spasm on palpation. The measurements of the patient with AS were: chest expansion (3 cm), lumbar Schober (3 cm), chin-manubrium sternal distance (3 cm), tragus-wall distance (19 cm), and wall-occiput distance (6 cm).

Laboratory tests, including complete blood count, erythrocyte sedimentation rate using the Westergren method, serologic tests (rheumatoid factor, CRP), routine biochemical tests (urea, creatinine, renal-liver function tests and urine deposits) were within normal limits. Human leukocyte antigen (HLA)-B27 test was negative.

Osteophytes and new bone formation with calcification of anterior ligaments were compatible with DISH on the anteroposterior (AP) and lateral dorsal - lumbosacral spine radiographs (Figure 1, 2). Lateral foot radiographs (Figure 3) showed calcaneal ossifications which are seen as peripheral enthesopathy both in DISH and AS. Sacroiliac radiography on the AP view revealed irregularity related with bilateral sacroiliitis. Joint distance narrowing, irregularity,

erosion and sclerotic changes were bilaterally detected on magnetic resonance imaging (MRI). These changes were reported as bilateral chronic sacroiliitis (Figure 4).

Other possible diseases which can be associated with ossification in the spine and peripheral regions, such as hypervitaminosis A, acromegaly, and calcium pyrophosphate dihydrate deposition disease were excluded on the differential diagnosis. We did not find any clinical or laboratory findings matching with these diseases.

Anti-inflammatory drugs (indometasin cap 75 mg per day) were given for symptomatic therapy of

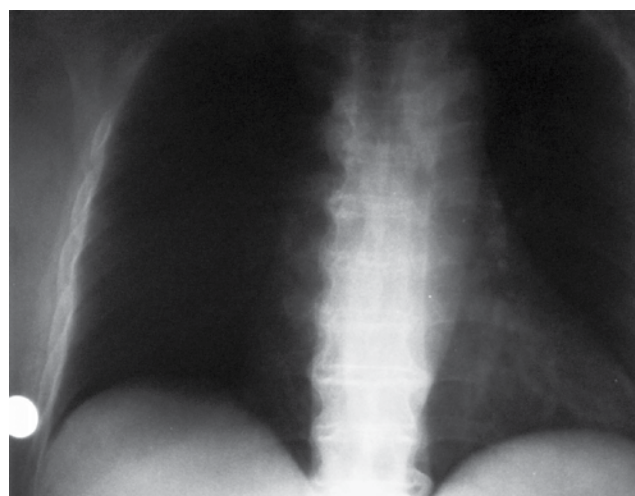


Figure 1. A) Anteroposterior radiograph of the thoracic spine; shows flowing calcification and ossification along the anterolateral aspect of the contiguous vertebral bodies

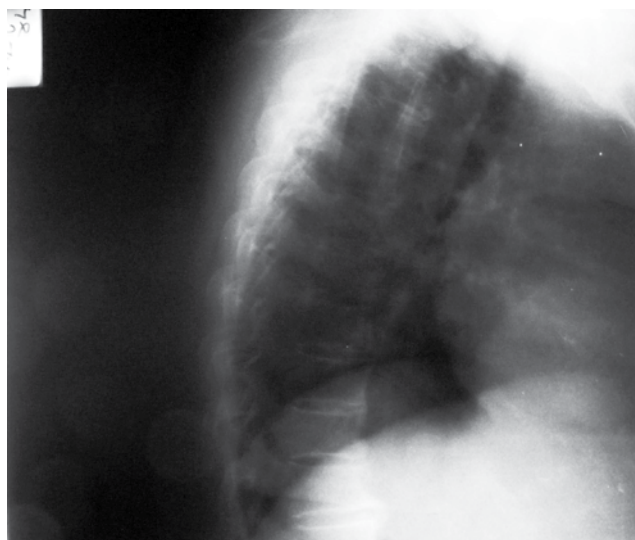


Figure 1. B) Lateral radiograph of the thoracic spine

the complaints. A physiotherapy program, which was composed of hot pack, thermal ultrasound, transcutaneous electrical nerve stimulation and therapeutic exercises (range of motion, stretching, strengthening and stabilization exercises) were applied in thoracic and lumbar regions for 14 days. Patient's complaints reduced and pain (visual analogue scale) score decreased from 80 mm to 10 mm at the end of physiotherapy.

Discussion

Our patient showed characteristic features of both diseases clinically and radiologically. The dorsal radiograph of the case showed typical appearance of DISH. In addition, she had type 2 DM which might be associated with DISH. However, on the other hand, she described inflammatory back and low back pain suggesting AS. We found sacroiliitis and squaring of the lumbar vertebrae on the plane radiographs. Moreno et al. (5) reviewed 106 cases of AS for radiological features of DISH and they found only one case. They reported that the incidence of DISH in AS patients was 0.94%. Clinical coexistence of the symptoms of both diseases was not discussed in this study.

DISH is characterized by calcification and ossification of soft tissues, mainly ligaments and

entheses. In a recent population-based study, 27.3% of men and 12.8% of women older than 50 years of age were found to show evidence of DISH (4).

Several radiologic criteria were described by different authors for the diagnosis of the DISH (6-8). One of the most used classification criteria set by Resnick and Niwayama (8) require flowing calcification and ossification along the anterolateral aspect of at least four contiguous vertebral bodies in first stage. Second stage includes relative preservation of the intervertebral disk height in the involved vertebral

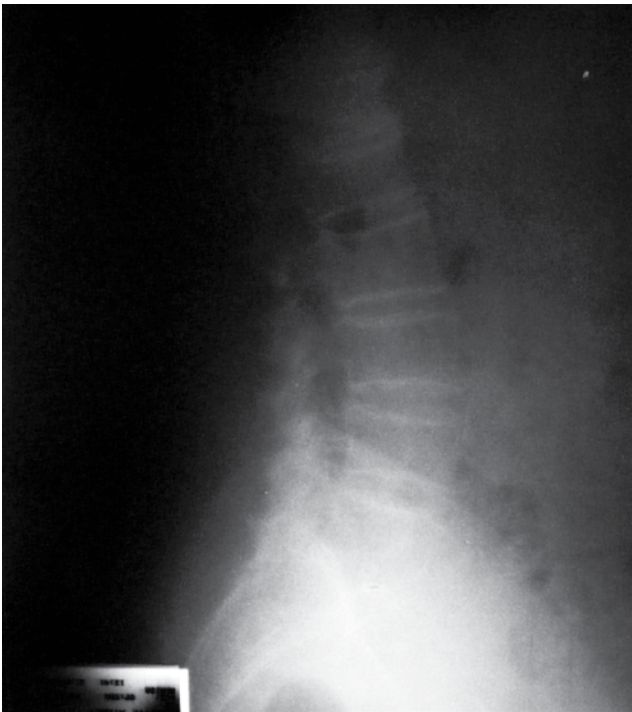


Figure 2. Lateral radiograph of the lumbar spine

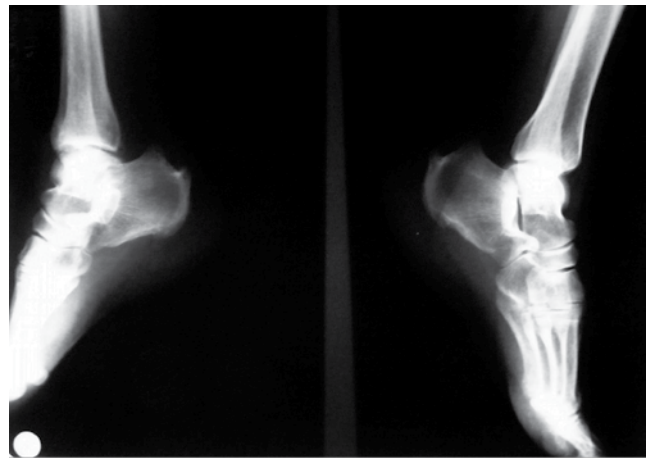


Figure 3. Lateral graphsies of the feet shows calcaneal ossifications, peripheral entesopathy

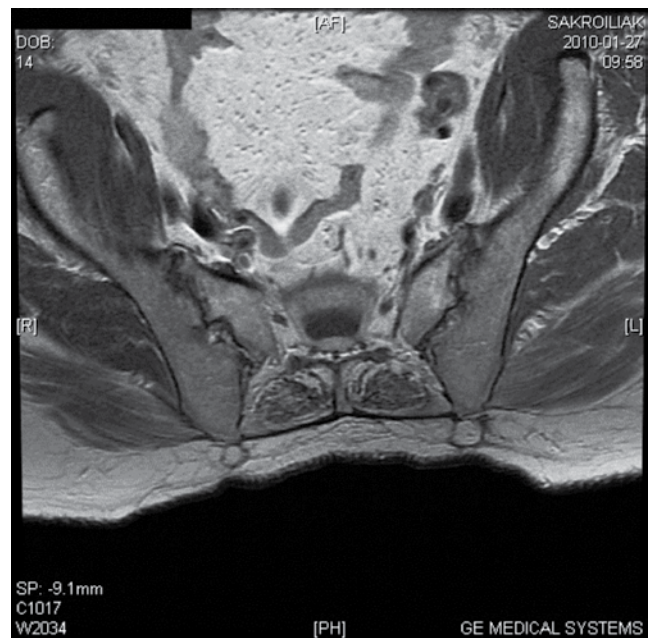


Figure 4. Sacroiliac magnetic resonance imaging shows joint distances narrowing, irregularity, erosion, sclerotic changes and the apparent bilateral chronic sacroileitis

segment and the absence of extensive radiographic changes of degenerative disk disease, including vacuum phenomena and vertebral body marginal sclerosis. Last stage is described as the absence of apophyseal joint ankylosis and the absence of sacroiliac joint erosions, sclerosis, or intraarticular osseous fusion in the synovial portion of these joints. None of these criteria consider the involvement of peripheral entheses. Another set of criteria suggested by Utsinger (9) for the diagnosis of probable DISH lowered the threshold for spinal involvement to three contiguous vertebral bodies and added the presence of peripheral enthesopathy. In our case, there was no doubt about radiological features of DISH, because she had typical radiological changes described by Resnick and Niwayama (8) in the dorsal radiographs. In addition, foot radiographs demonstrated calcaneal ossification showing peripheral enthesopathy.

Sacroiliac capsular bridging has been described in patients with DISH using computed tomography or anteroposterior radiograph of the pelvis. This may give false impression of obliteration of the sacroiliac joint space that occurs in patients with AS (3,10). Our case complained of inflammatory low back pain suggesting sacroiliitis. For this reason, we performed sacroiliac MRI which revealed bilateral chronic sacroileitis. In addition, squaring of the lumbar vertebrae was found. These findings were compatible with AS.

Rillo et al. (11) reported three patients in whom clinical and radiological findings were indicative of DISH and AS coexistence. Two of these cases exhibited HLA-B27 positivity. Jordana et al. (12) reported a 72-year-old male diagnosed with AS, mainly according to clinical and radiological findings, confirmed as HLA-B27-negative. Postmortem examination of the skeleton raised doubts on the initial diagnosis, since spinal findings pointed out also to DISH. Unlike in DISH, there is strong association between HLA-B27 and AS (4). Presence of HLA-B27 may be an important value in the differential diagnosis of the two diseases. However, predictive value of HLA-B27 in AS might be variable in the coexistence of AS and DISH. Our patient was HLA-B27-negative.

Clinicians must be aware of the fact that the features of these two disease processes may overlap and must be able to differentiate the two conditions because the course of the treatment of these diseases is considerably different (2). Our patient showed

specific clinical and radiological findings of both diseases. She dramatically responded to indomethacin treatment supporting inflammatory back pain in AS. We assume that anti-inflammatory therapy should be chosen for patients with prominent AS complaints despite advanced radiological manifestations of DISH. In conclusion, the treatment should be tailored according to the patient's clinical symptoms.

Many questions still remain unanswered in the association with the prediction of the prognosis for patients affected by both AS and DISH. Our patient had complaints for 6 years, but clinically there were no advanced deformities and functional limitations. In addition, the patient reported morning stiffness of short duration, lasting about only 10 minutes. The age of our patient and late-onset AS both seem to play a role in better prognosis in the coexistence of the two diseases. There are no data about the prognosis of these coexisting diseases in the literature. Further investigations are needed.

Ethics

Informed Consent: Consent form was filled out by all participants.

Peer-review: Externally and internally peer-reviewed.

Authorship Contributions

Surgical and Medical Practices: Aslihan Ulusoy, **Concept:** Zeliha Ünlü, **Design:** Zeliha Ünlü, Gülgün Yılmaz, **Data Collection or Processing:** Zeliha Ünlü, Gülgün Yılmaz, Aslihan Ulusoy, **Analysis or Interpretation:** Zeliha Ünlü, Gülgün Yılmaz, Aslihan Ulusoy, **Literature Search:** Aslihan Ulusoy, **Writing:** Zeliha Ünlü, Gülgün Yılmaz, Aslihan Ulusoy.

Conflict of Interest: No conflict of interest was declared by the authors.

Financial Disclosure: The authors declared that this study has received no financial support.

References

1. Baraliakos X, Listing J, Buschmann J, von der Recke A, Braun J. A comparison of new bone formation in patients with ankylosing spondylitis and patients with diffuse idiopathic skeletal hyperostosis: a retrospective cohort study over six years. *Arthritis Rheum* 2012; 64: 1127-33.
2. Aliabadi H, Biglari D, Gonzalez F, Nakaji P. Diffuse idiopathic skeletal hyperostosis versus ankylosing spondylitis: brief case review. *BNI Quarterly* 2006; 22: 10-4.
3. Olivieri I, D'Angelo S, Cutro MS, Padula A, Peruz G, Montaruli M, et al. Diffuse idiopathic skeletal hyperostosis may give the typical

- postural abnormalities of advanced ankylosing spondylitis. *Rheumatology (Oxford)* 2007; 46: 1709-11.
4. Olivieri I, D'Angelo S, Palazzi C, Padula A, Mader R, Khan MA. Diffuse idiopathic skeletal hyperostosis: differentiation from ankylosing spondylitis. *Curr Rheumatol Rep* 2009; 11: 321-8.
 5. Moreno AC, Gonzalez ML, Duffin M, López-Longo FJ, Carreño L, Forrester DM. Simultaneous occurrence of diffuse idiopathic skeletal hyperostosis and ankylosing spondylitis. *Rev Rhum Engl Ed* 1996; 63: 292-5.
 6. Arlet J, Mazières B. Hyperostotic disease. *Rev Med Interne* 1985; 6: 553-64.
 7. Julkunen H, Heinonen OP, Knekt P, Maatela J. The epidemiology of hyperostosis of the spine together with its symptoms and related mortality in a general population. *Scand J Rheumatol* 1975; 4: 23-7.
 8. Resnick D, Niwayama G. Diffuse idiopathic skeletal hyperostosis. In: Resnick D, editor. *bone and joint imaging*. Philadelphia, W. B. Saunders Company; 1992. p. 440-52.
 9. Utsinger PD. Diffuse idiopathic skeletal hyperostosis. *Clin Rheum Dis* 1985; 11: 325-51.
 10. Taljanovic MS, Hunter TB, Wisneski RJ, Seeger JF, Friend CJ, Schwartz SA, et al. Imaging characteristics of diffuse idiopathic skeletal hyperostosis with an emphasis on acute spinal fractures: review. *AJR Am J Roentgenol* 2009; 193(Suppl 3): S10-9.
 11. Rillo OL, Scheines EJ, Moreno C, Barreira JC, Porrini AA, Maldonado Cocco JA. Coexistence of diffuse idiopathic skeletal hyperostosis and ankylosing spondylitis. *Clin Rheumatol* 1989; 8: 499-503.
 12. Jordana X, Galtés I, Couto AR, Gales L, Damas M, Lima M, et al. The coexistence of ankylosing spondylitis and diffuse idiopathic skeletal hyperostosis-a postmortem diagnosis. *Clin Rheumatol* 2009; 28: 353-6.