

Bilateral Superior Semicircular Canal Dehiscence in Patient With Persistent Ear Pain

Persistan Kulak Ağrısı Yakınması Olan Hastada Bilateral Süperior Semisirküler Kanal Dehisansı

Kübra Çoban^{1*}, Feride Kural Rahatlı², Erdiñç Aydın¹

1.Baskent Universty, Faculty of Medicine, Department of Ear, Nose and Throat-Head and Neck Surgery, Ankara, Turkey.

2.Baskent Universty, Faculty of Medicine, Department of Radiology, Ankara, Turkey.

ABSTRACT

Superior semicircular canal dehiscence is a radiological diagnosis which is associated with sound-induced hearing loss, vertigo, nystagmus and oscillopsia. The clinical manifestations have been explained by the absence of a bony cover, generating a 'third window'. In one temporal bone survey the prevalence was reported as 5 cases in 1000 temporal bones, whereas, bilateral involvement was observed in one case. Here we present an otherwise healthy adult patient suffering from bilateral persistent ear pain, in whom bilateral superior semicircular canal dehiscence was the sole pathology. Bilateral canal dehiscence is a very rare entity and ear pain is unlikely in these cases. To our knowledge, there has been no similar cases reported in the literature so far.

Keywords: Superior semicircular canal, dehiscence, otalgia

ÖZ

Süperior semisirküler kanal dehisansı, ses ile tetiklenen işitme kaybı, vertigo, nistagmus ve osilopsi ile seyreden radyolojik bir tanıdır. Klinik bulgular, kanal üzerindeki kemik yapının bulunmaması nedeniyle gelişen 'üçüncü pencere' ile açıklanmaktadır. Bir çalışmada 1000 temporal kemiğin 5'inde bu patoloji bildirilmiştir. Aynı çalışmada bilateral tutulum ise yalnızca bir vakada bildirilmiştir. Bu yazımızda, her iki kulağında uzun yıllardır kulak ağrısı dışında, ek yakınması olmayan, ve bilateral superior semisirküler kanal tutulumu tespit edilen erişkin hasta sunulmaktadır. Bilateral kanal dehisansı nadir görülen bir patolojidir ve bu vakalarda kulak ağrısı beklenmeyen bir semptomdur. Literatür taramamızda benzer bir vakaya rastlanılmamıştır.

Anahtar Kelimeler: Süperior semisirküler kanal, dehisans, otalji

Received Date: 26.10.2018 Accepted Date: 21.02.2019 Published Date: 23.04.2019

*Corresponding Author: Kübra Çoban. Baskent Universty, Faculty of Medicine, Tıp Fakültesi, Department of Ear, Nose and Throat-Head and Neck Surgery, Ankara, Turkey. Phone +905327254196 mail: kubracob81@gmail.com

ORCID:0000-0002-4633-0983



INTRODUCTION

As defined by Minor et al. in 1998, patients with superior semicircular canal dehiscence syndrome (SSCDS), develop sound and/or pressure induced vertigo, hearing loss, disequilibrium due to a 'third window' which causes an acoustic energy loss and increased stimulation of the audiovestibular system [1-4]. Here we present an otherwise healthy adult patient with persistent pain in both ears, and bilateral superior semicircular canal dehiscence was the sole pathology. Bilateral superior semicircular canal dehiscence (SSCD) is very rarely observed in the literature and ear pain is not an expected symptom in these cases. To our knowledge, there has been no similar cases reported in the literature so far.

CASE REPORT

A 53 years old male, attended to our clinic with chronic ear pain in both ears. The pain was not sharp or throbbing, could start at any time of the day, lasted for hours, and exacerbated with loud sounds. He had never experienced any additional audiovestibular symptoms including hearing loss, vertigo, dizziness, tinnitus and ear fullness, so far. His otorhinolaryngology examination including fiberoptic endoscopic view was within normal limits. There were no pathological findings that may cause referred ear pain (Temporomandibular joint, cervical vertebrae, laryngeal pathologies etc.). No evidence of Tullio phenomenon and Hennebert sign was observed. His pure tone hearing levels and tympanometry findings were within normal limits and the acoustic reflexes were present in both ears. High resolution computed tomography scanning (HRCT) was performed using a Siemens Hi-Speed computed tomography (CT) scanner (Siemens, Erlangen, Germany) with the scanning parameters of 130 kV, 94 mA. Patient underwent scanning in the supine position with the head rec-lined and neck flexed. The scan plane was parallel to the orbitomeatal line and skull base. Images were acquired in the sequential mode with a 1 mm slice thickness and zero interslice gap. The images were reformatted from the raw data using a 512x512 matrix. Measurements were performed in a workstation (GE Advantage, Windows version 4.2; GE Medical Systems, Wilmington, MA, USA). For the optimal evaluation of superior

semicircular canal dehiscence, coronal reformatted images were obtained. There was no evidence of other external, middle or inner ear pathologies except bilateral SSCD (Figure 1-2). The size of the dehiscences in the right and left ear were 1,1mm and 0,8 mm respectively (Figure 3).

He had no related audiovestibular symptoms that remarkably affect his quality of life, therefore surgical procedures were not considered. He is still in close follow-up. He was referred to the Neurology clinic for an evaluation with regards to idiopathic intracranial hypertension (IIH).

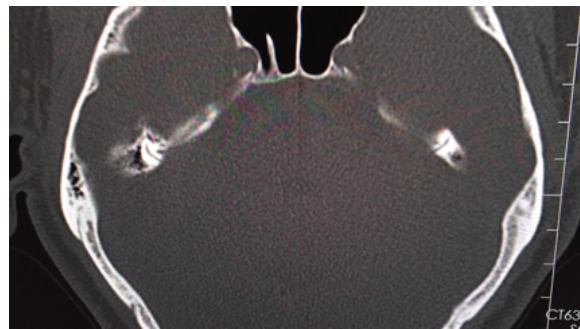


Figure 1: Bilateral SSCD axial image

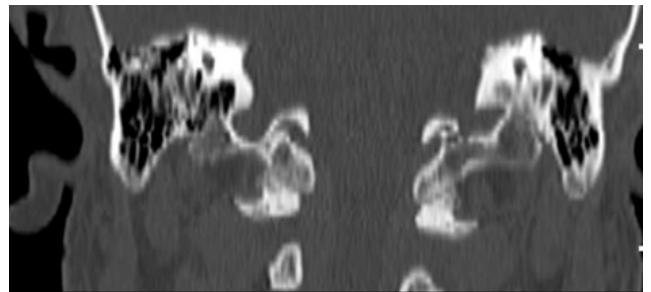


Figure 2: Bilateral SSCD coronal reconstruction view.

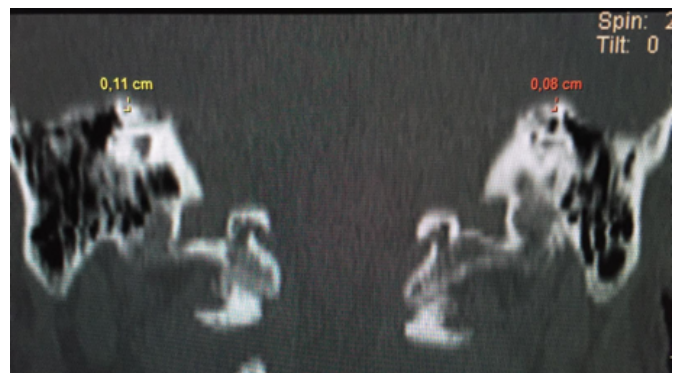

Figure 3: Bilateral SSCD coronal reconstruction view. Sizes of right and left ear dehiscences were shown.

DISCUSSION

The incidence of SSCD was 0.7% in a temporal bone study by Carey et.al [5]. In that study they reported only one case with bilateral involvement. Clinical findings often occur around middle age [6]. According to Minor et al., 92.3% of cases have vestibular symptoms, and 95% of these cases also have vestibular signs. Audiological symptoms, however, were observed in 7.7% of those patients [1]. Interestingly, there were no audivestibular symptoms in this present case.

Superior semicircular canal dehiscence is diagnosed with HRCT [2]. There are differences among histopathological and radiographical studies with respect to the prevalence of SSCD. According to Crovetto et.al, SSCD is more frequently diagnosed radiographically, compared to temporal bone histopathologic evaluations [7].

Ceylan et al. reported 12% prevalence for unilateral, 4% for bilateral SSCD[8]. Belden et al. compared 0.5 mm and 1 mm slice thickness imagings, and, reported similar sensitivity but decreased specificity with 1 mm slice thickness imaging [9]. Poschl and Stenvers planes provide optimal evaluation for the superior semicircular canals [2]. According to Belden et al.[9], approximation of these planes reduces false negative results. The HRCT device in our hospital scans with 1mm thickness, however via coronal reformatted images superior semicircular canals were properly observed.

The clinical diagnosis is commonly achieved by vestibular evoked myogenic potentials (VEMP) test. In symptomatic ears, decrease in the thresholds and increase in amplitudes are commonly noted [6]. The VEMP findings in asymptomatic individuals, are still uncertain and the relationship between the size of the dehiscence, the severity of the symptoms and signs and the VEMP results has not been fully demonstrated in the literature so far [11]. We perform VEMP tests frequently in our clinic, however as our patient had no SSCD related symptoms, he refused to do so.

The main audiological signs in these patients are related to conductive type hearing loss. A 5-10 decibel (dB) air bone gap in 2 or more subsequent frequencies is commonly observed. Acoustic reflexes are commonly preserved [10]. Also there are

few reports with sensorineural hearing loss [3,10]. However in our case, pure tone hearing levels both for air and bone conduction were within normal limits, and the reflexes were preserved. Though still contradictory, there are reports suggesting a positive correlation between the dehiscence size and the air bone gap [10,12]. Why some patients have solely vestibular or audiological complains, some others have both audio-vestibular symptoms, and some patients have no audiovestibular symptoms? is still unanswered [13]. Mikulec et.al observed bilateral SSCD in siblings and suggested a genetic predisposition [13]. However Ceylan et.al, observed 3 bilateral SSCD cases among 5 patients with a history of trauma [8]. They suggested that, trauma may induce vestibular symptoms in patients with congenitally thin bony layer over the semicircular canals [8].

Cho et.al investigated the incidence of SSCD in patients with chronic otitis media and detected a significantly increased incidence of SSCD in the normal ears (bilateral involvement). They suggested that both congenital and developmental etiologies contribute to the development of SSCD [14].

There are studies supporting that, the congenitally thin bony covering of the semicircular canals, may become dehiscent by time due to trauma or increased intracranial pressure [6]. Therefore it should be kept in mind that asymptomatic individuals may become symptomatic ultimately.

The best treatment strategy is to avoid the stimuli inducing the symptoms[6]. Surgical procedures are preferred in severe and persistent cases. In this present case, surgery was not considered.

In this case study we presented SSCD with bilateral involvement, in a patient suffering from bilateral chronic persistent ear pain, that could not be explained by any other pathology. To the best of our knowledge, there is no data in the literature that may associate SSCD with chronic ear pain. However the presence of bilateral ear pain, absence of any other pathology leading to primary and secondary ear pain, suggest that there may be a relationship between SSCD and ear pain. Even in radiological studies, SSCD cases with bilateral involvement are rarely observed and clinical manifestations in those cases are still unclarified in the

literature. Further studies are essential.

In addition, as aforementioned, increased IIH may cause SSCD. As in our present case, it should be kept in mind that chronic persistent ear pain may develop due to IIH, thus the patient was referred to the Neurology department [15]. The increased awareness of otorhinolaryngologist about SSCD will shed light on further studies.

Conclusion: Ear pain is not an expected symptom in SSCD cases. To our knowledge there were no similar cases in the literature. It should be kept in mind that radiological evaluation of temporal bone structures may be necessary in chronic ear pain with unknown etiology.

Conflict of interest: The authors have nothing to disclose and there are no conflicts of interests.

Funding sources: There is no source of funding or financial interest in this study.

15. Reitsma S, Stokroos R, Weber JW, van Tongeren J. Pediatric Idiopathic Intracranial Hypertension Presenting With Sensorineural Hearing Loss. *Ann Otol Rhinol Laryngol.* 2015 Dec;124(12):996-1001. PMID: 26082474

How to cite this article/Bu makaleye atif için:
Çoban K, Rahatlı FK, Aydın E. Bilateral Superior Semicircular Canal Dehiscence in Patient With Persistent Otagia. *Acta Med. Alanya* 2019;3(1):85-88. DOI:10.30565/medalanya.475057

KAYNAKLAR

1. Minor LB. Clinical manifestations of superior semicircular canal dehiscence. *Laryngoscope.* 2005;115(10):1717-27. PMID: 16222184
2. Manzari L, Modugno GC. Bilateral dehiscence of both superior and posterior semicircular canals. *Otol Neurotol.* 2009;30(3):423-5. PMID: 18997636
3. Kanaan AA, Raad RA, Hourani RG, Zaytoun GM. Bilateral superior semicircular canal dehiscence in a child with sensorineural hearing loss and without vestibular symptoms. *Int J Pediatr Otorhinolaryngol.* 2011;75(6):877-9. PMID: 21524803
4. Hamid MA. Bilateral dehiscence of the superior semicircular canals. *Otol Neurotol* 2001;22(4):567-8. PMID: 11449118
5. Carey JP1, Minor LB, Nager GT. Dehiscence or thinning of bone overlying the superior semicircular canal in a temporal bone survey. *Arch Otolaryngol Head Neck Surg.* 2000;126(2):137-47. PMID: 10680863
6. Yew A, Zarinkhou G, Spasic M, Trang A, Gopen Q, Yang I. Characteristics and management of superior semicircular canal dehiscence. *J Neurol Surg B Skull Base.* 2012 Dec;73(6):365-70. PMID: 24294552
7. Crovetto M, Whyte J, Rodriguez OM, Lecumberri I, Martinez C, Eléxpuru J. Anatomic-radiological study of the Superior Semicircular Canal Dehiscence Radiological considerations of Superior and Posterior Semicircular Canals. *Eur J Radiol.* 2010 Nov;76(2):167-72. PMID: 19540691
8. Ceylan N, Bayraktaroglu S, Alper H, Savaş R, Bilgen C, Kirazlı T, Güzelmansur I, Ertürk SM. CT imaging of superior semicircular canal dehiscence: added value of reformatted images. *Acta Otolaryngol.* 2010 Sep;130(9):996-1001. PMID: 20205621
9. Belden CJ, Weg N, Minor LB, Zinreich SJ. CT evaluation of bone dehiscence of the superior semicircular canal as a cause of sound- and/or pressure-induced vertigo. *Radiology.* 2003 Feb;226(2):337-43. PMID: 12563123
10. Teixeira EO, Fonseca MT. Superior Semicircular Canal Dehiscence Syndrome without Vestibular Symptoms. *Int Arch Otorhinolaryngol.* 2014;18(2):210-2. PMID: 25992092
11. Chilvers G, McKay-Davies I. Recent advances in superior semicircular canal dehiscence syndrome. *J Laryngol Otol.* 2015;129(3):217-25. PMID: 25655361
12. Niësten ME, Hamberg LM, Silverman JB, Lou KV, McCall AA, 1Windsor A, Curtin HD, Herrmann BS, Grolman W, Nakajima HH, Lee DJ. Superior canal dehiscence length and location influences clinical presentation and audiometric and cervical vestibular-evoked myogenic potential testing. *Audiol Neurootol.* 2014;19(2):97-105. PMID: 24434937
13. Mikulec AA, McKenna MJ, Ramsey MJ, Rosowski JJ, Herrmann BS, Rauch SD, Curtin HD, Merchant SN. Superior semicircular canal dehiscence presenting as conductive hearing loss without vertigo. *Otol Neurotol.* 2004 Mar;25(2):121-9. PMID: 15021770
14. Cho YW, Shim BS, Kim JW, Kim TS, Ahn JH, Chung JW, Lee KS, Yoon TH, Park HJ. Prevalence of radiologic superior canal dehiscence in normal ears and ears with chronic otitis media. *Laryngoscope.* 2014 Mar;124(3):746-50. PMID: 23794324