

Case Report

IS DERMAL MELASMA A PHOTOTOXIC REACTION? A CASE REPORT

Kayaş Y¹, Yaman B², Ertam İ³, Akalın T², Ünal İ³

¹ Malatya Education and Research Hospital Dermatology Clinic, Malatya, Turkey.

² Ege University, Faculty of Medicine, Department of Pathology, İzmir, Turkey.

³ Kartal Ege University, Faculty of Medicine, Department of Dermatology, İzmir, Turkey.

Corresponding author

Kayaş Y

Malatya Education and Research Hospital Dermatology Clinic, Malatya, Turkey.

e-mail: dryavuzkayas@hotmail.com

ABSTRACT

Pigmentation related to drugs consist %10-20 of cases with acquired hyperpigmentation. Melasma is a common acquired disorder characterized by symmetric, hyperpigmented patches with an irregular outline, occurring most commonly on the face. Melasma is rarely seen in males. High ultraviolet exposure and family history are the most common in etiology and some drugs may result melasma to be seen in males which is very rare. Phototoxic drug reaction should also be considered in differential diagnosis in male patients with hyperpigmentation on the sun exposed areas.

Key words: Melasma , Photosensitivity, Drug reactions, Fluoxetine

ÖZET

İlaçlara bağlı pigmentasyon, edinsel hiperpigmentasyonlu olguların yaklaşık %10-20'sini oluşturur. Melasma çoğunlukla yüzde oluşan, düzensiz kenarlı, simetrik, hiperpigmente yamalarla karakterize, sık görülen edinsel bir hastalıktır. Melasma nadiren erkeklerde görülür. Yüksek UV maruziyeti ve aile hikayesi etolojide siktir ve bazı ilaçlar nadiren de olsa erkeklerde de görülen melasmaya neden olabilir. Fototoksik ilaç reaksiyonu, güneş gören bölgelerde hiperpigmentasyonlu erkek hastalarda ayırıcı tanıda düşünülmelidir.

Anahtar kelimeler: Melasma, fotosensitivite, ilaç reaksiyonları, fluoxetine

INTRODUCTION

Melasma is characterized by irregular hyperpigmented macules located typically on the sun exposed areas like frontal, malar zones, upper lip, cheeks and neck.¹ Melasma is seen commonly in females. Pregnancy, oral contraceptive usage, sunlight, genetic factors and thyroid

otoimmunity may trigger melasma.² Melasma is rarely seen in males (3). High ultraviolet exposure and family history are the most common in etiology and some drugs may result melasma to be seen in males which is very rare.⁴

We present this male case of melasma to point out the importance of drugs in etiology and show that drug reaction

caused by selective serotonin reuptake inhibitors (SSRI) may rarely be seen.

CASE REPORT

A 38 years old male patient referred to our clinic with grey-blue discoloration on the right preauricular region which was started two and a half years ago and spread to whole facial area within one year.

Dermatological examination showed diffuse grey-blue discoloration in his forehead, both malar and mental regions (Figure 1). Wood lamp examination confirmed dermal melasma.

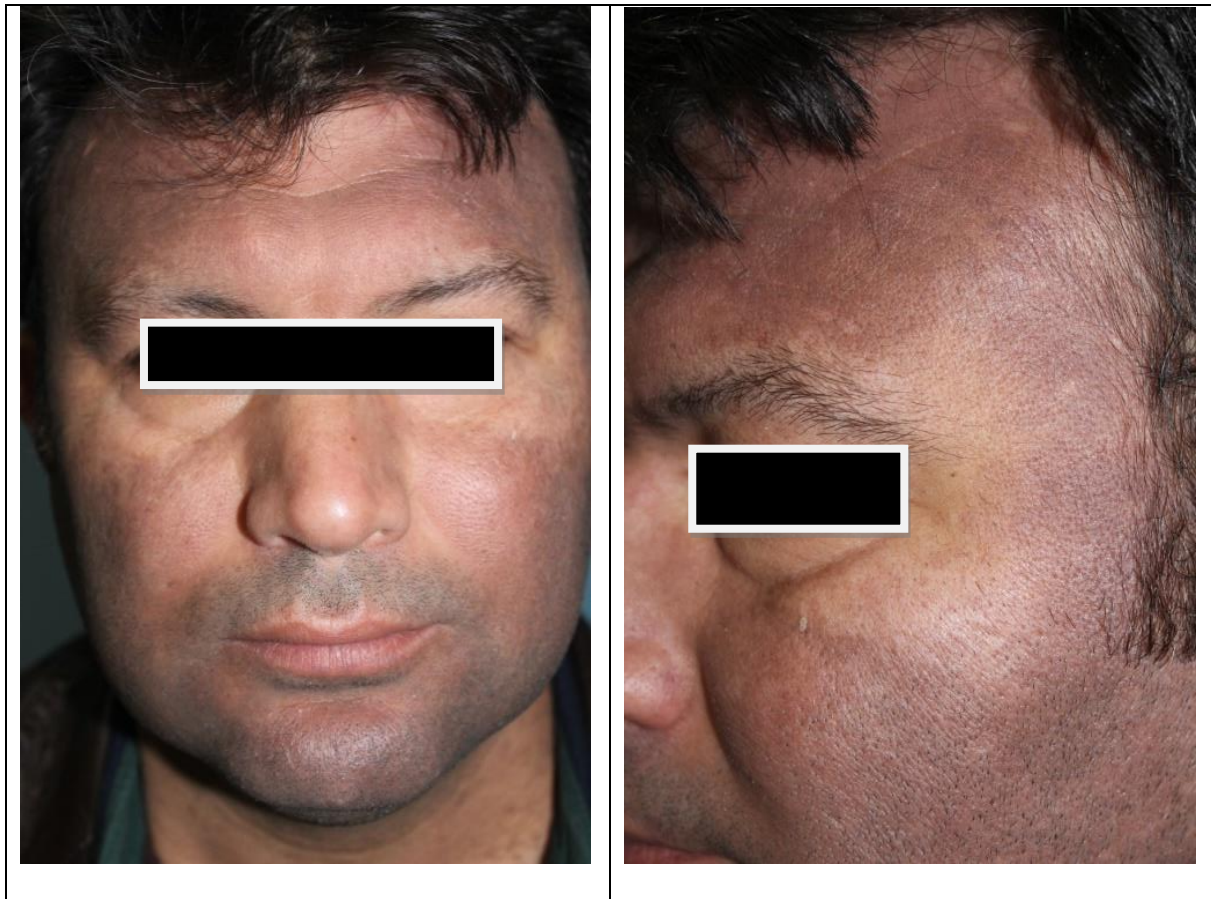


Figure 1. Grey-blue pigmentation on frontal, malar areas of the patient.

Patient's history revealed that he had been using fluoxetine which he was still using until 5 months ago for his depressive complaints, he had used for 2 years and he

has sun exposure only in his social and occupational life.

No abnormalities were detected in complete blood count, routine urine,

biochemistry and thyroid function tests. Antinuclear antibody (ANA) was negative. Since there was a history of drug usage, skin biopsy was planned in order to confirm the diagnosis. Skin biopsy showed epidermal atrophy, single cell necrosis, basal cell degeneration and lymphocyte

exocytosis, mononuclear cell infiltration containing perivascular rich melanophages in superficial dermis which is interpreted as phototoxic dermatitis (Figure 2). After stopping fluoxetine discoloration areas has started to decrease.

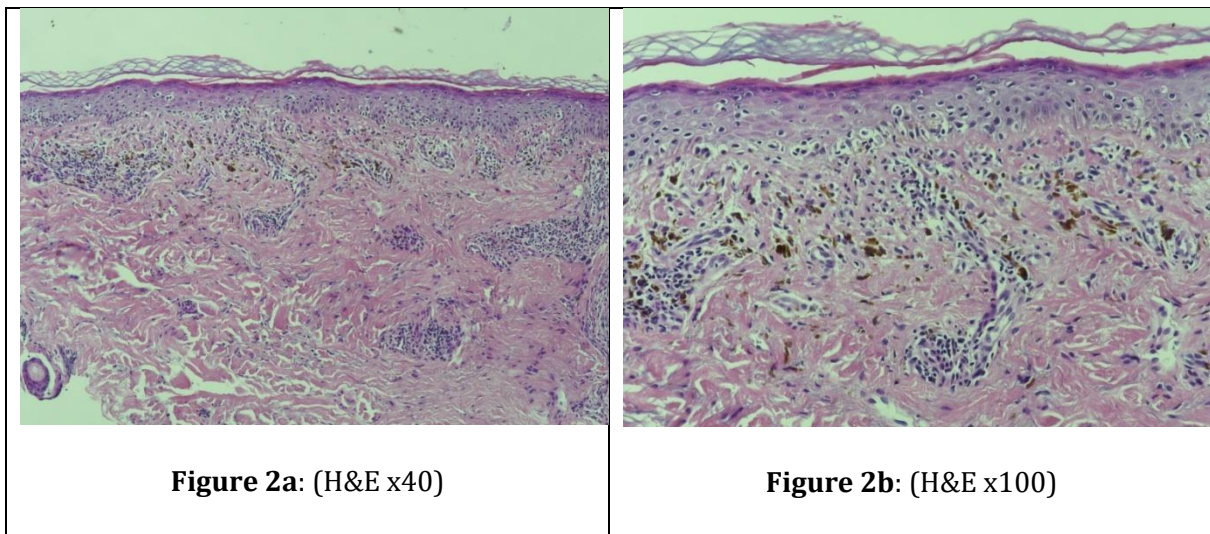


Figure 2. Epidermal atrophy, single cell necrosis, basal cell degeneration and lymphocyte exocytosis, mononuclear cell infiltration containing perivascular melanophages in superficial dermis.

DISCUSSION

Photosensitive drug eruptions consists %8 of cutaneous adverse reactions related to drugs.⁵ Pigmentation related to drugs consist %10-20 of cases with acquired hyperpigmentation.⁶ Photosensitivity caused by drugs generally occur with phototoxicity and photoallergic mechanisms.⁷

Phototoxic skin reactions are usually seen as severe sun burn like, erythema and edema with vesicles and blisters. Skin

reactions caused by photoallergic mechanisms are usually seen as polymorphic papulovesicles, itchy eczematous and lichenified lesions. In both types, lesions can be seen as postinflammatory hyperpigmentation.^{7,8}

Skin reactions related to psychotropic drugs are usually associated with antiepileptic drugs.⁹ However, in written literature severe skin reactions like erythema multiforme, Stevens-Johnson

syndrome (SJS); Lyell's Syndrome (Toxic Epidermal Necrolysis–TEN); Acute generalised exanthematous pustulosis (AGEP) caused by antidepressant including SSRIs, erythroderma, tanning, facial erythema, telangiectasia and photo distributed hyperpigmentation caused by only SSRI drugs have been reported⁵

In one case SJS/TEN and in another case TEN was reported caused by fluoxetine. In another case hypersensitivity syndrome was reported.⁹ Besides this severe skin reactions in literature photosensitive drug reaction caused by fluoxetine and alprazolame, erythema and edema caused by only fluoxetine was reported.^{10,11}

In our case, diffuse grey-black hyperpigmentation caused by fluoxetine

usage was seen and diagnosed with melasma clinically. Wood lamp examination confirmed melasma diagnosis. However, skin punch biopsy intended for differential diagnosis showed findings related to phototoxic dermatitis on this case with drug usage history. Skin findings were uncommon pigmentations rather than erythema, edema, vesicles and blisters. Drug usage history should be evaluated for diagnosis in patients with photodistributed skin findings like melasma. ANA should be evaluated in differential diagnosis for Lupus, photopatch test should be done for etiological agent and mechanisms. In certain situations urine, blood and feces tests should be evaluated for porfirias.¹²

CONCLUSION

Widely prescribed psychiatric drugs like SSRIs should be kept in mind as photosensitive drugs and patients should

be evaluated for drug reactions and sun protection should be recommended.

REFERENCES

1. Chang MW. Disorders of Hyperpigmentation in Dermatology, Third edition, vol. one, Jean JBologna L, Jorizzo JL (eds) Ed. Elsevier Saunders, 2012, pp. 1049–1074.
2. S. K. Çakmak SK, Özcan N, Kılıç A, et al. Etiopathogenetic factors, thyroid functions and thyroid autoimmunity in melasma patients. *Adv Dermatology Allergol* 2015; 5:327–330.
3. Jang YH, Sim JH, Kang HY, et al. The histopathological characteristics of male melasma: Comparison with female melasma and lentigo. *J Am Acad Dermatol* 2012; 66: 642–649.
4. Rashmi S, Garg S. Melasma in Men. in *Melasma : A Monograph*, First., R. Sarkar, Ed. Jaypee Brothers Medical Publishers, 2015, pp. 80–85.
5. Drucker A, Rosen C. Drug-induced photosensitivity : culprit durgs, management and preventin. *Drug Saf* 2011; 34: 821–837.

6. Dereure O. Drug-induced skin pigmentation. Epidemiology, diagnosis and treatment. *Am J Clin Dermatol* 2001; 2: 253–262.
7. Kutlubay Z, Sevim A, Engin B et al. Photodermatoses, including phototoxic and photoallergic reactions (internal and external). *Clin Dermatol* 2014; 32:73–79.
8. Lehmann P. Photodermatoses. in Braun-Falco's *Dermatology, Third.*, Burgdorf W. Plewig G. Wolff H.H. Landthaler M., Ed. Springer New York, 2008;573–597.
9. Herstowska M, Komorowska O, Cubała WJ, et al. Severe skin complications in patients treated with antidepressants: a literature review. *Postępy dermatologii i Alergol* 2014.; 31:92–97.
10. Pazzagli L, Banfi R, Borselli G, et al. Photosensitivity reaction to fluoxetine and alprazolam. *Pharm World Sci* 1998; 20: 136.
11. Gaufberg E, Ellison JM. Photosensitivity reaction to fluoxetine. *J Clin Psychiatry* 1995; 56: 486.
12. I. Drug-induced, I. The, and M. Phototoxic, "Evidence-Based Guideline for the Classification and Management of Drug-Induced Phototoxicity," *Eur. Dermatology Forum Guidel. Photodermatoses*, pp. 1–6.