

Approach to iatrogenic colon perforations due to colonoscopy: A retrospective cohort study

Kolonoskopiye bağlı gelişen iyatrojenik kolon perforasyonlarına yaklaşım: Retrospektif kohort çalışma

Yasin Kara¹

¹University of Health Sciences, Kanuni Sultan Süleyman Education and Research Hospital, Department of General Surgery, Istanbul, Turkey

ORCID ID of the author(s)
YK: 0000-0002-9723-1774

Corresponding author / Sorumlu yazar:
Yasin Kara

Address / Adres: Atakent Mahallesi, Halkalı
Altnşehir İstanbul Cd. No:1, 34303
Küçükçekmece, İstanbul, Türkiye
e-Mail: yasinkara32@windowslive.com

Ethics Committee Approval: Ethics committee approval was not received because the study was performed retrospectively.

Etik Kurul Onayı: Çalışmamız retrospektif olması nedeniyle etik kurul onayı alınmamıştır.

Conflict of Interest: No conflict of interest was declared by the authors.

Çıkar Çatışması: Yazarlar çıkar çatışması bildirmemişlerdir.

Financial Disclosure: The authors declared that this study has received no financial support.

Finansal Destek: Yazarlar bu çalışma için finansal destek almadıklarını beyan etmişlerdir.

Published: 5/24/2019

Yayın Tarihi: 24.05.2019

Copyright © 2019 The Author(s)

Published by JOSAM

This is an open access article distributed under the terms of the Creative Commons Attribution-NonCommercial-NoDerivatives License 4.0 (CC BY-NC-ND 4.0) where it is permissible to download, share, remix, transform, and build upon the work provided it is properly cited. The work cannot be used commercially without permission from the journal.



Abstract

Aim: Iatrogenic colonic perforation (ICP) is a serious complication that can increase mortality and morbidity in patients undergoing therapeutic or diagnostic colonoscopy. The aims of this study are to (1) evaluate the underlying mechanisms of ICPs; (2) discuss the ideal treatment approach and period between onset and treatment; (3) review the current literature regarding the management of ICPs and (4) share our experiences as a single tertiary center.

Methods: Patients who underwent colonoscopy between January 2012 and March 2019 at Kanuni Sultan Süleyman Training and Research Hospital's Endoscopy Unit were reviewed retrospectively. Interventions during which ICPs occurred were documented and analyzed.

Results: Between January 2012 and March 2019, 9857 patients underwent colonoscopy and 1320 patients underwent rectosigmoidoscopy at our center. Ten of these procedures were associated with perforation. The perforation rates were 0.06% and 0.23% in diagnostic and therapeutic colonoscopies respectively. The most frequent localizations of perforation were (a) Rectosigmoid junction (30%) (b) Sigmoid colon (30%) (c) Descending colon (20%) and (d) Transvers colon (10%) (e) Cecum (10%). Managements included surgical treatment in eight patients two of whom were operated with late laparotomy, endoscopic clipping of perforation and conservative management in one patient, and conservative treatment in one patient. There was no mortality and eight patients discharged uneventfully but one of remaining two patients had acute hepatitis, one had enterocutaneous fistula. **Conclusion:** Iatrogenic colonic perforations are rare but most serious complications of colonoscopy procedures. Especially, special attention should be given to older and comorbid patients receiving therapeutic procedures during colonoscopy. High risk patients and their families must be informed about this complication. Difficult and tough colonoscopies should be monitored closely at least 24 hours as early diagnosis is vital for treatment. Comorbidities, age, general condition of patient, the size and location of the perforation, and the time interval between onset and diagnosis should be evaluated, and the treatment procedure should be planned. Conservative management, endoscopic clipping, laparoscopic or open operations from primary repair to Hartmann's procedure can be used, decision should be made on a case by case basis.

Keywords: Colonoscopy, Iatrogenic bowel perforation, Treatment, Emergency surgery, Laparoscopy

Öz

Amaç: İyatrojenik kolon perforasyonu (İKP), terapötik veya tanısal kolonoskopi uygulanan hastalarda mortalite ve morbiditeyi artırabilen ciddi bir komplikasyondur. Bu çalışmanın amacı (1) İKP'lerin oluş mekanizmalarını irdelemek (2) İdeal tedavi yaklaşımlarını ve zamanını tartışmak (3) Tedaviye yönelik güncel literatürü gözden geçirmek ve (4) üçüncü basamak tek merkez olarak tecrübelerimizi paylaşmaktır.

Yöntemler: Ocak 2012 ve Mart 2019 arasında Kanuni Sultan Süleyman Eğitim ve Araştırma Hastanesi Endoskopi Ünitesinde, tanısal veya tedavi amaçlı yapılan tüm kolonoskopiler retrospektif olarak incelendi. İyatrojenik kolon perforasyonu gelişen işlemler kayıt altına alındı ve analiz edildi.

Bulgular: 2012 Ocak ve 2019 Mart arasında, merkezimizde 9857 hastaya kolonoskopi ve 1320 hastaya rektosigmoidoskopi işlemi yapılmıştır. Bu işlemlerden 10 tanesinde iyatrojenik kolon perforasyonu gelişmiştir. Perforasyon oranları tanısal işlemlerde %0.06, tedavisel işlemlerde %0.23 idi. Perforasyon alanları, sıklığına göre (a) rektosigmoid bileşke (%30), (b) sigmoid kolon (%30), (c) inen kolon (%20), (d) transvers kolon (%10), (e) çekum (%10). Sekiz hasta ikisi geç laparotomi olmak üzere ameliyat edildi, bir hastada perforasyona endokliplleme ve konservatif tedavi yine bir hastaya sadece konservatif tedavi uygulandı. Mortalite izlenmemiş olup sekiz hasta sorunsuz taburcu edilirken, kalan iki hastanın birinde akut hepatit tablosu ve diğerinde enterokütan fistül gelişmiştir.

Sonuç: İyatrojenik kolon perforasyonları kolonoskopi işleminin nadir ancak en ciddi komplikasyonudur. Özellikle girişimsel işlem uygulanan yandaş hastalığı olan yaşlı hastalara dikkat edilmelidir. Yüksek riskli hastalar ve aileleri perforasyon konusunda bilgilendirilmelidir. Zor geçen, şüpheli kolonoskopilerde, hastalar en az 24 saat müşahade altında takip edilmelidir. Perforasyon gelişen hastalarda yandaş hastalık, hastanın genel durumu, perforasyonun yeri ve büyüklüğü ve perforasyondan ameliyata kadar olan süre hesaba katılarak tedavi prosedürü belirlenmelidir. Her hasta vaka bazında değerlendirilerek konservatif takipten endoskopik kliplleme, laparoskopik veya açık olarak primer rafiden Hartman prosedürüne kadar bir dizi tedavi yöntemi seçilebilir.

Anahtar kelimeler: Kolonoskopi, İyatrojenik kolon perforasyonu, Tedavi, Acil cerrahi, Laparoskopik

Introduction

Since colonoscopy was introduced in 1960s at the Department of Surgery of Medical Center in New York City, it is accepted as the gold standard method in diagnosis, prevention, treatment, and follow-up of colorectal cancers and diseases [1].

Currently, because of the extended therapeutic and diagnostic indications of colonoscopy, number of iatrogenic colonic perforations (ICP) is increased. As a major cause, it is estimated that the frequency of ICP is 0.019%-0.8% and 0.10%-3% for diagnostic and therapeutic colonoscopy respectively [2].

Perforation located at the colon can rapidly cause peritonitis and even sepsis depending upon bowel cleaning, the size and localization of perforation, age and comorbidities of patients. These complications imply high morbidity and mortality [3].

In the management of ICP, unfortunately there is not a gold standard method. The traditional management of ICP is surgical repair by either laparotomy or laparoscopy. Although most cases require urgent surgery, in some cases, ICP can be managed by endoscopic clipping and conservative management (CM). We aimed to evaluate the incidence of ICP, risk factors, patient management strategies, and the clinical consequences in our single tertiary center in the light of literature.

Materials and methods

Between January 2012 and March 2019, a total of 11177 lower gastrointestinal system endoscopies were performed at our single tertiary center. Patients with ICP were investigated retrospectively. All procedures were conducted under sedoanalgesia. The procedures were performed by 16 endoscopists, including 13 general surgeons and 3 gastroenterology specialists. The experience of the endoscopists varied between 3 and 17 years.

The data of the cases was obtained retrospectively from the patient files in hospital archive and from electronic hospital records. Local Ethics committee approval was not required because of the retrospective nature of the study. Written informed consent was obtained from all patients included in this study. The study was prepared in accordance with the principles of the Helsinki Declaration.

We evaluated and analyzed the demographics, comorbidities, American Society of Anesthesiologists (ASA) scoring of patients, the type of procedure (therapeutic or diagnostic), indications for colonoscopy, associated colonic pathologies, location and detection time of perforation, treatment strategies (operative or nonoperative), duration of hospitalization, and postoperative complications.

Patients who underwent surgery within the twelve hours after perforation are named as early laparotomy; those who underwent surgery after twelve hours were called as late laparotomy. Patients in whom perforation detected during colonoscopic examination were operated in the early period of emergency surgery team. Patients who were suspected to have colon perforation after colonoscopy were hospitalized in their clinics, the other service or outpatient patients were followed up by the emergency surgery team. Patients diagnosed with

perforation following radiological evaluation and / or clinical follow-up were operated.

The perforations were detected either during colonoscopy by observing a visible defect in the colonic wall (mesenteric or antimesenteric side) or after the procedure by detecting free intra-abdominal air upon radiological examination. Appropriate stable patients were treated either conservatively or endoclippping plus conservative management. Patients who complained of abdominal pain or distention following colonoscopy were initially evaluated by abdominal x-ray, hemogram and C-reactive protein level. All patients with generalized peritonitis and free intra-abdominal air underwent surgical intervention either open or laparoscopically.

Statistical analysis

Statistical Package for the Social Sciences (SPSS) (IBM Corp.; Armonk, NY, USA) 22.0 software package was used for statistical analysis. Data was presented with numbers and percentages.

Results

Between January 2012 and February 2019, a total of 11177 colorectal system endoscopies were performed in our endoscopy unit, 9857 of them were colonoscopy and 1320 of them were sigmoidoscopy. During these procedures, polypectomy was performed in 516 patients and biopsy was performed in 1171 patients. Iatrogenic colon perforation developed in 10 patients eight of which required surgical intervention. Seven (70%) of these patients were female and three (30%) were male and their mean age was 59 (40-73 years). While nine cases occurred during colonoscopy one case had ICP during rectosigmoidoscopy. ICP occurred during therapeutic procedure in 4 patients and due to diagnostic colonoscopy in 6 patients (Table 1).

Eight patients with ICP were diagnosed during endoscopic examination; others were diagnosed with acute abdominal symptoms during clinical follow-up, and / or were diagnosed with intra-abdominal free air in radiological examination. Patients who had ICP detected during endoscopy were operated on an average of 2.45 hours (1-5 hours), and patients diagnosed in late period after clinical endoscopy were operated on average of 60 hours (30-90 hours). The mean duration of the operation after colonoscopy was 13.95 hours (1-90 hours). Five patients underwent early, two patients underwent late laparotomy and one had early laparoscopic primary repair (Table 1).

In two of six patients operated in early period, primary suturing either laparoscopically or open was the treatment of choice. In four cases, open segmental colon resection plus end to end anastomosis was the operative procedure. One case that occurred after polypectomy was treated conservatively as bowel resting, intravenous fluid replacement and antibiotherapy. Another perforation detected during polypectomy was treated with endoclippping and conservative management. Two patients with ICP were detected in late period. In one of them, perforation was in cecum and due to argon plasma coagulation of cecal angiodysplasia, treatment of choice was right hemicolectomy and ileotransversostomy. Other late detected perforation was at 90th hour of diagnostic colonoscopy, she was in sepsis and emergency

laparotomy and Hartmann’s procedure with abdominal vacuum-assisted closure (VAC) exchange procedure applied (Table 1).

The perforation area was the rectosigmoid in three (30%) patients and the sigmoid in three (30%), descending colon in two (20%), transvers colon in one (10%) and cecum in one (10%) patient. Considering all applications, the rate of ICP was found to be 0.09%. When evaluated separately, perforation rate was 0.06% in diagnostic colonoscopy and 0.23% in therapeutic ones. The reasons for perforation in interventional colonoscopy were snare polypectomy in three patients and argon plasma coagulation of bleeding angiodysplasia in one patient.

The diverticulosis was found in two patients who developed colon perforation due to diagnostic endoscopy, and the long-folded sigmoid colon anatomy and previous surgery were the predisposing factors in remaining 4 patients.

Patient who underwent Hartmann’s procedure and abdominal VAC exchange procedure developed acute hepatitis during follow-ups in intensive care unit and one with right hemicolectomy ileotransversostomy developed enterocutaneous fistula.

Table 1: Demographics and properties of patients with ICP, localization of perforations, time of diagnosis, and treatment modalities of iatrogenic colon perforations

Age	Gender	Indication of colonoscopy	Perforation site	BMI	ASA score	Comorbidity	Procedure modality	Diagnosis	Operation time	Treatment
40	F	Chronic diarrhea	Sigmoid	27	2	No	Diagnostic	During endoscopy	2nd hour	Laparoscopic primary suturing
56	F	FOBT (+)	Rectosigmoid junction	26	3	HT, COPD	Therapeutic	During endoscopy	1st hour	Resection and anastomosis
67	F	Constipation	Rectosigmoid junction	26	3	CHF, HT	Diagnostic	In emergency room	4th day	Hartmann’s procedure + Abdominal VAC
73	F	Lower gastrointestinal bleeding	Cecum	24	4	CAD, HT, DM	Therapeutic	In emergency room	1st day	Open right hemicolectomy
73	M	Iron deficiency Anemia	Rectosigmoid junction	20	3	HT, DM, CHF	Diagnostic	During endoscopy	2nd hour	Open primary suturing
63	F	FOBT(+)	Sigmoid colon	27	3	HT	Therapeutic	During endoscopy	Conservative	Conservative management
66	M	Iron deficiency anemia	Transvers colon	25	3	DM, MG	Diagnostic	During endoscopy	2nd hour	Segmental resection and anastomosis
53	F	FOBT(+)	Descending colon	22	2	No	Diagnostic	During endoscopy	3rd hour	Segmental resection and anastomosis
56	F	Constipation	Sigmoid colon	28	3	HT, DM	Therapeutic	During endoscopy	Conservative	Hemoclipping
46	M	Constipation	Descending colon	24	2	No	Diagnostic	During endoscopy	4th hour	Resection and anastomosis

BMI: Body Mass Index; CHD: Congestive Heart Failure; HT: Hypertension; CAD: Coronary Artery Disease; RA: Rheumatoid Arthritis; MG: Myasthenia Gravis; FOBT: Fecal Occult Blood Test; COPD: Chronic Obstructive Pulmonary Disease. ASA: American Society of Anesthesiologists; VAC: Vacuum - assisted closure

Discussion

Colonoscopy is being used for diagnostic, therapeutic and follow-up purposes of various colorectal diseases and lesions. Iatrogenic colonic perforation is the second and most serious complication that encountered in colonoscopy procedures. Therapeutic interventions (Endoscopic mucosal resection, endoscopic submucosal dissection, polypectomy or biopsies, etc.) during colonoscopy increase the risk of ICP [3].

In a recent study of 56,882 colonoscopies, full-thickness large bowel perforation occurred in forty patients, corresponding to an incidence rate of 0.05% in diagnostic/screening procedures and 0.17% in therapeutic colonoscopies [4]. A greater risk of ICP was associated with low-volume practices, female gender (due to greater colonic length and a more mobile transverse colon), advanced age (reduced wall strength), history of diverticular disease, previous abdominal surgery (especially pelvic), and colonic obstruction (risk of over-insufflation) [4]. In a Netherland’s study including 30,366 endoscopic procedures found that ICP occurred in 35 patients (0.12%) [5]. The authors described a 4-fold higher risk of ICP in colonoscopies compared

with sigmoidoscopies and a 5-fold greater risk of ICP in therapeutic compared with diagnostic procedures. In our case series, when evaluated separately, perforation rate was 0.06% in diagnostic colonoscopy and 0.23% in interventional colonoscopy which is compatible with literature. Our nine (90%) ICP occurred during colonoscopy and one (10%) during sigmoidoscopy. The reasons for perforation in interventional colonoscopy were snare polypectomy in three patients and argon plasma coagulation of bleeding angiodysplasia in one patient. The diverticulosis was found in two patients who developed colon perforation due to diagnostic endoscopy, and the long-folded sigmoid colon anatomy and previous surgery were the predisposing factors in remaining 4 patients.

Iqbal et al [6] study, the perforation rates were higher at the rectosigmoid junction and the sigmoid colon (52%). The perforation rates in other sites of the colon were 17% (cecum), 14% (ascending colon), 7% (transverse colon), 8% (descending colon) and 1% (rectum), respectively. In our series, the most frequent locations of perforation were rectosigmoid and sigmoid (60%) and descending colon was 20%, cecum and transvers colon were 20% together. This was appropriate with the literature. The managements included surgical treatment in eight patients, endoscopic clipping of perforation and conservative management in one patient, and conservative treatment in one patient.

Perforation may result from direct mechanic effects (sharp edge) of the colonoscope, barotrauma, or thermal burns during polypectomy [6]. While perforation resulting from direct mechanic effects is often seen in the recto-sigmoid junction and strictures, perforation resulting from direct barotrauma is most frequently seen in the cecum zone [7]. Mechanical injury leads to the largest perforations, while electrocautery injury causes the smallest perforations. The patient dependent risks were anticoagulation usage, suboptimal bowel cleaning, active malignancy, and steroid usage. Other factors were the existence of dense or wide-mouthed diverticula, incomplete bowel preparation and active hemorrhage. The diverticulosis, the long-folded sigmoid colon anatomy and previous surgery were the predisposing factors in ICP in our series.

Some researchers observed that the perforation rate is higher in patients with two or more comorbidities [8-10]. In case series, 60% of colonic perforation was observed in patients with ASA scores greater than 2. Handami et al. [8] also reported female gender, older age, comorbidities and hypoalbuminemia as risk factors of increased ICP rates patients. In their study, perforation rates have been found to be higher during procedures performed for diagnosing nonspecific abdominal pain, iron deficiency anemia, inflammatory bowel disease and bleeding. In our series, colonoscopy indications in patients with ICP were constipation, colon cancer screening, acute lower gastrointestinal bleeding, iron deficiency anemia and chronic diarrhea.

For management, there is no gold standard method. Comorbidities, age, size and location of the perforation, and the time interval between the onset and diagnosis should be evaluated, and the treatment procedure should be planned. Sagawa et al. [11] proposed a treatment algorithm for ICPs as shown in figure 1. Conservative management, endoscopic clipping, laparoscopic or open operations from primary repair to

Hartmann's procedure can be used decision should be made on a case by case basis. Selective patients are likely to improve under conservative management. Generally, conservative treatment can be conducted if the patient has a small perforation, is in good general condition, and shows only mild signs of peritonitis. Such treatment requires bowel rest, the rapid administration of intravenous fluid therapy and broad spectrum antibiotics. With such treatment, clinical symptoms have been reported to improve usually within 24 hours [12,13]. Patients successfully treated non-surgically must be clinically stable, and their abdominal symptoms should improve rapidly with no deterioration due to peritoneal signs [13]. Conservative management in appropriate patients results in a shorter length of hospitalization and lower morbidity. In our series, one patient with microperforation after snare polypectomy developed localized mild abdominal pain and pneumoperitoneum with a mild increase in leukocytosis and C-reactive protein. She was followed with bowel rest, broad spectrum antibiotics and intravenous fluid therapy. Clinical symptoms improved within 24 hours and she was discharged on the fifth day of his admission.

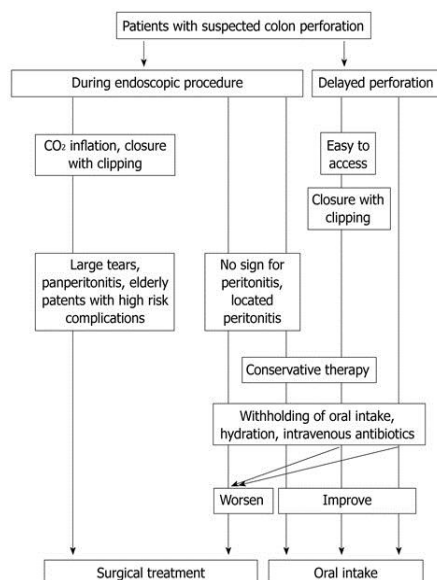


Figure 1: The management of iatrogenic colonic perforations

Intraoperative findings determine the surgical management [14]. Surgery may be primary closure or resection with primary anastomosis in cases of intra-abdominal contamination accompanied by normal tissues in order to limit the comorbidity. Due to the extensive contamination, poor tissue situation and a higher complication rate, stoma or fecal diversion after reparation is chosen. Iqbal et al [6] indicated that only two preoperative factors determined the type of procedure, the time after the perforation and mechanical injuries. Comparing patients who were diagnosed with perforation after 24 h, those within 24 h were more suitable for a primary closure because the latter was more likely to have extensive fecal contamination. Moreover, mechanical injury always induced larger perforations (average, 1.9 cm) which need fecal diversion after resection or resection and anastomosis. In our series, segmental colonic resection and anastomosis was treatment of choice in five patients because of large defects of perforation. In two late detected cases, more extensive operative procedures as right hemicolectomy and Hartmann's procedure with VAC were applied.

Currently the improvement of laparoscopic techniques and technology increase the practice of laparoscopic repair for ICP more widely [15]. In the Zhang et al [16] study, their experience in laparoscopic primary suturing of ICP indicated that laparoscopic perforation repair was a safe and feasible method. They reported that when compared with the open method, patients who underwent laparoscopic repair had a significantly shorter incision length (16 ± 15 mm vs 163 ± 54 mm), shorter length of hospital stay (5.1 ± 1.7 d vs 9.2 ± 3.1 d) and fewer perioperative complications (two vs five) [17]. Thus, they suggest that it is rational to regard laparoscopic therapy as the initial approach for repairing iatrogenic colorectal perforation. In our study group, one patient with sigmoid perforation detected during endoscopy operated at the 2nd hour of perforation laparoscopically. She had less pain and early mobilization and discharged at fourth day postoperatively. We think that in early detected perforations laparoscopic treatment might be safe and feasible.

In the recent study by Kim et al [18], 115285 diagnostic colonoscopies were performed with a total of 27 iatrogenic colon perforations (incidence of 0.02%). Endoscopic closure of the perforation site was attempted in 16 patients, with success in 13 patients. This suggests that immediate endoscopic closure with clips can be performed for diagnostic perforations as well as therapeutic colonoscopy-associated perforations. Jovanovic et al. [19] reported that endoscopic closure of colonic perforations could be performed when the perforation is < 1 cm. Some authors [22] have used the endoclips to treat perforations > 1 cm. Trecca et al. [20] reported 2 perforations > 3 cm that were managed by using endoclips successfully. Considering the technical challenge of endoclip application, an experienced endoscopist is the most important factor, as well as the site and size of the perforation. Clip closure was reported to be successful in 69% to 92% of cases [21]. In our series, one patient with sigmoid perforation of 0.5 cm size resulted from snare polypectomy was treated with endoclip application and conservative management as bowel resting, intravenous antibiotics and fluid resuscitation. She was discharged uneventfully on the sixth day of his admission

Experience of the endoscopist may decrease the perforation rates [22]. However, other than experience the various risk factors discussed previously contribute to the occurrence of ICPs. Lohsiriwat et al. [23] stated in their study of 10,124 patients that the experience of the endoscopist did not play a significant role in reducing complication rates. In our study, the experience of the endoscopists varied between 3 and 17 years. Of all cases in which perforations were documented, six were by endoscopists who had 6 to 8 years of experience, and four were by endoscopists who had 8 to 12 years of experience.

In our study, no significant difference in the rate of perforation between colonoscopies performed by gastroenterologists or surgeons has been noticed, so we may conclude that colonoscopies performed by surgeons are safe, with low morbidity and mortality.

In conclusion, ICPs are rare but most serious complications of both diagnostic and therapeutic colonoscopy procedures. All patients who will get colonoscopy and their families must be informed to be alert about this complication.

Special attention should be given to older and comorbid patients receiving therapeutic procedures during colonoscopy. Difficult and tough colonoscopies should be monitored closely at least 24 hours as early diagnosis is essential for treatment. For treatment there is no gold standard method, comorbidities, age, the size and location of the perforation, and the time interval between onset and diagnosis should be evaluated, and the treatment procedure should be planned. Conservative management, endoscopic clipping, laparoscopic or open operations from primary repair to Hartmann's procedure can be used, decision should be made on a case by case basis.

References

1. Fisher DA, Maple JT, Ben-Menachem T, Cash BD, Decker GA. ASGE Standards of Practice Committee. Complications of colonoscopy. *Gastrointest Endosc.* 2011;74:745–52.
2. Araghi-zadeh FY, Timmcke AE, Opelka FG, Hicks TC, Beck DE. Colonoscopic perforations. *Dis Colon Rectum.* 2001;44:713–6. doi:10.1007/BF02234572.
3. Hall C, Dorricott NJ, Donovan IA, Neoptolemos JP. Colon perforation during colonoscopy: surgical versus conservative management. *Br J Surg.* 1991;78:542–4.
4. Samalavicius NE, Kazanavicius D, Lunevicius R, Poskus T, Valantinas J, Stanaitis J, et al. Incidence, risk, management, and outcomes of iatrogenic full-thickness large bowel injury associated with 56,882 colonoscopies in 14 Lithuanian hospitals. *Surg Endosc.* 2013;27:1628–35. doi:10.1007/s00464-012-2642-4.
5. Luning TH, Keemers-Gels ME, Barendregt WB, Tan AC, Rosman C. Colonoscopic perforations: a review of 30,366 patients. *Surg Endosc.* 2007;21:994–7. doi:10.1007/s00464-007-9251-7.
6. Iqbal CW, Chun YS, Farley DR. Colonoscopic perforations: a retrospective review. *J Gastrointest Surg.* 2005;9:1229–35. discussion 1236.
7. Kang HY, Kang HW, Kim SG, Kim JS, Park KJ, Jung HC, et al. Incidence and management of colonoscopic perforations in Korea. *Digestion.* 2008;78:218–23.
8. Hamdani U, Naeem R, Haider F, Bansal P, Komar M, Diehl DL, et al. Risk factors for colonoscopic perforation: A populationbased study of 80118 cases. *World J Gastroenterol.* 2013;19:3596–601.
9. Arora G, Mannalithara A, Singh G, Gerson LB, Triadafilopoulos G. Risk of perforation from a colonoscopy in adults: a large population-based study. *Gastrointest Endosc.* 2009;69:654–64.
10. Gatto NM, Frucht H, Sundararajan V, Jacobson JS, Grann VR, Neugut AI. Risk of perforation after colonoscopy and sigmoidoscopy: a population-based study. *J Natl Cancer Inst.* 2003;95:230–6.
11. Sagawa T, Kakizaki S, Iizuka H, Onozato Y, Sohara N, Okamura S, et al. Analysis of colonoscopic perforations at a local clinic and a tertiary hospital. *World J Gastroenterol.* 2012;18(35):4898–904. doi:10.3748/wjg.v18.i35.4898
12. Christie JP, Marrazzo J. 3rd “Mini-perforation” of the colon—not all postpolypectomy perforations require laparotomy. *Dis Colon Rectum.* 1991;34:132–5.
13. Lo AY, Beaton HL. Selective management of colonoscopic perforations. *J Am Coll Surg.* 1994;179:333–7.
14. Taku K, Sano Y, Fu KI, Saito Y, Matsuda T, Uraoka T, et al. Iatrogenic perforation associated with therapeutic colonoscopy: a multicenter study in Japan. *J Gastroenterol Hepatol.* 2007;22:1409–14.
15. Mattei P, Alonso M, Justinich C. Laparoscopic repair of colon perforation after colonoscopy in children: report of 2 cases and review of the literature. *J Pediatr Surg.* 2005;40:1651–53.
16. Zhang YQ, Lu W, Yao LQ, Qin XY, Xu MD, Zhong YS, et al. Laparoscopic direct suture of perforation after diagnostic colonoscopy. *Int J Colorectal Dis.* 2013;28:1505–9.
17. Bleier JI, Moon V, Feingold D, Whelan RL, Arnell T, Sonoda T, Milsom JW, et al. Initial repair of iatrogenic colon perforation using laparoscopic methods. *Surg Endosc.* 2008;22:646–9.
18. Kim JS, Kim BW, Kim JI, Kim JH, Kim SW, Ji JS, et al. Endoscopic clip closure versus surgery for the treatment of iatrogenic colon perforations developed during diagnostic colonoscopy: a review of 115,285 patients. *Surg Endosc.* 2013;27:501–4.
19. Jovanovic I, Zimmermann L, Fry LC, Mönkemüller K. Feasibility of endoscopic closure of an iatrogenic colon perforation occurring during colonoscopy. *Gastrointest Endosc.* 2011;73:550–5.
20. Trecca A, Gaj F, Gagliardi G. Our experience with endoscopic repair of large colonoscopic perforations and review of the literature. *Tech Coloproctol.* 2008;12:315–21. discussion 322.
21. Taku K, Sano Y, Fu KI, Saito Y, Matsuda T, Uraoka T, et al. Iatrogenic perforation associated with therapeutic colonoscopy: a multicenter study in Japan. *J Gastroenterol Hepatol.* 2007;22:1409–14.
22. Dafnis G, Ekbohm A, Pahlman L, Blomqvist P. Complications of diagnostic and therapeutic colonoscopy within a defined population in Sweden. *Gastrointest Endosc.* 2001;54:302–9.
23. Lohsiriwat V. Colonoscopic perforation: incidence, risk factors, management and outcome. *World J Gastroenterol.* 2010;16:425–30.

The National Library of Medicine (NLM) citation style guide is used in this paper.

Suggested citation: Patrias K. Citing medicine: the NLM style guide for authors, editors, and publishers [Internet]. 2nd ed. Wendling DL, technical editor. Bethesda (MD): National Library of Medicine (US); 2007 [updated 2015 Oct 2; cited Year Month Day]. Available from: <http://www.nlm.nih.gov/citingmedicine>