

Case Report



A WAGR Syndrome Case with Postaxial Polydactyly

Hatice KOÇAK^{a1}, Gülay CEYLANER²

¹Ankara Dışkapı Çocuk Hastalıkları Eğitim ve Araştırma Hastanesi, Tıbbi Genetik, ANKARA, Türkiye

²İntergen Genetik Merkezi, ANKARA, Türkiye

ABSTRACT

The WAGR contiguous gene deletion syndrome is a combination of Wilms tumor, Aniridia, Genito-urinary abnormalities, and growth and mental Retardation which is invariably associated with an 11p13 deletion. This deletion included the PAX6 and WT1 genes as previously reported in typical WAGR patients. Ocular defects result from hemizygosity for the PAX6 gene. Urogenital and renal abnormalities and predisposition to nephroblastoma are related to hemizygosity for the Wilms tumor suppressor gene WT1. We report an 8-year-old boy with WAGR syndrome and additional unusual clinical features. He had developmental delay, growth deficiency, severe ocular involvement, operated Wilms tumor and postaxial polydactyly. Cytogenetic and fluorescent in situ hybridization (FISH) analyses identified a deletion, del (11) (p11.2p13). Although the simultaneous appearance of WAGR and preaxial polydactyly has been already described, to our knowledge this is the first case in which the postaxial polydactyly is reported. The unusual anomalies described in this report may be another features of the WAGR syndrome and suggest the existence of a related gene in the WAGR critical region or in its proximity.

Key words: Seminal vesicle, agenesis, anomalie, infertility

ÖZET

Postaksiyel Polidaktilili WAGR Sendromu Vakası

WAGR bitişik gen delesyonu sendromu; Wilms tümörü, aniridi, genitor-üriner anomaliler, büyüme geriliği ve mental geriliğin bir kombinasyonu olup, istisnasız 11p13 delesyonu ile ilişkilidir. Bu delesyon, tipik WAGR Sendromlu hastalarda daha önce bildirildiği gibi PAX6 ve WT1 genlerini içerir. Oküler defektler PAX6 geninin hemizigozitesinden kaynaklanır. Ürogenital ve renal anomaliler ile nefroblastoma yatkınlık ise; Wilms Tümör baskılayıcı gen WT1'in hemizigozitesiyle ilişkilidir. WAGR Sendromuna ek olarak nadir klinik özellikleri olan 8 yaşında bir erkek hastayı sunuyoruz. Olguda büyüme ve gelişme geriliği, şiddetli oküler tutulum, opere Wilms Tümörü ve postaksiyel polidaktili mevcuttu. Sitogenetik ve Floresan İn Situ Hibridizasyon (FISH) analizleri ile bir delesyon tespit edildi: del (11) (p11.2p13). WAGR Sendromu ve preaksiyel polidaktili birlikteliği daha önce tanımlanmış olmakla beraber, bugünkü bilgilerimize göre bu vaka; postaksiyel polidaktilinin bildirildiği ilk vakadır. Burada tanımlanan nadir anomaliler WAGR Sendromunun diğer özellikleri olup, WAGR kritik bölgesi veya daha proksimalinde ilişkili bir genin varlığını gösterebilir.

Anahtar kelimeler: Seminal vezikül, agenez, anomalie, infertilite

The association of aniridia, congenital anomalies, and Wilms tumor (WT) was first described by Miller et al. (1), and subsequently defined by the acronym of WAGR syndrome, where W refers to WT, A to aniridia, G to genitourinary abnormalities, and R to growth and mental retardation (OMIM #194072). The prevalence of WAGR syndrome is lower than 1 in 100,000 births. WAGR is associated with an increased risk of developing Wilms tumor, which can occur at any age, and with total or partial aniridia with possible glaucoma or cataract, genitourinary disorders ranging from sexual ambiguity to ectopic testis, and variable degrees of intellectual deficit (2). This syndrome is one of the best-studied 'contiguous gene syndromes'. The location of genes responsible for this syndrome was initially suggested by the association of cytogenetically visible interstitial deletions of the chromosome 11, involving invariantly part or all of band p13 (3). Expression of the WAGR-associated phenotypes, however, was noted to be variable even in patients with cytogenetically apparently identical deletions (4). Molecular studies of this chromosomal region led to the identification of hemizygosity for the ocular development gene PAX6, the

Wilms tumor suppressor gene WT1 and other genes mapped to a 700 kb interval in distal 11p13 (5).

We describe here a patient with WAGR syndrome and additional unusual clinical anomalies.

CASE REPORT

Patient, a boy, was born after an uneventful pregnancy to consanguineous Turkish parents at 40 weeks gestation. Birth weight was 3150 g (25-50 percentiles) and length was 51 cm (50-75 percentiles). He had facial dysmorphism (Figure 1a), including brachycephaly, coarse hair, frontal upsweep, synophrys, bilateral ptosis, downslanted palpebral fissures, epicanthal fold, long eyelashes, cataract on the left eye, bilateral nystagmus, depressed nasal bridge, thick alae nasi, overfolded ears, high palate and jagged four inferior incisors. In addition to he showed (Figure 1b) kyphosis, up position of shoulders, pectus excavatum, horizontal operation scar of Wilms tumor on superior abdominal quadrant, inguinal hernia and cryptorchidism on the right and bilateral postaxial

^a Corresponding Adress: Dr. Hatice KOÇAK, Ankara Dışkapı Çocuk Hastalıkları Eğitim ve Araştırma Hastanesi, Tıbbi Genetik, ANKARA, Türkiye
Tel: +90 312 5969757 Fax: +90 312 3472330 e-mail: drhaticekocak@hotmail.com

polydactyly scar of the feet (Figure 2). At the ophthalmologic examination, bilateral aniridia, bilateral congenital cataract, macular hypoplasia and bilateral horizontal nystagmus with rotatuar components were found.

Growth deficiency and psychomotor delay were noted. He was hypotonic at birth. He walked unsupported at 2 years, and spoke his first words at age 3 years. His extra toes were removed shortly after birth. His sister also had bilateral postaxial polydactyly of the hand at birth. They were also removed (Figure 3). Bilateral aniridia was diagnosed at age 3 months. At 3 years of age, a left kidney tumor was detected. The Wilms tumor was surgically removed, followed by chemotherapy consisting of 5 cures vincristine and actinomycin-D treatment. Surgery for cataract was performed at 6 years. The case developed epilepsy at 7 years. At the last follow up

at age 8 years and 2.5 months, he was 116 cm tall (< 3rd centile), weighted 21 kg (3-10th centile) and had an OFC 53 cm (50-98th centile).

The cranial magnetic resonance imaging showed the milimetric Thornwaldt cyst of the nasopharynx and inflammatory changes in maxillary, frontal, ethmoid and mastoid sinuses, cranial computed tomography and EEG were normal. There was compensatory hypertrophy of right kidney (114x43mm) in abdominal ultrasound, while renal function was normal.

High-resolution cytogenetic testing at the 500-550 band level detected a constitutional deletion on chromosome 11, involving the p11.2-p13 region (Figure 4). The same deletion was also demonstrated by FISH analysis.

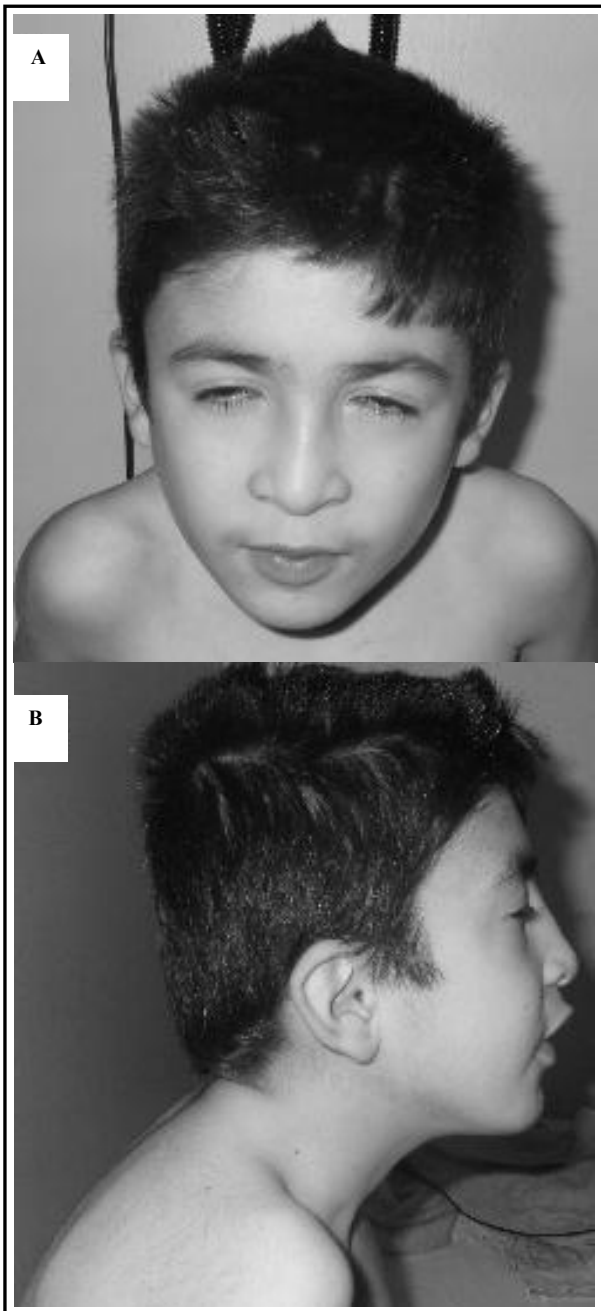


Figure 1. Dysmorphic facial findings of propositus A) Frontal B) Side.

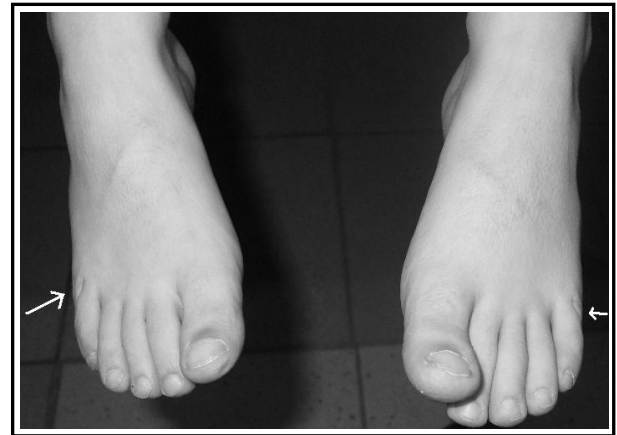

Figure 2. Bilateral postaxial polydactyly scar of the feet.

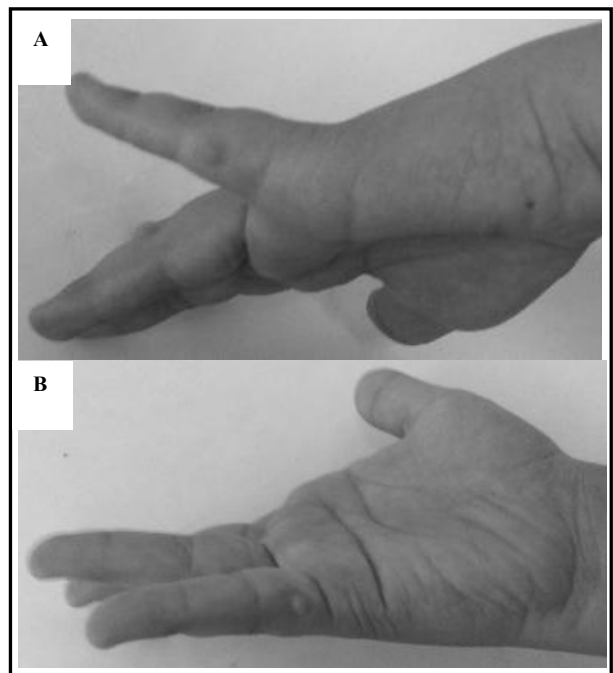


Figure 3. Bilateral postaxial polydactyly scars of the propositus' sister.

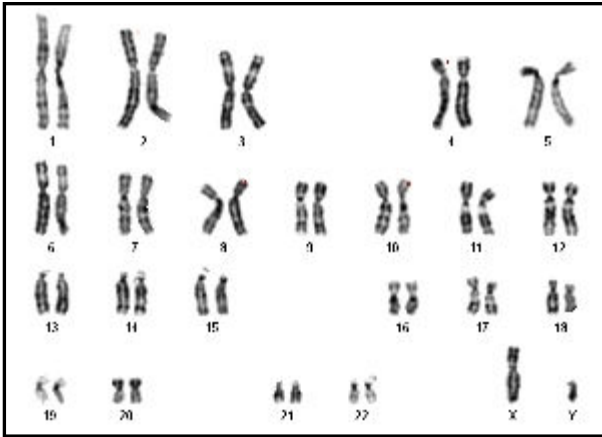


Figure 4. Cytogenetic analysis. It showing G-banded Chromosomes; del (11)(p11.2p13).

DISCUSSION

WAGR is an acronym for: Wilms tumor, Aniridia, Genitourinary anomalies and mental Retardation. A combination of two or more of these clinical features is normally required for an individual to be diagnosed with WAGR syndrome (6). The patient described in this report meets the diagnostic criteria for WAGR syndrome, both clinically and cytogenetically. Karyotypic examination revealed a deletion in p11.2-p13. In addition to, the cytogenetic results were confirmed with FISH analysis. It was used for FISH analysis that the PAX6 probe which obtained from clone RP11-26B16. Similar deletions were previously reported (2,4,7,8). The microdeletion is de novo in most cases, but it may result from an inherited parental translocation. The karyotype of the patient should be determined to detect the presence of such a translocation (9). The parents of our case had no chromosomal rearrangement.

Children with WAGR syndrome generally present in the newborn period with sporadic aniridia (6). The feature invariably present in all documented cases is aniridia. Only one patient who had WAGR without aniridia has published (10). Aniridia occurs in 1 in 50–100,000 newborns (7) and it exists both as sporadic cases and as familial cases with an autosomal dominant mode of inheritance. Approximately one third of patients with sporadic aniridia will have WAGR syndrome. Both forms of aniridia are caused by mutations in the PAX6 gene (6,7). The combination of sporadic aniridia along with genital anomalies may alert the clinician to the possibility of WAGR syndrome, although genitourinary anomalies are not always present, particularly in girls. For this reason, it is recommended that all infants with sporadic aniridia be evaluated carefully for WAGR syndrome. The most common abnormality of the genitourinary tract was cryptorchidism, found in 60% of male patients (6).

According to recent research, deficiencies in the PAX6 gene result in abnormalities not only of the eye but also possibly of the central nervous system and endocrine pancreas (11, 12). Mental retardation was the most common

neurologic manifestation of WAGR syndrome and was found in 70% of patients (6). The genetic basis of mental retardation in WAGR remains to be explained. There is great variability in the cognitive abilities of children with WAGR syndrome, from profound mental retardation to “borderline” or even normal IQ.

The majority of these cases with FISH detected cryptic deletions involving WTI were reported to have developed Wilms tumors. It has been suggested that about 1 in 70–90 children with Wilms tumor has aniridia (2). Wilms’ tumor is an embryonal tumor that normally affects approximately 1 in 10 000 children. In patients with WAGR syndrome, the risk has been estimated to be up to 45% (13). The development of Wilms tumor in patients with WAGR syndrome has a more rapid time course than of a sporadic Wilms tumor. Mean age at diagnosis of Wilms tumor in WAGR syndrome is 28.6 months (median: 17months) compared to a mean of 36 months and a median of 33 months in unilateral, non-syndromic Wilms tumor (2). Wilms’ tumor is considered unusual after age 5, renal ultrasound is recommended every 3 months from birth until age 6. After age 6, a thorough physical examination should be performed to assess for abdominal masses every 6 months until age 8 and every 6 to 12 months thereafter. Clinicians should maintain a high index of suspicion for Wilms’ tumor in patients of any age with WAGR syndrome. The cumulative risk of renal failure in patients with WAGR syndrome at 20 years of age is 53% (6). The majority of patients who have a sporadic Wilms’ tumor and subsequent nephrectomy do not develop renal failure. This suggests that additional factors may contribute to the development of renal disease in patients with WAGR syndrome.

Bernard et al. (2005) showed the ratio of nonclassical clinical findings in 54 cases with WAGR Syndrome in literature (6). The patient reported here had some of these rare manifestations such as cataracts [36], nystagmus [22], macular hypoplasia [7], ptosis [2], cryptorchidism [19], inguinal hernia [3], hypotonia [7], epilepsy [4], tonsillectomy and adenoidectomy [22], kyphosis [8]. These unusual anomalies could be very low penetrant traits associated with haploinsufficiency of one of the genes present in the critical WAGR region. There are four cases had duplication of halluces in literature (2, 4) but to our knowledge, this is the first case with postaxial polydactyly. This finding may be unrelated and a familial feature as his sister also had postaxial polydactyly. On the other hand, this may be a new feature of this syndrome. Cytogenetic analysis showed a deletion more proximal than that observed in the cases with thumb duplication in this case. This may be the reason of this and other additional features.

In summary; we are presenting a case with very rare features including postaxial polydactyly, epilepsy and ptosis. To our knowledge, this is the first case with postaxial polydactyly. This is very important to know, WAGR syndrome cases may have very rare additional features and these features may mislead during diagnostic studies.

REFERENCES

1. Miller RW, Fraumeni Jr JF, Manning MD. Association of Wilms’s tumor with aniridia, hemihypertrophy and other congenital malformations. *N Engl J Med* 1964; 270: 922- 927.
2. Brémond-Gignac D, Gérard-Blanluet M, Copin H, et al. Three patients with hallucal polydactyly and WAGR syndrome, including discordant expression of Wilms tumor in MZ twins. *Am J Med Genet A* 2005; 134:422-425.

3. Brémond-Gignac D, Crolla JA, Copin H, et al. Combination of WAGR and Potocki-Shaffer contiguous deletion syndromes in a patient with an 11p11.2-p14 deletion. *Eur J Hum Genet* 2005; 13:409-413.
4. Manoukian S, Crolla JA, Mammoliti PM, et al. Bilateral preaxial polydactyly in a WAGR syndrome patient. *Am J Med Genet A* 2005; 134:426-429.
5. Ton CC, Hirvonen H, Miwa H, et al. Positional cloning and characterization of a paired box- and homeobox-containing gene from the aniridia region. *Cell* 1991; 67:1059-1074.
6. Fischbach BV, Trout KL, Lewis J, Sika M. WAGR Syndrome: A Clinical Review of 54 Cases. *Pediatrics* 2005; 116:984-988.
7. Crolla JA, van Heyningen V. Frequent chromosome aberrations revealed by molecular cytogenetic studies in patients with aniridia. *Am J Hum Genet* 2002; 71:1138-1149.
8. Marlin S, Couet D, Lacombe D, Cessans C, Bonneau D. Obesity: a new feature of WAGR (del 11p) syndrome. *Clin Dysmorphol* 1994; 3:255-257.
9. Huff V. Parental origin of WT1 mutations and mental retardation in WAGR syndrome. *Nat Genet* 1994; 8:13-14.
10. Turleau C, de Grouchy J, Nihoul-Fekete C, et al. Del11p13/nephroblastoma without aniridia. *Hum Genet* 1984; 67:455-456.
11. Talamillo A, Quinn JC, Collinson JM, et al. PAX6 regulates regional development and neuronal migration in the cerebral cortex. *Dev Biol* 2003; 255:151-163.
12. Yasuda T, Kajimoto Y, Fujitani Y, et al. PAX 6 mutation as a genetic factor common to aniridia and glucose intolerance. *Diabetes* 2002; 51:224-230.
13. Muto R, Yamamori S, Ohashi H, Osawa M. Prediction by FISH analysis of the occurrence of Wilms' tumor in aniridia patients. *Am J Med Genet* 2002; 108:285-289.

Kabul Tarihi:23.04.2009