

KORONER TROMBÜSÜN NEDEN OLDUĞU AKUT KORONER SENDROMLU ÜÇ OLGUNUN DEĞERLENDİRİLMESİ

EVALUATION OF THREE CASES WITH ACUTE CORONARY SYNDROME CAUSED BY CORONARY THROMBUS

Aysel GÜVEN BAĞLA¹, Meltem İÇKİN GÜLEN¹, Bahadır KIRILMAZ², Ertuğrul ERCAN³

¹Çanakkale Onsekiz Mart Üniversitesi Tıp Fakültesi, Histoloji ve Embriyoloji Ana Bilim Dalı

²Çanakkale Onsekiz Mart Üniversitesi Tıp Fakültesi, Kardiyoloji Ana Bilim Dalı

³İzmir Üniversitesi Tıp Fakültesi, Kardiyoloji Ana Bilim Dalı

ÖZET

Akut miyokard infarktüsü olan hastalarda koroner trombus, kan akımının azalmasına neden olur. Amacımız, üç olguda trombus analizi yaparak, trombusun neden olduğu koroner oklüzyon mekanizmalarının anlaşılmasına katkıda bulunmaktır. Olgulara koroner anjiyografi ile ST elevasyon tipi miyokard infarktüsü tanısı konuldu. Trombuslarda histopatolojik inceleme ve PTX3 (Pentraksin 3, bir akut faz proteini) ve CD68 (monosit ve makrofajlardan salınan bir sitokin) ile immünohistokimyasal boyama yapıldı. Ayrıca troponin ve PTX3 kan düzeyleri ölçüldü. PTX3 immün boyama skoru, tüm vakalarda yüksekti ve kan düzeyleri ile uyumlu değildi. PTX3 kan düzeyi normal olan vakada boyama yoğunluğunun fazla olmasının, PTX3'ün hızlı lokal salınımı sonucu olabileceği düşünüldü. En yüksek PTX3 kan düzeyi olan vakada, bu artışı sağlayabilecek başka bir inflamatuvar hastalık vardı. PTX3 ve CD68 immün boyamalarının, koroner trombusun histopatolojik değerlendirilmesinde bir belirteç olarak kullanılabileceğini düşünüyoruz.

ANAHTAR KELİMELER: Akut koroner sendrom, CD68, Koroner trombus, Pentraksin 3

ABSTRACT

Coronary thrombus causes reduced blood flow in patients with acute myocardial infarction. Our aim was to contribute to the understanding of the mechanisms of coronary occlusion caused by thrombus, evaluating the histopathological characteristics of thrombi in three cases. Cases were diagnosed with ST elevation type of myocardial infarction by coronary angiography. Histopathological analysis of thrombi as well as immunohistochemical staining with PTX3 (pentraxin 3, an acute phase protein) and CD68 (a cytokine released from monocyte and macrophages) were performed. Blood levels of troponin and PTX3 were also evaluated. The PTX3 immunostaining score was high in all cases but it was not consistent with its blood level. The high PTX3 staining intensity in the case with normal PTX3 blood level may be the result of rapid local release of PTX3. Case with highest PTX3 blood level had another inflammatory disease that could have driven this increase. We suggest that PTX3 and CD68 immunostainings can be used as a marker in the histopathological evaluation of coronary thrombus.

KEYWORDS: Acute coronary syndrome, CD68, Coronary thrombus, Pentraksin 3

Geliş Tarihi / Received: 29.05.2019

Kabul Tarihi / Accepted: 15.04.2020

Yazışma Adresi / Correspondence: Prof.Dr.Aysel GÜVEN BAĞLA

Çanakkale Onsekiz Mart Üniversitesi Tıp Fakültesi, Histoloji ve Embriyoloji Ana Bilim Dalı

E-mail: drayselguven@yahoo.com

Orcid No (Sırasıyla): 0000-0002-1501-9324, 0000-0002-6364-8344, 0000-0002-5929-1426, 0000-0003-0480-4738

INTRODUCTION

Coronary angiography techniques have shown how often coronary thrombus formation occurs in patients with acute myocardial infarction (AMI) (1). Atherosclerotic plaques reveal infiltration by activated macrophages, T cells and mast cells. CD68 is expressed by monocytes and macrophages and CD68 immunostaining was used as an indicator of macrophages in a study detecting inflammatory cell content of coronary thrombi (2). Fuijkschot et al. showed CD68 positive monocytes/macrophages were more present in lytic than in fresh and organized thrombi (2). Pentraxin 3 (PTX3) is an acute phase protein which takes place in the same family with C-reactive protein and is involved in the regulation of inflammatory reactions (3).

PTX3 is produced by major cell types involved in atherosclerotic lesions in consequence of inflammatory stimuli, therefore it may have a pathogenic role in AMI (4). PTX3 may be a new biomarker for inflammatory vascular disease and cardiovascular events (5). In the present report, histopathological examination as well as immunohistochemical detection of CD68 and PTX3 in three cases with ST elevation myocardial infarction (STEMI) are represented.

CASE REPORT

Three patients who applied to our hospital with chest pain, underwent coronary angiography and were diagnosed with hyperacute STEMI. Their blood pressures were within normal limits and hemodynamics were stable. Blood samples were taken for determination of pre-treatment troponin and pentraxin 3 levels (**Table 1**). LDL cholesterol levels were above 130 mg/dL, except the second case. Case I had thrombus formation in native coronary artery, Case II had thrombus formation within the stent placed in native coronary artery (while having dual antiplatelet treatment; acetyl salicylic acid (ASA) + clopidogrel), Case III had thrombus formation in a vein.

Table 1: Biochemistry and characteristics of the cases

Case	Troponin level (mg/dl)	PTX3 level (ng/mL)	Risk Factors	Medication	Event	Age
Case 1	130	0,897	smoking hypertension	none	no reflow	34
Case 2	168	18,421	hypertension hyperlipidemia diabetes	statin clopidogrel ASA	ulcerative colitis	54
Case 3	12	2,168	hypertension hyperlipidemia diabetes	ASA	with bypass thrombus in saphenous vein graft	51

ASA: Acetyl Salicylic Acid

CASE I

A 34 year old male patient with hypertension and smoking history, referred with a 4 hour chest pain and diagnosed with hyperacute anterior MI. There was no significant plaque formation, observed with coronary angiography. Large red thrombus was observed in the proximal part of the left anterior coronary artery (**Figure 1**).

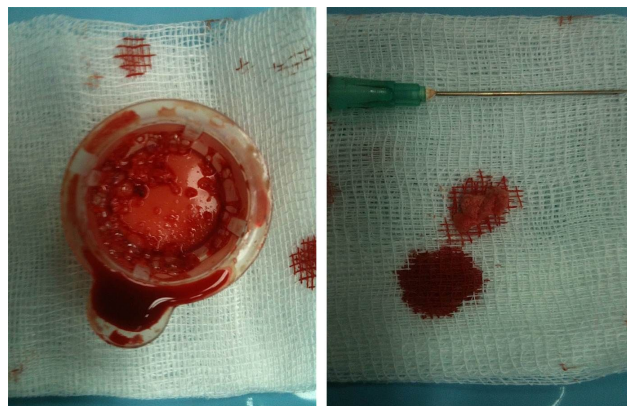
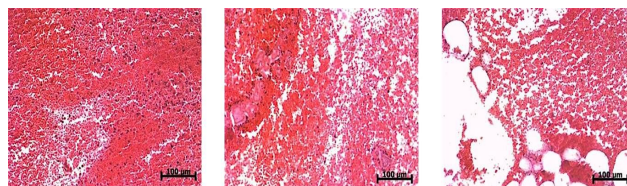


Figure 1: Case 1 macroscopic view of thrombus. Large red thrombus was seen from the aspirated material in Case 1

The procedure was successful, but no-reflow phenomenon was observed after the procedure. Successful direct stent implantation was performed after thrombus aspiration. The patient was discharged after a 5 day hospitalization. Histopathological evaluation by hematoxylin eosin staining revealed erythrocyte rich red thrombus (**Figure 2**), PTX3 immunostaining of thrombus material was evaluated as score 3 and CD68 as score 2 in this case, who had the lowest PTX3 blood level (**Figure 3 and 4**).

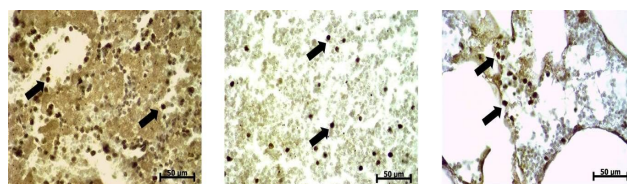


Case 1

Case 2

Case 3

Figure 2: Microscopic view of thrombi (H&E stain). All cases had red thrombus and diffuse infiltration of erythrocytes were observed. Scale bar = 100 μ m



Case 1

Case 2

Case 3

Figure 3: PTX3 immunostaining of thrombi. All cases took score 3 for PTX3 staining, so that more than 50% of macrophages (arrows) expressed PTX3 immunostaining. Staining intensity in each section was scored in 10 fields (x40 objective): score 0 = no staining, score 1 = weak and focal staining (positivity in <25% of the tissue area/cellular component), score 2 = moderate staining (25-50% positive), score 3 = dense and diffuse staining (> 50% positive) (7). Scale bar = 50 μ m

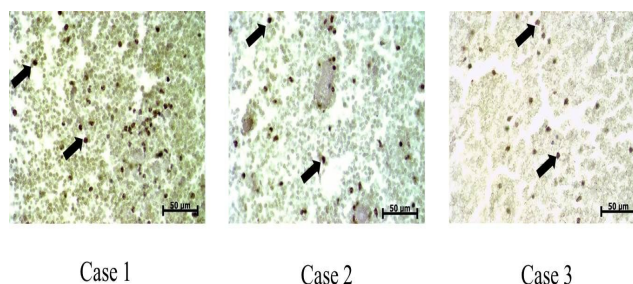


Figure 4: CD68 immunostaining of thrombi. Case 1 took score 2 for CD68 staining, which was moderate, meaning 25-50% of macrophages (arrows) stained positive. The score was 3 for cases 2 and 3, more than 50% of macrophages (arrows) expressed CD68 immunostaining. Staining intensity in each section was scored in 10 fields (x40 objective): score 0 = no staining, score 1 = weak and focal staining (positivity in <25% of the tissue area/cellular component), score 2 = moderate staining (25-50% positive), score 3 = dense and diffuse staining (> 50% positive) (7). Scale bar = 50 µm

CASE II

A 54 year old male patient with diabetes, hyperlipidemia and hypertension, moreover with ulcerative colitis. An elective left anterior coronary artery stent implantation was performed 3 days before. He had been suffering from diarrhea before and after the procedure. He was taking dual antiplatelet treatment, as ASA + clopidogrel. He referred with a 10 hour chest pain. Coronary angiography revealed thrombus formation within the stent. Successful angioplasty was performed after thrombus aspiration.

Histopathological evaluation by hematoxylin eosin staining revealed erythrocyte rich thrombus (Fig. 2), both PTX3 and CD68 immunostainings of thrombus material was evaluated as score 3 in this case, who had the highest PTX3 and troponin blood levels (Fig.s 3 and 4). The patient unfortunately died after 10 days of intensive care.

CASE III

A 51 year old male patient with diabetes, hyperlipidemia and hypertension who underwent triple bypass surgery 7 years before. He referred with a 16-hour chest pain. Coronary angiography revealed occlusion with thrombus in saphenous vein graft connected to the circumflex coronary artery. Stent implantation was performed successfully after thrombus aspiration. The distal flow was observed to be reduced after the procedure (**Figure 5**).

The patient was discharged after 4 days of hospitalization. Histopathological evaluation by hematoxylin eosin staining revealed erythro-

cyte rich red thrombus (Fig. 2), both PTX3 and CD68 immunostainings of thrombus material was evaluated as score 3 in this case (Fig.s 3 and 4).

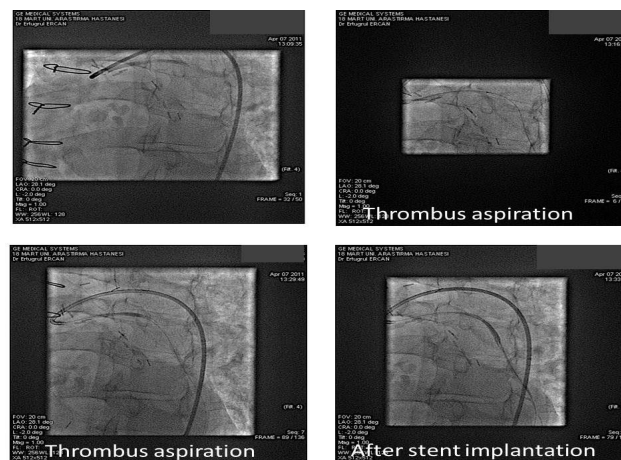


Figure 5: Case 3 Coronary angiogram. Image showed stent occlusion by thrombus. Thrombus aspiration and stent implantation enabled blood flow

DISCUSSION

Occlusive coronary artery thrombi are composed of a mixture of white (platelet rich) and red (rich in fibrin and erythrocyte) thrombi. Our cases had STEMI and red thrombus. Inflammation and tissue damage trigger nonspecific acute phase response. PTX3 is an acute phase protein in humans and blood levels rapidly increase during inflammatory and infectious conditions and cardiovascular events in parallel with the severity of the disease (5). Savchenko et al. have shown localized PTX3 production in inflammatory vessel lesions such as atherosclerotic plaques (6). PTX3 can be an early indicator of activation of both immune and inflammatory responses and a biomarker for inflammatory vascular disease and cardiovascular events (5). It is associated with severity of cardiovascular disease and restenosis, and therefore, it has prognostic value in patients with STEMI (7).

Case II had highest PTX3 blood level, he died after 10 days of intensive care. He had ulcerative colitis in addition to acute coronary disease which may have led to a further increase in PTX3 blood level. Thrombus PTX3 immunostaining was intense in Case I with normal PTX3 blood level. He referred with a 4 hour chest pain, earlier than the other two cases. The high staining intensity in the thrombus material prior to the increase in blood, may show the rapid local rele-

ase of PTX3. Immunostaining of CD68 was also detected in the thrombus materials, so that it is expressed by monocytes and macrophages. The high intensity of PTX3 and CD68 immunostainings of the thrombus material can also give us an idea of the prognosis of Case II. Thrombus PTX3 and CD68 immunostainings were evaluated as score 3 in case III, although PTX3 blood level was borderline and troponin blood level was low. This blood PTX3 level may be the result of the transient rise in plasma concentrations of this protein (8). Maugeri et al. found that PTX3 bound to activated platelets and dampened their inflammatory potential (8).

Blasco et al. reported CD68 immunohistochemical staining in thrombus aspirate was a good method for plaque detection (9). The presence of plaques appears to be associated with a more favorable outcome and plaque absence could be used as a marker for the need for more intensive preventive strategies involving antiplatelet and anticoagulant drugs (10). Immunohistochemical evaluation as well as histopathological evaluation of thrombus will provide more detail to confirm the relationship between thrombus characteristics and underlying plaque morphology, in addition to cardiovascular imaging methods of patients with STEMI. We suppose PTX3 and CD68 immunostainings can be used as markers in histopathological evaluation of coronary thrombus.

REFERENCES

1. Ambrose JA, Winters SL, Stern A, et al. Angiographic morphology and the pathogenesis of unstable angina pectoris. *J Am Coll Cardiol*. 1985;5(3):609-16.
2. Fuijkschot WW, Groothuizen WE, Appelman Y, et al. Inflammatory cell content of coronary thrombi is dependent on thrombus age in patients with ST-elevation myocardial infarction. *J Cardiol*. 2017;69(1):394-400.
3. Bottazzi B, Bastone A, Doni A, et al. The long pentraxin PTX3 as a link among innate immunity, inflammation, and female fertility. *J Leukoc Biol*. 2006;79(5):909-12.
4. Yunoki K, Naruko T, Sugioka K, et al. Thrombus aspiration therapy and coronary thrombus components in patients with acute ST-elevation myocardial infarction. *J Atheroscler Thromb*. 2013;20(6):524-37.
5. Bonacina F, Baragetti A, Catapano AL, et al. Long pentraxin 3: experimental and clinical relevance in cardiovascular diseases. *Mediators Inflamm*. 2013;2013:725102.

6. Savchenko A, Imamura M, Ohashi R, et al. Expression of pentraxin 3 (PTX3) in human atherosclerotic lesions. *J Pathol*. 2008;215:48-55.
7. Latini R, Maggioni AP, Peri G, et al. Lipid Assessment Trial Italian Network (LATIN) Investigators. Prognostic significance of the long pentraxin PTX3 in acute myocardial infarction. *Circulation*. 2004;110(16):2349-54.
8. Maugeri N, Rovere-Querini P, Slavich M, et al. Correction: Early and transient release of leukocyte pentraxin 3 during acute myocardial infarction. *J Immunol*. 2011;187(12):970-9.
9. Blasco A, Bellas C, Goicolea L, et al. Immunohistological Analysis of Intracoronary Thrombus Aspirate in STEMI Patients: Clinical Implications of Pathological Findings. *Rev Esp Cardiol (Engl Ed)*. 2017;70:170-7.
10. Takashima A, Shimabukuro M, Tabata M, et al. Histopathological heterogeneity of in-stent restenosis in four coronary endarterectomy specimens. *Cardiovasc Pathol*. 2015;24:194-7.