

Compatibility of clinical presentation and imaging for patient with multiple lumbar canal stenosis at Wahidin Hospital

Andika Thehumury, Ruksal Saleh, Jainal Arifin

¹Department of Orthopaedic and Traumatology, Hasanuddin University, Makassar, Indonesia

ABSTRACT

Background: The numbers of surgical procedures performed for lumbar spinal stenosis has increased steadily over the years. Diagnosis of the patients with lumbar canal stenosis and decision for decompression was mainly with magnetic resonance imaging (MRI). Majority of patients will end up with multilevel decompression.

Material and Method: This was a cross-sectional analytical study. Patient who was diagnosed with multiple lumbar canal stenosis by 3 orthopedic broad certified spine surgeons based on clinical presentation and computerized tomography (CT) myelography and MRI will undergo decompression surgery. Functional outcome was evaluated by using Japanese orthopedic association back pain evaluation questionnaire (JOABPEQ) score. The proportion of patients who has match and unmatched clinical presentation and imaging was evaluated with Fisher exact test.

Results: Majority of the patients (90%) who decompressed with match clinical presentation and imaging study will has to improve JOABPEQ score 3 months follow up. Patients who decompressed with unmatched clinical presentation and imaging study 75% will had to improve JOABPEQ score and 25 % had decrease JOABPEQ score.

Conclusions: Determining the level of decompression in patient with multiple lumbar canal stenosis should be based on clinical presentation of the patients rather than using imaging study. However, further authentication is required by doing long term studies.

Keywords: Multiple lumbar canal stenosis, MRI, CT myelography, decompression, Japanese orthopedic association back pain evaluation questionnaire, JOABPEQ

INTRODUCTION

Lumbar Spinal Stenosis (LSS) is a disabling condition characterized by narrowing of the central and lateral spinal canals causing back pain and neurologic deficit, often leading to substantial disability (1). It is estimated that more than 200.000 adults are affected by LSS in the United States (2), and will rise to 64 million elderly adults by the year 2025 (3). The Framingham study (4) found that congenital re-

lative LSS was 4.7% and absolute LSS was 2.6%, acquired relative and absolute LSS was 22.5%, and 7.3%, respectively, for 60–69 years old population, the relative and absolute LSS was 47.2% and 19.4%, respectively. A population-based study in Japan (5) found that the LSS incidence was increased by age; there are about 1.7– 2.2% in 40–49 years old population and 10.3%–11.2% in 70–79 years old population. Another study reported the incidence of symptomatic LSS was about 10% (6).

Corresponding Author: Andika Thehumury, Jl. Perintis Kemerdekaan km. 10. Zip Code: 90245, Makassar, Indonesia

Phone: 087849508811

E-mail: andikathehm@gmail.com

Received: 25.01.2019 **Accepted:** 02.04.2019 **Doi:** 10.32322/jhsm.517616

Cite this article as: Thehumury A, Saleh R, Arifin J. Compatibility of clinical presentation and imaging for patient with multiple lumbar canal stenosis at Wahidin Hospital. J Health Sci Med 2019; 2(3): 75-78.



The LSS is the most common reason for more than 65 years old patients to undergo spinal surgery (7). During 2002 to 2007, the rate of lumbar stenosis surgery per 100,000 Medicare beneficiaries is about 135.5–137.5 persons, the mean hospital charges for decompression alone is about \$23.724 and combined with fusion is \$80.888, and in 2009, the hospital bill for LSS for Medicare beneficiaries was \$1.65 billion (8). The narrowing factors could be the intervertebral disc herniation, hypertrophy of ligamentum flavum, hypertrophy of facet joint, spondylolisthesis, osteophyte and ectopic fat tissue.

Because such diverse pathology leads to diverse symptoms, an accurate diagnosis is important for deciding treatment modality and predicting prognosis, but it is not easy to decide and confirm the main pathology leading to symptoms especially in cases involving multiple segments (9). Central LSS is defined by measurements of the diameter or area of the thecal sac or spinal canal based on imaging studies. Now, magnetic resonance imaging (MRI) is accepted as a primary diagnostic tool for degenerative lumbar spine disease as a result of the development of its technology and investigations about reader interpretation (10). Compared with MRI, usage of computerized tomography myelography (CTM) has diminished, but it is usually reserved for the patients for whom MRI results were ambiguous or technically suboptimal. Many studies compared the efficiency of MRI and CTM and showed diverse results

The aims of this study are to analyze the compatibility of clinical symptoms and radiological examination. The radiological examination is divided into two modalities (MRI and CT myelography). In this study, we also evaluated the level of stenosis of a multiple lumbar canal stenosis patients. We use the Japanese orthopedic association back pain evaluation questionnaire (JOABPEQ) score to analyze the outcome of the patient after the decompression surgery based on the clinical presentation of the patients.

MATERIAL AND METHOD

We reviewed 31 patients (17 men, and 14 women) who had undergone decompression surgery (interlaminar decompression for lumbar canal stenosis) at Wahidin Hospital from January 2018 to July 2018. The inclusion criteria were neurologic claudication such as numbness or burning sensation in one or both legs. Exclusion criteria were (1) compression fracture at the lumbar spine due to trauma or osteoporosis; (2) Patients with degenerative lumbar scoliosis; (3) Any previous lumbar spine surgery; (4)

Patient with any contraindications to repeat MRI such as autoimmune disorders or the use of platelet anti-aggregates and anticoagulants; (5) Patient that allergic to contrast.

The 31 patients underwent MRI (Spine surface coil 1.5 T (Toshiba, ExcelArt AG)) and CTM (High-Speed Aquilion Lighting Multislice detector 10, Toshiba). All the patients who had the symptom of Lumbar canal stenosis would undergo MRI and CTM examination. After the MRI and CTM 3 certified, broad spine surgeon would decide the level of decompression for the patients based on the clinical presentation of the patients.

Research Tools

In this research, JOABPEQ score was used and evaluated before the surgery and 3 months after the surgery. The JOABPEQ for assessing low back pain was designed. It was a disease-specific tool and contains 25 items tapping into five subscales: social function (four items), mental health (seven items), lumbar function (six items), walking ability (five items), and low back pain (four items). The score for each subscale range from 0 to 100, with higher scores, indicated better conditions.

In this study, we tried to find the correlation between the clinical presentation and imaging, which could give a more precise level of stenosis. We also compared the results of the MRI and CTM to diagnose the level of stenosis in multiple lumbar canal stenosis. The result of MRI and CTM was measured using the Interclass Correlation Coefficient test, to measure the compatibility of the test. Then, we measured the compatibility of the clinical presentation and imaging examination to diagnose the level of the decompression in multiple lumbar canal stenosis by using the Fisher's exact test (11).

Ethics: Kementerian Riset, Teknologi dan Pendidikan Tinggi Universitas Hasanuddin Fakultas Kedokteran RSPTN Universitas Hasanuddin RSUP Dr. Wahidin Sudirohusodo Makassar Komite Etik Penelitian Kesehatan, 12 December 2018, Protokol No: UH18120969.

RESULTS

During the 6 months period, there was 31 patient how to participate in this study. Majority of the patient were male (54.8%) and the rest were female (45.2%) (Figure 1).

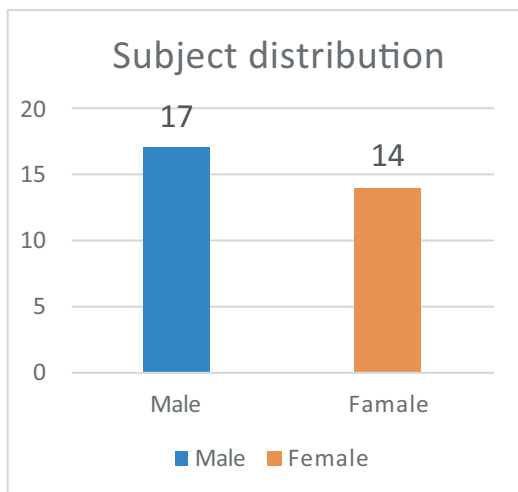


Figure 1. Subject Distribution-Gender

With the mean age between 70 years old from 31 patient, we found that there were 3 patients who had 2 levels stenosis, 8 patients who had 3 levels stenosis and there were 20 patients who had more than 3 levels of stenosis. Majority of the patients had the symptoms of stenosis for more than 1 year (Figure 2)

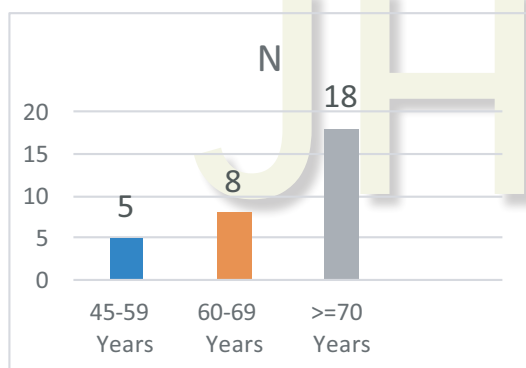


Figure 2. Subject Distribution - Age

From this study, we found that there was a different mean result for the dural sac area between the CTM and the MRI. Mean of the dural sac area from the CTM and mean from the MRI. We used the interclass correlation coefficient test to evaluate the compatibility between two radiological examinations. From this, we found that there was a no different value from the between two radiological modalities for the multiple lumbar canal stenosis (Figure 3).

In this study, we also measured the compatibility of the clinical presentation and radiological examination. We divided our patient into two categories, patient with improve outcome and patient with no improve outcome. Patient who had improve outcome, 90.9% patient who has match results of clinical outcome and radiological examination.

Besides, 75% improve outcome for patient who clinical presentation and radiological examination had unmatched result. We found higher incident of no

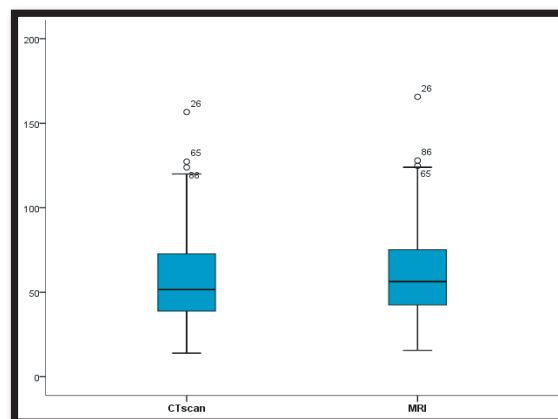


Figure 3. Subject Distribution - Graphically

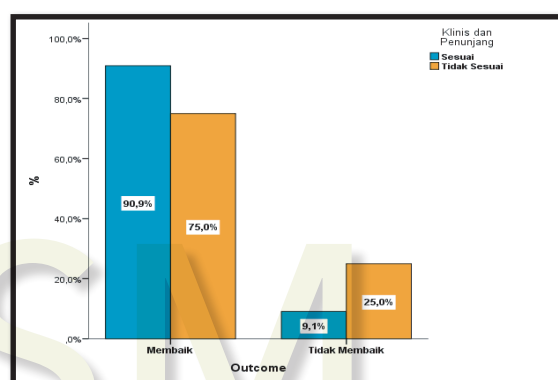


Figure 4. The compatibility of the clinical presentation and radiological examination

improve outcome in patient (25%) with unmatched clinical presentation and radiological examination. We used Fisher's exact test to measure the different between the parameters, and we found no correlation between this test test ($p>0,05$) (Figure 4).

DISCUSSION

Lumbar canal stenosis is one of the conditions that usually affected the elderly population. This condition causes decreased the ability to perform daily activities due to the difficulty to walk and disability. From this study, we found that the majority of the patient was male and most of them are more than 70 years old. During 6 months period, we managed to find 31 patient who were compatible with the inclusion and exclusion criteria. Patient who are compatible with inclusion and exclusion criteria would undergo radiological examination (MRI and CTM). We found smaller result of dural sac area from CTM compared to MRI. Our study result was different from previous study performed by Masahiro which stated that the result of CTM examination was wider than the MRI (12). We also found that patient who had a smaller canal size did not always have a worse clinical presentation. Our result of the study was similar to the

result from the previous study from Haig et al. who found radiological examination cannot differentiate patient who had a symptom and those who did not have a symptom (13).

This study revealed that more patients with improved outcome had a matched clinical presentation and radiological examination. From 11 patients who had matched clinical presentation and radiological examination, 1 subject had no improvement. We suspected that this patient had inadequate decompression surgery, incorrect level of decompression and instability. Patients who had unmatched clinical presentation and radiological examination, shown no improvement. This condition could be caused by poor medical condition prior to the surgery, long period of lumbar canal stenosis, patient with comorbid, and patient who had depression and low-walking ability before surgery (14). We also suspected that patient who had no improvement usually came with disease for more than 1 year. Radkliff et al. (15) stated that patient who had symptoms more than 1 year will have a worse outcome, operatively and nonoperatively. In this study, we compare the clinical presentation of the patient with multiple lumbar canal stenosis and imaging modalities. And by comparing this two-parameter we found that even though from the imaging modalities we could see multilevel lumbar canal stenosis, not all the level has shown symptoms for the patient, clinical presentation and patient complaint is the most important factor for determining the level of decompression in patient with multiple lumbar canal stenosis. We could treat the patient by only performing surgical decompression at the selected level, and we found a satisfactory result after 6 months of treatment. A longer follows up is needed to evaluate the long term result of the selected lumbar decompression, a bigger sample for study was also needed in the next research.

CONCLUSION

In this study, we found that the majority of the patient was male and most of them are more than 70 years old. Besides, there were 31 patient who were compatible with the inclusion and exclusion criteria. The patients who are compatible with inclusion and exclusion criteria have undergone radiological examination (MRI and CTM). After undergoing radiological examination, it was found that there was a smaller result of dural sac area from CTM compared to MRI. Hereby, the patients who had smaller canal size did not always have worse clinical presentation. Further research is expected to identify and conduct research related to the patient who was diagnosed with multiple lumbar canal stenosis by 3 orthopedic broad certified spine surgeons based on clinical presentation and CTM and MRI with different ways of observation and investigation.

DECLARATION OF CONFLICTING INTERESTS

The author declared no conflicts of interest with respect to the authorship and/or publication of this article.

REFERENCES

- Gopinathan P. Lumbar spinal canal stenosis-special features. *J Orthop* 2015; 12: 123-5.
- Ciol MA, Deyo RA, Howell E, et al. An assessment of surgery for spinal stenosis: time trends, geographic variations, complications, and reoperations. *J Am Geriatr Soc* 1996; 44: 285-90.
- Yabuki S, Fukumori N, Takegami M, et al. Prevalence of lumbar spinal stenosis, using the diagnostic support tool, and correlated factors in Japan: a population-based study. *J Orthop Sci* 2013; 18: 893-900.
- Ishimoto Y, Yoshimura N, Muraki S, et al. Prevalence of symptomatic lumbar spinal stenosis and its association with physical performance in a population-based cohort in Japan: the Wakayama Spine Study. *Osteoarthritis Cartilage* 2012; 20: 1103-8.
- Deyo RA, Gray DT, Kreuter W, et al. United States trends in lumbar fusion surgery for degenerative conditions. *Spine* 2005; 30: 1441-5.
- Deyo RA, Mirza SK, Martin BI, et al. Trends, major medical complications, and charges associated with surgery for lumbar spinal stenosis in older adults. *JAMA* 2010; 303: 1259-65.
- Samuels J, Krasnokutsky S, Abramson SB. Osteoarthritis: a tale of three tissues. *Bull NYU Hosp Jt Dis* 2008; 66: 244-50.
- Arden NK, Leyland KM. Osteoarthritis year 2013 in review: clinical. *Osteoarthritis Cartilage* 2013; 21: 1409-13.
- Nazim SM, Fawzy M, Bacj C, Ather MH. Multi-disciplinary and shared decision-making approach in the management of organ-confined prostate cancer. *Arab J Urol* 2018; 16: 367-77.
- Song KJ, Choi BW, Kim GH, Kim JR. Clinical usefulness CT-myelogram comparing with the MRI in degenerative cervical spinal disorders: is CTM still useful for primary diagnostic tool? *J Spinal Disord Tech* 2009; 22: 353-7.
- Osborn CE. *Statistical application for health information management (second edition)*. UK: Johns and Bartlett Publishers, 2006.
- Yoshida M, Shima K, Taniguchi Y, Tamaki T, Tanaka T. Hypertrophied ligamentum flavum in lumbar spinal canal stenosis. Pathogenesis and morphologic and immunohistochemical observation. *Spine* 1992; 17: 1353-60.
- Dorenbeck U, Schreyer AG, Schlaier J. Degenerative diseases of the cervical spine: comparison of a multiecho data image combination sequence with a magnetization transfer saturation pulse and cervical Myelography and CT. *Neuroradiology* 2004; 46: 306-9.
- Aalto TJ, Malmivaara A, Kovacs F, et al. Preoperative predictors for postoperative clinical outcome in lumbar spinal stenosis: systematic review. *Spine* 2006; 31: 648-63.
- Radkliff K, Rihn J, Hilibrand A, et al. Does duration of symptoms in patients with spinal stenosis and degenerative spondylolisthesis affect outcomes? Analysis of the Spine Outcomes Research Trial. *Spine* 2011. E-pub ahead of print.