







To cite this article: Ogden M, Yuksel U, Akkaya S, Bulut IU, Bakar B, Ozveren MF. Possible predictive markers to make a decision for surgical intervention in discography. Turk J Clin Lab 2019; 10: 197-208.

■ Original Article

Possible predictive markers to make a decision for surgical intervention in discography

Radyolojik görüntülerle klinik semptomları uyumlu olmayan lomber disk hernisi hastalarında diskografi uygulaması

Mustafa OGDEN^{*1} , Ulas YUKSEL² , Suleyman AKKAYA¹ , İbrahim Umut BULUT¹ , Bulent BAKAR¹ , Mehmet Faik OZVEREN¹ 

¹Kirikkale University, Faculty of Medicine, Department of Neurosurgery, Kirikkale/TURKEY

²Yildirim Beyazit University, Faculty of Medicine, Department of Neurosurgery, Ankara/TURKEY

Abstract

Aim: In this retrospective study, the diagnostic and therapeutic events of discography and disc-blockage (discoblock) were investigated in patients whose clinical symptoms could not be explained by CT and/or MR images.

Material and Methods: The study included patients applied with discography between August 2014 and October 2016. Patient data were recorded, consisting of age, gender, pre-procedure Visual Analogue Scale (VAS) score (PRE-VAS), post-procedure VAS score (POST-VAS), and pre-procedure "Japanese Orthopedic Association" (JOA) score (PRE-JOA), post-procedure JOA score (POST-JOA), long-term follow-up VAS score (FOLLOW-VAS) and JOA score (FOLLOW-JOA), level of herniated disc in the spinal column (L1-2, L2-3, L3-4, L4-5, L5-S1), size of herniated disc ("bulging", "protrusion", "extrusion") and localization of the herniated disc in the spinal canal (median or foraminal).

Results: Evaluation was made of a total of 22 patients (11 females, 11 males) aged 32 - 60 years. Discectomy after discography and/or discoblock was applied to 12 patients. The PRE-VAS scores of patients who underwent discectomy were higher than those of patients who did not undergo surgery, and the scores were lower in the postoperative period than those of the unoperated group. The long term (6 months) follow-up results indicated that patients with discectomy and those without surgery had similar levels of pain. The JOA scores of patients with discectomy were higher than those of patients without surgery.

Conclusion: At the end of this study, it was thought that discography and discoblock procedure could be an adjunctive test for decision-making in respect of surgery for patients who were not diagnosed using radiological views and clinical symptoms. Furthermore, it was considered that the VAS score applied before and after discography may identify the patients who will be applied with discectomy.

Keywords: disc herniation; discography; discoblock; visual analogue scale; Japanese Orthopedic Association score

Corresponding author*: Mustafa Ogden, Kirikkale University, Faculty of Medicine, Department of Neurosurgery, Kirikkale/TURKEY

E-posta: mustafaogden38@gmail.com

ORCID: 0000 0002 7129 0936

Received: 11.09.2018 accepted: 01.04.2019

Doi: 10.18663/tjcl.459085

Öz

Amaç: Halen bazı mekanik veya intervertebral disk kökenli bel ağrılarında radyolojik tanı yöntemleri her zaman yeterli olamayabilmektedir. Bu klinik çalışmada mevcut klinik semptomları uygulanan BT ve/veya MR tetkiki görüntüleri ile açıklanamayan hastalarda diskografi ve disk blokajı uygulamasının hastaların tanı ve tedavisine fayda sağlayıp sağlamadığı araştırıldı.

Gereç ve Yöntemler: Çalışmaya Ağustos 2014 ile Ekim 2016 tarihleri arasında diskografi uygulanan hastalar dahil edildi. Bu hastalara ameliyat öncesi ve sonrası Görsel analog skala (VAS) "Japanese Orthopedic Association" (JOA) ölçeği uygulandı. Disk blokajı sonrası ağrı şikayeti azalmayan hastalar takibe alındı ve ağrı şikayeti azalan hastalara standart mikrodisektomi girişimi uygulandı. Hastalar altı ay süre ile takip edildi ve bu süre sonunda bu hastalara tekrar başta uygulanan ölçekler uygulandı.

Bulgular: Diskografi yapıp ameliyat edilmeyen hastalarda diskografi işlemi öncesi VAS puanının fazla olmasının işlem sonrası VAS puanını arttırdığı gözlemlendi. Diskografi öncesi JOA puanları düşüğe diskografi öncesi ve sonrası VAS puanlarının yükseldiği gözlemlendi. Yine diskografi öncesi VAS puanının yüksek olduğu koşulda diskografi sonrası VAS puanının da yüksek olacağı görüldü. Bu bulgularla diskografinin ağrı üzerine etkisinin olmadığı düşünüldü. Oysa disektomi yapılan grupta ameliyat öncesi VAS ve JOA puanı düşük olduğu koşulda ameliyat sonrası JOA puanının arttığı ve erkek hastalarda uzun dönem takipte VAS puanlarının daha düşük bulunduğu saptandı. Ayrıca disektomi yapıldığı koşulda ameliyat sonrası JOA puanlarının artarken VAS puanlarının azaldığı düşünüldü. Bu bulgularla disektominin hem ağrıyı azalttığı ve hem de JOA puanını arttırdığı düşünüldü.

Sonuç: Bu çalışmanın sonunda radyolojik görüntüleri ile klinik semptomları birbiri ile uyuşmayan hastalarda ameliyatla tedavi kararını verebilmek için diskografinin ve diskoblok işleminin yardımcı bir test olabileceği düşünüldü.

Anahtar kelimeler: disk herniasyonu; diskografi; diskoblok; görsel analog skala; Japanese Orthopedic Association ölçeği

Introduction

In order to investigate the etiological factors, radiological examination methods such as computed tomography (CT), magnetic resonance (MR) and direct radiography are usually used in patients with low back pain accompanied by radiculopathy. However, these methods are not always sufficient diagnostic tools in the pathophysiology of the low back pain, which is still based on some mechanical lumbar pain or intervertebral disc herniation [1,2]. Sometimes, MR examination is not sufficient to diagnose the pathophysiology in patients with low back pain without radicular pain, or with mild clinical symptoms [3]. In such patients, "discography" which is a painful provocative surgical method can be performed to diagnose the pathophysiology of the low back pain. At the same time, it can be used to diagnose an abnormal intervertebral disc texture, and to assist in establishing the relationship between clinical symptoms and radiological findings [2,4,5,6].

Discoblock following the discography is another diagnostic method that shows whether or not this pain which is developed by the discography is reduced after anesthetic drug and / or corticosteroid drug injection into the intervertebral disc. If the patient's pain is diminished or does not continue after discoblock application, it may be considered that the back pain may be of intervertebral disc origin, and this procedure

could help the surgeon to make the decision to apply surgical treatment to the patient [7].

The aim of this retrospective study was to investigate the diagnostic and therapeutic events of discography and discoblock in patients whose clinical symptoms could not be explained by CT and / or MR images.

Materials and Methods

This retrospective study was conducted with the approval of the Local Ethics Committee. (Date: 23.08.2018, decision no: 20/01)

Patients included in the study were those applied with discography between August 2014 and October 2016.

Patient inclusion criteria:

- Suffering from lumbar pain but not radicular pain
- Pain lasting for at least 3 months
- Pain unresponsive to preventive treatment modalities
- Pain not caused by instability and / or spinal deformity
- Pain not originating from the facet and / or sacroiliac joint
- No previous surgery on the lumbar region
- No definite relationship between the radiological view and symptoms and clinical symptoms
- No overlapping of the electromyography (EMG) examination results and patient complaints / clinical symptoms / radiological events

Patient exclusion criteria:

- Radicular type of lumbar pain
- Other factors (such as tumor, infection, rheumatic disease) diagnosed in the spine or elsewhere in the body,
- Polyneuropathy / trapped neuropathy detected on EMG examination
- Detection of spinal fracture / spondylosis / spondylolisthesis
- History of any surgery or infection in the lumbar region.

All patient data were recorded by the same researcher (U.Y.),

consisting of age, gender, pre-procedure Visual Analogue Scale (VAS) score (PRE-VAS), post-procedure VAS score (POST-VAS), and pre-procedure "Japanese Orthopedic Association" (JOA) score (PRE-JOA), post-procedure JOA score (POST-JOA), long-term follow-up VAS score (FOLLOW-VAS) and JOA score (FOLLOW-JOA). Findings were also recorded of the level of the herniated disc in the spinal column (L1-2, L2-3, L3-4, L4-5, L5-S1), the size of the herniated disc ("bulging", "protrusion", "extrusion") and localization of the herniated disc in the spinal canal (median or foraminal) (Table 1).

Table 1: Descriptive table of patients who were conservatively treated (unoperated group) and patients who were applied with discectomy (N: patient number, PRE-VAS: VAS score before discography, POST-VAS: VAS score after discography, PRE-JOA: JOA scale score before discography, POST-JOA: JOA score after discography, FOLLOW-VAS: long-term follow-up VAS score, FOLLOW-JOA: long-term follow-up JOA score).

		UNOPERATED	DISCECTOMY
Demographic findings	Variable	Frequency	Frequency
Gender	Female	5 (50.0%)	6 (50.0%)
	Male	5 (50.0%)	6 (50.0%)
Level of herniated disc at the spinal colon	L1-2	-	-
	L2-3	1 (10.0%)	-
	L3-4	2 (20.0%)	2 (16.7%)
	L4-5	6 (60.0%)	10 (83.3%)
	L5-S1	1 (10.0%)	-
Size of herniated disc	Bulging	3 (30.0%)	1 (8.3%)
	Protrusion	6 (60.0%)	9 (75%)
	Extrusion	1 (10.0%)	2 (16.7%)
Localization of herniated disc in the spinal canal	Median	4 (40.0%)	5 (41.7%)
	Foraminal	6 (60.0%)	7 (58.3%)
Scales	Score		
PRE-VAS	6	3 (30.0%)	-
	7	4 (40.0%)	3 (25.0%)
	8	3 (30.0%)	5 (41.7%)
	9	-	4 (33.3%)
POST-VAS	0	-	1 (8.3%)
	1	-	3 (25.0%)
	2	-	7 (58.3%)
	3	1 (10.0%)	1 (8.3%)
	4	6 (60.0%)	-
	5	3 (30.0%)	-
FOLLOW-VAS	0	-	1 (8.3%)
	1	5 (50.0%)	7 (58.3%)
	2	3 (30.0%)	4 (33.3%)
	3	2 (20.0%)	-
PRE-JOA	0	5 (50.0%)	10 (83.3%)
	1	5 (50.0%)	2 (16.7%)
POST-JOA	1	2 (20.0%)	-
	2	8 (80.0%)	1 (8.3%)
	3	-	11 (91.7%)
FOLLOW-JOA	2	4 (40%)	12 (100.0%)
	3	6 (60%)	

Discography

VAS (PRE-VAS) and JOA (PRE-JOA) scales were applied to all patients before the entire procedure. To perform the discography procedure, a 22Gx25cm needle (Chiba, Geotek, Turkey) was inserted into intervertebral disc through the "Kambin's triangle" (Figure 1) and 2-3 ml iopromide (Ultravist-370, Bayer, Germany) was administered into the intervertebral disc (8,9) (Figure 2). Care was taken not to damage the nerve root during the procedure. Then, to apply the intervertebral disc block (discoblock), a mixture of the contrast agent and bupivacaine (Marcaïn, AstraZeneca, Turkey) was injected into the disc following discography. Corticosteroid (Depomedrol, Pfizer, Turkey) was also injected into the intervertebral disc. The scales (POST-VAS and POST-JOA) were reapplied in the first 24 hours after the discoblock operation and patients with continuing back pain after the discoblock were followed up without surgery. Standard microdiscectomy was performed to the patients with diminished or discontinued back pain. All patients were followed up for six months and at the end of this period the scales were reapplied.

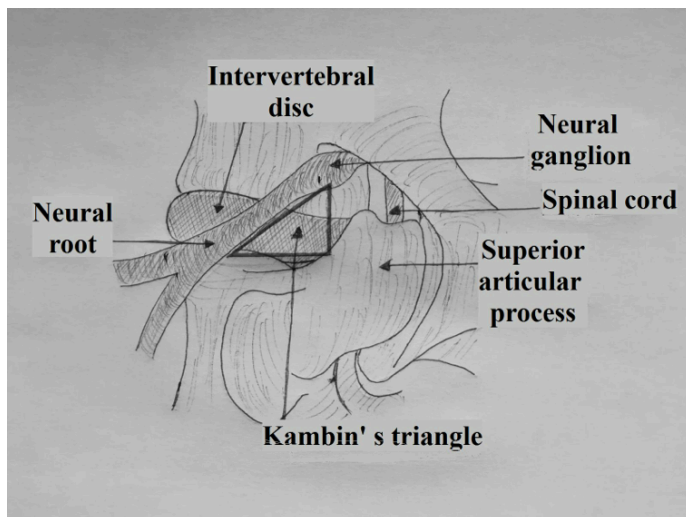
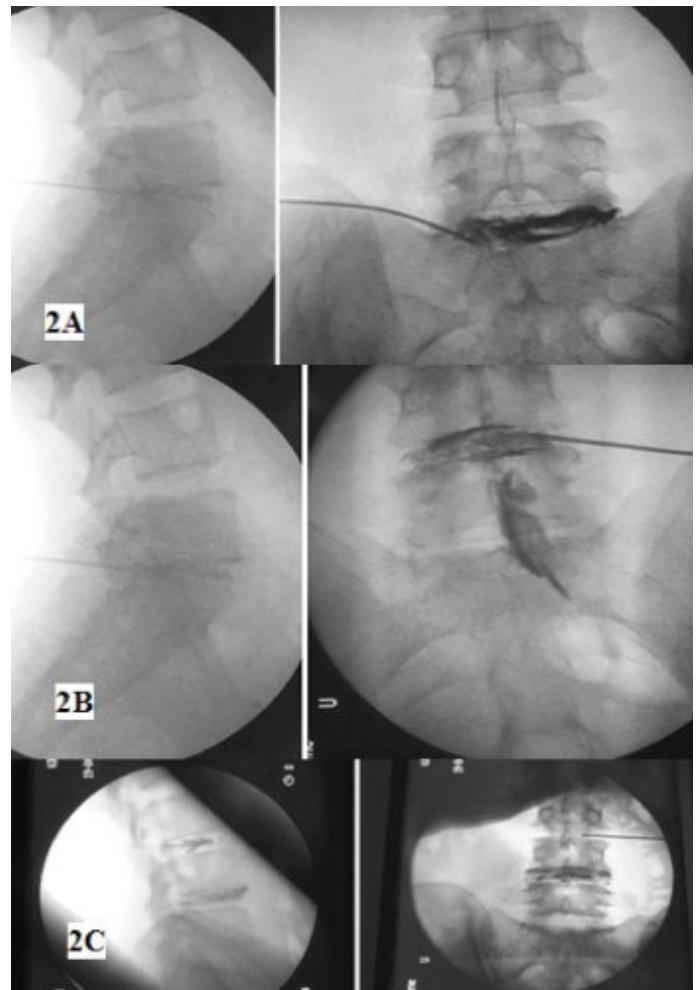


Figure 1: Schematic view of the Kambin's triangle targeted for discography and disc blockage



Scales

Before and after the discography, the following scales were applied to all the patients to determine the pain level and quality of life:

- **Visual Analogue Scale (VAS):** This scale is accepted in literature and in this study it was used to evaluate the pain on a scale between 0 and 10 points. Higher points indicated a higher level of pain (10).

- **"Japanese Orthopedic Association" (JOA) scale:** This scale is accepted in literature and is used to determine bladder and / or bowel function levels together with lower and / or upper extremity motor and sensory function levels of patients. The total score of the scale ranges between 0 and 3, and lower points indicated increased functional loss of the patient (7,11).

Discectomy

In patients with decreased pain complaints after the application of discoblock, a standard hemilaminotomy was performed at the relevant intervertebral disc level. The operations were performed with the patient positioned prone

under general anesthesia under microscope guidance by the same researcher (M.O.) and the relevant intervertebral disc was excised at the required amount.

Statistical analysis

Patient data were analyzed using the Kruskal-Wallis test. The Mann-Whitney U test was applied in the binary comparisons of the groups. The ROC-Curve test was performed to determine the predictive prognostic properties of the scales and the sensitivity specificity ratios were determined by setting "cut-off" values. Spearman's rho Correlation test was used to determine the correlation between parameters. A value of $p < 0.05$ was considered statistically significant.

Results

Evaluation was made of a total of 22 patients, comprising 11

females and 11 males, aged 32 - 60 years. During or after the procedure, no complication related to the discography (such as infection, hemorrhage, nerve root injury) was observed in any patient in short or long-term follow-up.

Patients were divided into two groups as those who underwent discectomy (DISCECTOMY group, $n=12$) and those who were followed up with conservative treatment without discectomy (UNOPERATED group, $n=10$). Median age was 46 years in the patient group who underwent discectomy. In these patients, disc herniation was found to be most prominent in the L4-5 intervertebral disc and was mostly seen as protrusion. There were significant differences between the groups in terms of the PRE-VAS ($Z = -2.588$, $p = 0.010$), POST-VAS ($Z = -4.039$, $p < 0.001$) and POST-JOA ($Z = -4.109$, $p < 0.001$) scores (Table 1, Table 2, Figure 3).

Table 2: Statistical analysis of the findings of the patients who were not treated operatively and patients who were applied with discectomy. Mann-Whitney U test, $p < 0.05$ (Z: Z score, PRE-VAS: VAS score before discography, POST-VAS: VAS score after discography, PRE-JOA: JOA scale score before discography, POST-JOA: JOA score after discography, FOLLOW-VAS: long-term follow-up VAS score, FOLLOW-JOA: long-term follow-up JOA score).

Variable	Z	p
Age (year)	-1.091	0.275
Gender (female=1, male=2)	0.000	1.000
Level of herniated disc at the spinal colon	-0.338	0.736
Size of herniated disc	-1.163	0.245
Localization of herniated disc in the spinal canal	-0.077	0.938
PRE-VAS score	-2.588	0.010
POST-VAS score	-4.039	<0.001
FOLLOW-VAS score	-1.212	0.226
PRE-JOA score	-1.633	0.102
POST-JOA score	-4.109	<0.001
FOLLOW-JOA score	-2.366	0.018

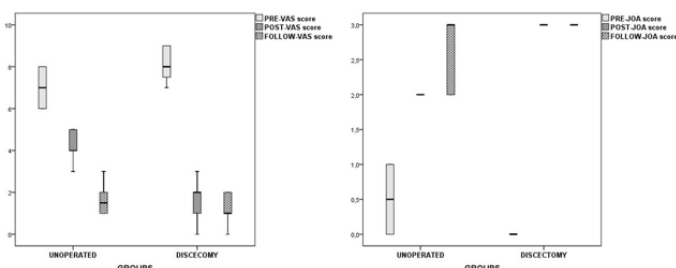


Figure 3: VAS and JOA scores of the patients before and after discography (PRE-VAS: VAS score before discography, POST-VAS: VAS score after discography, PRE-JOA: JOA scale score before discography, POST-JOA: JOA score after discography, FOLLOW-VAS: long-term follow-up VAS score, FOLLOW-JOA: long-term follow-up JOA score)

In the DISCECTOMY group, the preoperative VAS score was

8 and postoperative VAS score was 2. In these patients, JOA score was 0 preoperatively, and 3 postoperatively. In both groups, FOLLOW-VAS scores were similar in the long-term follow-up. A statistically significant difference was determined between the groups in respect of the FOLLOW-JOA scores ($Z = -2.366$, $p = 0.018$). There was no significant difference between the groups in terms of the level of the herniated disc, or size and location of the herniated disc in the spinal canal ($p > 0.05$). When the patients were divided into groups according to gender, no statistically significant difference was determined in respect of the level of the herniated disc, size of the herniated disc and location of the herniated disc in the spinal canal (Table 3, Table 4, Table 5).



Table 3: Descriptive table of patients according to gender (N: patient number, PRE-VAS: VAS score before discography, POST-VAS: VAS score after discography, PRE-JOA: JOA scale score before discography, POST-JOA: JOA score after discography, FOLLOW-VAS: long-term follow-up VAS score, FOLLOW-JOA: long-term follow-up JOA score).

		FEMALE	MALE
Demographic findings	Variable	N (%)	N (%)
Level of herniated disc at the spinal colon	L1-2	-	-
	L2-3	-	1 (9.1%)
	L3-4	3 (27.3%)	1 (9.1%)
	L4-5	7 (63.6%)	9 (81.8%)
	L5-S1	1 (9.1%)	-
Size of herniated disc	Bulging	1 (9.1%)	3 (27.3%)
	Protrusion	9 (81.8%)	6 (54.5%)
	Extrusion	1 (9.1%)	2 (18.2%)
Localization of herniated disc in the spinal canal	Median	3 (27.3%)	6 (54.5%)
	Foraminal	8 (72.7%)	5 (45.5%)
Discectomy	Yes	6 (54.5%)	5 (45.5%)
	No	5 (45.5%)	6 (54.5%)
Scales	Score		
PRE-VAS	6	1 (9.1%)	2 (18.2%)
	7	3 (27.3%)	4 (36.4%)
	8	4 (36.4%)	4 (36.4%)
	9	3 (27.3%)	1 (9.1%)
POST-VAS	0	-	1 (9.1%)
	1	1 (9.1%)	2 (18.2%)
	2	5 (45.5%)	2 (18.2%)
	3	3 (27.3%)	2 (18.2%)
	4	2 (18.2%)	3 (27.3%)
	5	-	1 (9.1%)
FOLLOW-VAS	0	-	1 (9.1%)
	1	4 (36.4%)	8 (72.7%)
	2	7 (63.6%)	-
	3	-	2 (18.2%)
PRE-JOA	0	7 (63.6%)	8 (72.7%)
	1	4 (36.4%)	3 (27.3%)
POST-JOA	1	1 (9.1%)	1 (9.1%)
	2	5 (45.5%)	4 (36.4%)
	3	5 (45.5%)	6 (54.5%)
FOLLOW-JOA	2	2 (18.2%)	2 (18.2%)
	3	9 (81.8%)	9 (81.8%)

Table 4: Descriptive table of patients according to the size of the herniated disc (N: patient number, PRE-VAS: VAS score before discography, POST-VAS: VAS score after discography, PRE-JOA: JOA scale score before discography, POST-JOA: JOA score after discography, FOLLOW-VAS: long-term follow-up VAS score, FOLLOW-JOA: long-term follow-up JOA score).

		BULGING	PROTRUSION	EXTRUSION
Demographic findings	Variable	N (%)	N (%)	N (%)
Gender	Female	1 (25.0%)	9 (60.0%)	1 (33.3%)
	Male	3 (75.0%)	6 (40.0%)	2 (66.7%)
Level of herniated disc at the spinal colon	L1-2	-	-	-
	L2-3	-	2 (6.7%)	-
	L3-4	1 (25.0%)	3 (20.0%)	-
	L4-5	3 (75.0%)	11 (73.3%)	2 (66.7%)
	L5-S1	-	-	1 (33.3%)
Localization of herniated disc in the spinal canal	Median	3 (75.0%)	6 (40.0%)	-
	Foraminal	1 (25.0%)	9 (60.0%)	3 (100.0%)
Discectomy	No	3 (75.0%)	6 (40.0%)	1 (33.3%)
	Yes	1 (25.0%)	9 (60.0%)	2 (66.7%)
Scales	Score			
PRE-VAS	6	1 (25.0%)	2 (13.3%)	-
	7	1 (25.0%)	5 (33.3%)	1 (33.3%)
	8	2 (50.0%)	5 (33.3%)	1 (33.3%)
	9	-	3 (20.0%)	1 (33.3%)
POST-VAS	0	-	1 (6.7%)	-
	1	1 (25.0%)	1 (6.7%)	1 (33.3%)
	2	-	7 (46.7%)	-
	3	1 (25.0%)	-	1 (33.3%)
	4	2 (50.0%)	4 (26.7%)	-
	5	-	2 (13.3%)	1 (33.3%)
FOLLOW-VAS	0	-	1 (6.7%)	-
	1	2 (50.0%)	8 (53.3%)	2 (66.7%)
	2	1 (25.0%)	5 (33.3%)	1 (33.3%)
	3	1 (25.0%)	1 (6.7%)	-
PRE-JOA	0	3 (75.0%)	9 (60.0%)	3 (100.0%)
	1	1 (25.0%)	6 (40.0%)	-
POST-JOA	1	-	1 (6.7%)	1 (33.3%)
	2	3 (75.0%)	6 (40.0%)	-
	3	1 (25.0%)	8 (53.3%)	2 (66.7%)
FOLLOW-JOA	2	2 (50.0%)	1 (6.7%)	1 (33.3%)
	3	2 (50.0%)	14 (93.3%)	2 (66.7%)



Table 5: Descriptive table of patients according to the localization of the herniated disc in the spinal canal (N: patient number, PRE-VAS: VAS score before discography, POST-VAS: VAS score after discography, PRE-JOA: JOA scale score before discography, POST-JOA: JOA score after discography, FOLLOW-VAS: long-term follow-up VAS score, FOLLOW-JOA: long-term follow-up JOA score).

		MEDIAL	FORAMINAL
Demographic findings	Variable	N (%)	N (%)
Gender	Female	3 (33.3%)	8 (61.5%)
	Male	6 (66.7%)	5 (38.5%)
Level of herniated disc at the spinal colon	L1-2	-	-
	L2-3	1 (11.1%)	-
	L3-4	2 (22.2%)	2 (15.4%)
	L4-5	6 (66.7%)	10 (76.9%)
	L5-S1	-	1 (7.7%)
Size of herniated disc	Bulging	3 (33.3%)	1 (7.7%)
	Protrusion	6 (66.7%)	9 (69.2%)
	Extrusion	-	3 (23.1%)
Discectomy	No	4 (44.4%)	6 (46.2%)
	Yes	5 (55.6%)	7 (53.8%)
Scales	Score		
PRE-VAS	6	2 (22.2%)	1 (7.7%)
	7	1 (11.1%)	6 (46.2%)
	8	5 (55.6%)	3 (23.1%)
	9	1 (11.1%)	3 (23.1%)
POST-VAS	0	-	1 (7.7%)
	1	1 (11.1%)	2 (15.4%)
	2	4 (44.4%)	3 (23.1%)
	3	1 (11.1%)	1 (7.7%)
	4	2 (22.2%)	4 (30.8%)
	5	1 (11.1%)	2 (15.4%)
FOLLOW-VAS	0	-	1 (7.7%)
	1	5 (55.6%)	7 (53.8%)
	2	3 (33.3%)	4 (30.8%)
	3	1 (11.1%)	1 (7.7%)
PRE-JOA	0	7 (77.8%)	8 (61.5%)
	1	2 (22.2%)	5 (38.5%)
POST-JOA	1	1 (11.1%)	1 (7.7%)
	2	3 (33.3%)	6 (46.2%)
	3	5 (55.6%)	6 (46.2%)
FOLLOW-JOA	2	2 (22.2%)	2 (15.4%)
	3	7 (77.8%)	11 (84.6%)

Correlation analysis findings

In the UNOPERATED group, a positive correlation was found between POST-VAS scores and size of the herniated disc ($r = 0.659, p = 0.038$) and between POST-VAS and PRE-VAS scores ($r = 0.643, p = 0.045$). A negative correlation was found between the PRE-JOA and PRE-VAS scores ($r = -0.775, p = 0.009$), between PRE-JOA and POST-VAS scores ($r = -0.677, p = 0.031$), between POST-VAS and POST-JOA scores ($r = -0.697, p = 0.025$) and between FOLLOW-JOA and FOLLOW-VAS scores ($r = -0.849, p = 0.002$). In the DISCECTOMY group, there was a negative correlation between gender and FOLLOW-VAS score ($r = -0.716, p = 0.009$), between PRE-JOA and PRE-VAS scores ($r = -0.621, p = 0.031$) and between PRE-JOA and POST-JOA scores ($r = -0.674, p = 0.016$).

In female patients, a positive correlation was found between the level of the herniated disc and size of the herniated disc ($r=0.712, p=0.014$), between discectomy and POST-JOA score ($r = 0.830, p = 0.002$) and between the PRE-VAS and FOLLOW-VAS scores ($r=0.655, p=0.029$). In these patients, a negative correlation was found between the POST-VAS scores and discectomy ($r=-0.920, p<0.001$), between POST-VAS and POST-JOA scores ($r = -0.838, p = 0.001$), between PRE-JOA and PRE-VAS scores ($r = -0.873, p <0.001$) and between PRE-JOA and FOLLOW-VAS scores ($r = -0.607, p = 0.048$). The location of the herniated disc in the spinal canal (midline, foraminal) did not affect the results of the study. In male patients, a positive correlation was found between the discectomy and PRE-VAS scores ($r = 0.820, p = 0.002$), between discectomy and POST-JOA scores ($r = 0.971, p <0.001$), between POST-VAS and FOLLOW-VAS scores ($r = 0.619, p = 0.042$), between POST-JOA scores and the level of the herniated disc ($r = 0.643, P = 0.033$) and between POST-JOA and PRE-VAS scores ($r = 0.764, p = 0.005$).

If the herniated disc was located in the midline region in the spinal canal, POST-JOA scores were positively correlated with the placement level of the herniated disc ($r = 0.846, p = 0.004$), PRE-VAS scores ($r = 0.739, p = 0.023$), discectomy ($r = 0.968, p <0.001$), and negatively correlated with the POST-VAS scores ($r = -0.938, p <0.001$). POST-VAS scores were negatively correlated with the level of the herniated disc ($r = -0.873, p = 0.002$) and discectomy ($r = -0.909, p = 0.001$). If the herniated disc was located in the foraminal region in the spinal canal, a positive correlation was found between POST-JOA scores and

discectomy ($r = 0.849, p <0.001$) whereas a negative correlation was found between POST-JOA scores and the level of the herniated disc ($r = -0.622, p = 0.023$) and between POST-JOA and POST-VAS scores ($r = -0.833, p <0.001$). In these patients, a negative correlation was found between POST-VAS and discectomy ($r=-0.886, p<0.001$), between PRE-VAS and PRE-JOA scores ($r = -0.720, p = 0.006$), between the FOLLOW-VAS and FOLLOW-JOA scores ($r = -0.598, p = 0.031$).

ROC-Curve analysis findings

For the consideration of performing discectomy, the PRE-VAS scores obtained before discography were determined to be 75% sensitive and 70% specific if the PRE-VAS score was 7.5 and above (area = 0.813, $p = 0.013$, cut-off value = 7.5).

For the consideration of conservative treatment, the POST-VAS scores of the patients obtained immediately after discography were determined as 91.7% specific and 100% sensitive if the POST-VAS score was 2.5 or less (area = 0.996, $p <0.001$, cut-off value = 2.5) (Table 6, Figure 4). PRE-JOA scores were not found to be sensitive or specific in the consideration of performing discectomy or conservative treatment modalities (area = 0.333, $p = 0.187$).

Table 6: Table of sensitivity and specificity values of PRE-VAS and POST-VAS scales. ROC-Curve test, $p <0.05$ (PRE-VAS: VAS score before discography, POST-VAS: VAS score after discography)

Variable	Area	p	Cut-off value
PRE-VAS score	0.813	0.013	2.5
POST-VAS score	0.996	<0.001	2.5
PRE-JOA score	0.333	0.187	-

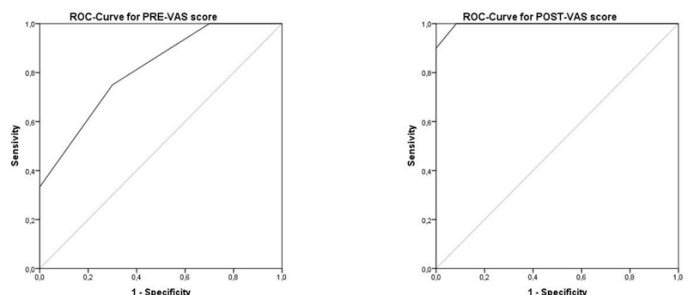


Figure 4: ROC-Curve graphs showing the sensitivity and specificity of the VAS scale before and after discography (PRE-VAS: VAS score before discography, POST-VAS: VAS score after discography)

Discussion

Pressure of a herniated disc on neural tissue, leakage of lactic acid/cytokines/chemokines to the neural tissue surfaces from



the herniated disc, formation of granulated tissues after disc herniation, and spinal instability have been reported as the physiopathological causes of intervertebral disc-based pain [12,13,14]. Radiological examination such as CT and MR are frequently used in the evaluation of lumbar pain. However, the diagnostic success of these tests depends on the matching of clinical symptoms and anatomic impairments while providing almost exact information about the anatomic deterioration such as disc degenerations, nerve root and dura pressures [2]. Sometimes indeterminate dermatomal features of low back pain make it difficult to interpret these tests and this is even more difficult if degenerations occur in the intervertebral disc region [3]. Discography, which is described as an alternative radiological examination to overcome these difficulties, is based on provoking the existing back pain by injecting a radiopaque drug into the intervertebral disc [4,5,12,15,16,17].

In literature, the benefits of discography have been described as follows: 1) possible association of suspicious CT and MR images with herniated disc in patients with discogenic pain, 2) Postoperative disc-scar relationship and separation, 3) Imaging of fusion in the intervertebral space, 4) Indication that the pain may be discogenic if this pain is reduced / recovered after the injection of the anesthetic agent into the disc, 5) Determination of symptomatic level in multi-level disc hernia, and 6) Display of disc degeneration and evaluation and association of mechanical back pain [2,3,5,17,18,19]. Although it has been emphasized in many studies that discography provides better results, especially in discogenic pain caused by degenerated disc and osteochondroses [20,21,22]. It has been suggested in some studies that it should not be used as a routine procedure due to disadvantages such as the invasiveness of the method, exposure to radiation, and the possibility of nerve root damage during the procedure [23].

The results of the current study demonstrated that gender, level of the herniated disc, size of the herniated disc and location of the herniated disc in the spinal canal (midline or foraminal region) had no modifying effect on VAS or JOA scores in all patients. However, the preoperative VAS scores were found to be higher in patients with discectomy than in patients without discectomy. After discectomy, these scores in patient with discectomy were observed to be lower than those of the unoperated patients and the JOA scores were also

found to be significantly increased in these patients compared to the unoperated patients. The long-term (6 months) follow-up results indicated that patients with discectomy and those without surgery had similar levels of back pain. However, patients with discectomy were found to have higher JOA scores than patients without discectomy.

In female patients, it was seen that the size of the herniated disc in the spinal canal was much greater in the lower lumbar region than in the upper lumbar region, but this finding was not observed in male patients. In female patients, the VAS scores were found to be high in long-term follow-up, if they had been high before discography. It was also considered that the JOA scores increased in these patients when VAS scores decreased after discography. However, in these patients the VAS scores were observed to decrease and JOA scores increased after discectomy.

In male patients applied with discectomy, the preoperative VAS score values were found to be high but the JOA score values were low. In the postoperative period, JOA scores were found to be high and the VAS scores were low. The long-term follow-up revealed that the JOA score increased and the VAS score decreased in these patients.

In the UNOPERATED group, it was observed that herniated disc size extending into the spinal canal and a higher VAS score before discography increased the VAS score after discography. VAS scores before and after the procedure were found to be high if the JOA score was low before the procedure. It was also predicted that the VAS score after the procedure could be high if the VAS score before the procedure was high. These findings suggested that discography has no effect on pain in this group. It was also observed in this group that as the VAS score increased, the JOA score decreased in long-term follow-up.

However, in the DISCECTOMY group, when the preoperative VAS score was found to be low, the preoperative JOA score was high. When the preoperative JOA score was found to be low, the postoperative JOA score increased, and the long term follow-up VAS scores were found to be low in male patients. In addition, when the discectomy was performed in patients with midline or foraminal disc herniation, it was observed that after surgery, the VAS scores decreased while the JOA scores increased. With these findings, discectomy was considered to both reduce pain and increase the JOA score.

When a cutoff value of ≥ 7.5 was accepted for the VAS score before discography, sensitivity was determined to be 75% and specificity 70% in the identification of patients to be applied with discectomy. Thus a VAS score >7 points before discography could predict that the patient could be a candidate for discectomy. When the cutoff value of ≤ 2.5 was accepted for the VAS score applied after discography, sensitivity was 91.7% and specificity 100% in the identification of patients to be applied discectomy. If the VAS score falls below 2.5 points after discography, it was thought that this pain could be due to disc herniation and that discectomy would probably be necessary for this disc space. Therefore, it can be recommended that VAS is definitely applied before and after discography in order to differentiate the pain originating from disc herniation and to decide whether to perform discectomy. It was concluded that this scale could be a diagnostic marker in these patients. However, it was determined that the scores of the JOA scales applied before discography were not sensitive and specific in the differentiation of discectomy decision-making. This finding suggested that JOA scale applied before discography may fail to identify patients who could be applied with discectomy.

Conclusion

In conclusion, the results of this study suggested that discography and discoblock procedure could be an adjunctive test in order to make a decision for surgery in patients who were not diagnosed using radiological views and clinical symptoms. Furthermore, it was observed that if the VAS score applied before discography is ≥ 7.5 points, this scale may identify patients to be applied with discectomy. In addition, it was concluded that lumbar pain may be due to disc herniation and that discectomy is probably necessary for this disc space if the VAS score falls below 2.5 points after discography.

Declaration of conflict of interest

The authors received no financial support for the research and/or authorship of this article. There is no conflict of interest.

References

1. Frymoyer JW. Back pain and sciatica. *N Engl J Med* 1988; 318: 291-300.
2. Smith BM, Hurwitz EL, Solsberg D, Rubinstein D, Corenman DS, Dwyer AP, Kleiner J. Interobserver reliability of detecting lumbar intervertebral disc high-intensity zone on magnetic resonance imaging and association of high-intensity zone with pain and anular disruption. *Spine (Phila Pa 1976)* 1998; 23: 2074-80.
3. Jarvik JG, Deyo RA. Imaging of lumbar intervertebral disk degeneration and aging, excluding disk herniations. *Radiol Clin North Am* 2000; 38: 1255-66
4. Carragee EJ, Chen Y, Tanner CM, Truong T, Lau E, Brito JL. Provocative discography in patients after limited lumbar discectomy: A controlled, randomized study of pain response in symptomatic and asymptomatic subjects. *Spine (Phila Pa 1976)* 2000; 25: 306530-71.
5. Carragee EJ, Paragioudakis SJ, Khurana S. 2000 Volvo Award winner in clinical studies: Lumbar high-intensity zone and discography in subjects without low back problems. *Spine (Phila Pa 1976)* 2000; 25: 2987-92.
6. Jinkins JR, Rauch RA, Gee GT, Bazan C 3rd, Xiong L, Kashanian FK, Hanna EP. Lumbosacral spine: early and delayed MR imaging after administration of an expanded dose of gadopentetate dimeglumine in healthy, asymptomatic subjects. *Radiology* 1995; 197: 247-51.
7. Ohtori S, Kinoshita T, Yamashita M et al. Results of surgery for discogenic low back pain: a randomized study using discography versus discoblock for diagnosis. *Spine (Phila Pa 1976)* 2009; 34: 1345-48.
8. Kambin P, Savitz MH. Arthroscopic microdiscectomy: an alternative to open disc surgery. *Mt Sinai J Med* 2000; 67: 283-87.
9. Kambin P. Arthroscopic microdiscectomy. *Arthroscopy* 1992; 8: 287-95.
10. Boonstra AM, Schiphorst Preuper HR, Reneman MF, Posthumus JB, Stewart RE. Reliability and validity of the visual analogue scale for disability in patients with chronic musculoskeletal pain. *Int J Rehabil Res* 2008; 31: 165-69.
11. Vitzthum HE, Dalitz K. Analysis of five specific scores for cervical spondylogenic myelopathy. *Eur Spine J* 2007; 16: 2096-103
12. Tehranzadeh J. Discography 2000. *Radiol Clin North Am* 1998; 36: 463-95.
13. Cohen SP, Larkin TM, Barna SA, Palmer WE, Hecht AC, Stojanovic MP. Lumbar discography: a comprehensive review of outcome studies, diagnostic accuracy, and principles. *Reg Anesth Pain Med* 2005; 30: 163-83.
14. Schliessbach J, Siegenthaler A, Heini P, Bogduk N, Curatolo M. Blockade of the sinuvertebral nerve for the diagnosis of lumbar diskogenic pain: an exploratory study. *Anesth Analg* 2010; 111: 204-206.



15. Peng B, Fu X, Pang X, Li D, Liu W, Gao C, Yang H. Prospective clinical study on natural history of discogenic low back pain at 4 years of follow-up. *Pain Physician* 2012; 15: 525-32.
16. Aprill C, Bogduk N. High-intensity zone: a diagnostic sign of painful lumbar disc on magnetic resonance imaging. *Br J Radiol* 1992; 65: 361-69.
17. Fukui S, Nitta K, Iwashita N, Tomie H, Nosaka S, Rohof O. Intradiscal pulsed radiofrequency for chronic lumbar discogenic low back pain: a one year prospective outcome study using discoblock for diagnosis. *Pain Physician* 2013; 16: 435-42.
18. Weishaupt D, Zanetti M, Hodler J, Boos N. MR imaging of the lumbar spine: prevalence of intervertebral disk extrusion and sequestration, nerve root compression, end plate abnormalities, and osteoarthritis of the facet joints in asymptomatic volunteers. *Radiology* 1998; 209: 661-66.
19. Tonosu J, Inanami H, Oka H et al. Diagnosing Discogenic Low Back Pain Associated with Degenerative Disc Disease Using a Medical Interview. *PLoS One* 2016; 11: 0166031.
20. Alamin TF, Kim MJ, Agarwal V. Provocative lumbar discography versus functional anesthetic discography: a comparison of the results of two different diagnostic techniques in 52 patients with chronic low back pain. *Spine J* 2011; 11: 756-65.
21. Carragee EJ, Alamin TF, Miller JL, Carragee JM. Discographic, MRI and psychosocial determinants of low back pain disability and remission: a prospective study in subjects with benign persistent back pain. *Spine J* 2005; 5: 24-35.
22. Carragee EJ, Chen Y, Tanner CM, Hayward C, Rossi M, Hagle C. Can discography cause long-term back symptoms in previously asymptomatic subjects? *Spine (Phila Pa 1976)* 2000; 25: 1803-08.
23. Putzier M, Streitparth F, Hartwig T, Perka CF, Hoff EK, Strube P. Can discoblock replace discography for identifying painful degenerated discs? *Eur J Radiol* 2013; 82: 1463-70.