

# Laparoscopic management of cornual pregnancy: A case report

## Kornual gebelikte laparoskopik tedavi: Olgu sunumu

Görker Sel<sup>1</sup>, Dilara Özaydın<sup>1</sup>, Avni Ozan Tekin<sup>1</sup>, Müge Harma<sup>1</sup>, Mehmet İbrahim Harma<sup>1</sup>

<sup>1</sup> Department of Obstetrics and Gynecology,  
Zonguldak Bülent Ecevit University Faculty of  
Medicine Education and Research Hospital,  
Zonguldak, Turkey

ORCID ID of the author(s)

GS: 0000-0001-8653-5687  
DÖ: 0000-0003-2973-6268  
AOT: 0000-0003-0496-1055  
MH: 0000-0002-4327-674X  
MİH: 0000-0002-9734-5253

### Abstract

The incidence of cornual or interstitial pregnancy is approximately 2% of all pregnancies. Interstitial pregnancy is one of the rare form of ectopic pregnancies, with 1-6% of all ectopic pregnancies. In our case report, we present successful laparoscopic resection of a cornual pregnancy with positive fetal cardiac activity and laparoscopic suturing of cornu uteri. A 26-year-old pregnant; gravida 2, para 0, abortus 1; was admitted with a complaint of left lower quadrant abdominal pain. An ultrasound examination was performed. The ultrasound examination revealed a 4-cm ectopic gestational sac with positive cardiac activity in the left adnexa. Laparoscopy was planned. A left uterine approximately 3x4 cm cornual pregnancy was observed, under direct visualization, one 5-mm coagulating dissector was used to perform the resection and seal of the cornu uteri. After the sealing, two times laparoscopic suturing was applied. Detecting interstitial pregnancy is more difficult than revealing other ectopic pregnancy types. Severe hemorrhage could occur during the resection of the cornu uteri. Therefore, a laparoscopic approach should only be attempted if the surgeon is well skilled in laparoscopic technique, and has the capability to convert the operation quickly to a laparotomy.

**Keywords:** Laparoscopy, Ectopic pregnancy, Cornual pregnancy

### Öz

Kornual veya interstisyel gebelik insidansı tüm gebeliklerin yaklaşık %2'sidir. İnterstisyel gebelik, tüm ektopik gebeliklerin %1-6'sı ile nadir görülen ektopik gebeliklerden biridir. Olgumuzda, pozitif fetal kardiyak aktivite gözlenen kornual ektopik olgusunun başarılı bir şekilde laparoskopik rezeksiyonu ve kornu uterinin laparoskopik suture edildiği olguyu sunuyoruz. 26 yaşında hamile; gravida 2, para 0, abort 1; sol alt kadranda ağrı şikayeti ile başvurdu. Ultrason muayenesi yapıldı. Ultrason muayenesinde sol adnekte pozitif kardiyak aktivite gösteren 4 cm'lik bir ektopik gebelik kesesi saptandı. Laparoskopi planlandı. Solda uterin kornuda, yaklaşık 3x4 cm kornual gebelik görüldü, 5 mm'lik bir koter disektör, cornu uteri'nin rezeksiyonu ve mühürlenmesi için kullanıldı. Sonrasında, iki kez laparoskopik dikiş atıldı. İnterstisyel gebeliği tespit etmek, diğer ektopik gebelik tiplerini ortaya koymaktan daha zordur. Cornu uteri'nin rezeksiyonu sırasında ciddi kanamalar görülebilir. Bu nedenle, laparoskopik bir yaklaşım, ancak cerrah laparoskopik teknikle uzman ve operasyonu hızlı bir şekilde laparotomiye dönüştürme yeteneğine sahipse denemelidir.

**Anahtar kelimeler:** Laparoskopi, Ektopik gebelik, Kornual gebelik

## Introduction

The interstitial portion of the fallopian tube is the proximal portion that is within the muscular wall of the uterus. It is 0.7 mm wide and 1 to 2-cm long [1]. The incidence of cornual or interstitial pregnancy is approximately 2% of all pregnancies. Interstitial pregnancy is one of the rare form of ectopic pregnancies, with 1-6% of all ectopic pregnancies [2]. It tends to rupture at a more advanced gestation compared to tubal ectopic pregnancy. It is not easy to ascertain exact localization of the cornual pregnancy accurately with the help of ultrasound. Since majority of the ectopic pregnancies have tendency to occur in ampullar region, generally preoperatively cornual pregnancies are misdiagnosed as ampullar ectopic pregnancies [3].

Current surgical procedure for tubal ampullar ectopic pregnancies are generally laparoscopy and then laparotomy [4]. However in case of cornual pregnancy, surgeons have reluctance to use laparoscopy, because of high risk of bleeding and difficulty of laparoscopic suturing.

In our case report, we present successful laparoscopic resection of a cornual pregnancy with positive fetal cardiac activity and laparoscopic suturing of cornu uteri.

Corresponding author / Sorumlu yazar:  
Görker Sel  
Address / Adres: Zonguldak Bülent Ecevit  
Universitesi, Tıp Fakültesi, Kadın Hastalıkları ve  
Doğum Anabilim Dalı, Zonguldak, Türkiye  
e-Mail: gorkersel@gmail.com

Informed Consent: The authors stated that the  
written consent was obtained from the patient  
presented in the study.

Hasta Onamı: Yazar çalışmada sunulan hastadan  
yazılı onam alındığını ifade etmiştir.

Conflict of Interest: No conflict of interest was  
declared by the authors.

Çıkar Çatışması: Yazarlar çıkar çatışması  
bildirmemişlerdir.

Financial Disclosure: The authors declared that  
this study has received no financial support.  
Finansal Destek: Yazarlar bu çalışma için finansal  
destek almadıklarını beyan etmişlerdir.

Published: 6/15/2019  
Yayın Tarihi: 15.06.2019

Copyright © 2019 The Author(s)  
Published by JOSAM

This is an open access article distributed under the terms of the Creative  
Commons Attribution-Non Commercial-NoDerivatives License 4.0 (CC  
BY-NC-ND 4.0) where it is permissible to download, share, remix,  
transform, and buildup the work provided it is properly cited. The work  
cannot be used commercially without permission from the journal.



## Case presentation

A 26-year-old pregnant; gravida 2, para 0, abortus 1; was admitted to our clinic with a complaint of left lower quadrant abdominal pain. An ultrasound examination was performed. The ultrasound examination revealed a 4-cm ectopic gestational sac, crown rump length 21-mm, with positive cardiac activity in the left adnexa. Regarding the findings, emergent laparoscopy was planned. The first, 10-mm trocar port for the laparoscope was entered by umbilicus. A left uterine cornual approximately 3x4 cm bulging ectopic sac was observed. The second and third 5-mm ancillary trocar ports were entered in the right and left lower quadrants. Cornual pregnancy was aspirated and approximately 3-cm fetus was attached to the aspirator, as shown in figure 1. Under direct visualization, one 5-mm coagulating dissector (Ligasure, Covidien ®) was used to perform the resection and seal of the cornu uteri. After the sealing, two times intracorporeal laparoscopic suturing with 1-0 Vicryl (Ethicon, Cincinnati, OH, USA) was applied and bleeding was completely taken under control, as shown in figure 2. The duration of the operation was approximately one hour.

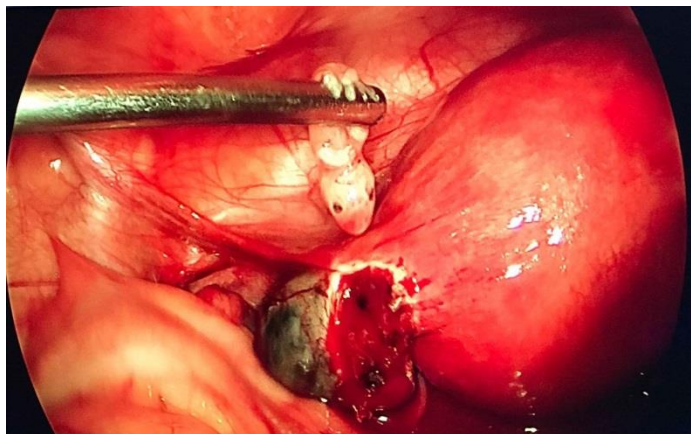


Figure 1: Ruptured left cornual pregnancy, the fetus attached to the aspirator

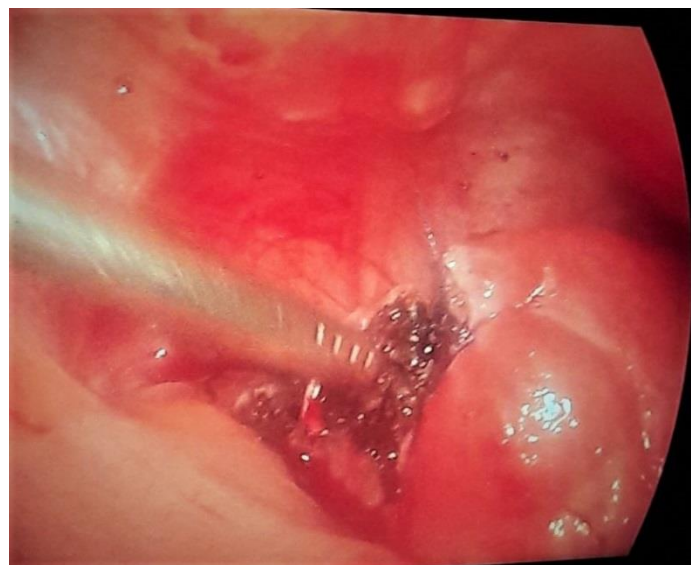

Figure 2: The sutured left cornu uteri

Estimated blood loss was 100 ml and the patient recovered without complication. The day after the operation, she was discharged uneventfully. Serum  $\beta$ -human chorionic gonadotrophin concentration decreased from 84,790 mIU/ml at the time of the operation to <1.5 mIU/ml in 4 weeks. The written consent was obtained from the patient presented in the study.

## Discussion

Detecting interstitial pregnancy is more difficult than revealing other ectopic pregnancy types, since the gestational sac, located in the myometrium, is isolated from other pelvic organs, so it presents itself as grave hemorrhage leading to hypovolemic shock resulting from rupture of uterus rather than localized pelvic pain as seen in other types [5,6].

With the help of ultrasound, incomplete or asymmetrical myometrium surrounding eccentric located gestational sac sign is a unique diagnostic finding for interstitial pregnancy [7]. However this is not always easy.

Although cornual pregnancies have traditionally been treated with hysterectomy or cornual resection, several more conservative techniques have recently become available [8]. In the case of an early and asymptomatic ectopic gestation, methotrexate has been shown to be an effective treatment by Sel et al [5] previously. A ruptured interstitial pregnancy is a medical emergency that requires an immediate surgical intervention either by laparoscopy or laparotomy to stop the bleeding and remove the pregnancy [9].

In Selma et al's [10] series, there was a tendency to perform laparoscopic wedge resection instead of cornuostomy because of the perception that extirpative surgery would result in fewer persistent cornual pregnancies. We also performed wedge resection and laparoscopic suturing in our case, to make it certain that no bleeding would occur and in order to prevent rupture of future pregnancies, since uterine rupture in future pregnancy following salpingectomy for interstitial pregnancy has been reported in the literature [11].

Laparoscopy is the gold standard for treatment in ectopic pregnancy, laparotomy is considered to be outdated. Even in women with significant hemoperitoneum, laparoscopic surgery can be safely conducted by experienced laparoscopic surgeons if hemodynamic stability is achieved by perioperative management [10].

However, severe hemorrhage could occur during the resection of the cornu uteri. Therefore, a laparoscopic approach should only be attempted if the surgeon is well skilled in laparoscopic technique, and has the capability to convert the operation quickly to a laparotomy. When these conditions are met, laparoscopy provides several advantages over laparotomy: fewer post-operative hospital days, faster return to normal activity, and decreased health care costs [8].

Cornual ectopic pregnancy is an uncommon case to be faced in obstetrics practice, albeit comprises grave risk to the pregnant women when it happens. Therefore, it is prudent to consider this diagnosis in case of an atypically localized gestational sac observed with ultrasound.

In recent years, laparoscopic management of any kind of surgery, of course with the exception of cesarean of intrauterine viable fetus, is possible. As surgeons get experienced, laparoscopy would be conventional surgery and laparotomy would be a historical practice.

## References

1. Soriano D, Vicus D, Mashiach R, Schiff E, Seidman D, Goldenberg M. Laparoscopic treatment of cornual pregnancy: a series of 20 consecutive cases. *Fertility and sterility*. 2008 Sep 1;90(3):839-43.

2. Jermy K, Thomas J, Doo A, Bourne T. The conservative management of interstitial pregnancy. *BJOG: An International Journal of Obstetrics & Gynaecology*. 2004 Nov 1;111(11):1283-8.
3. Chan LY, Fok WY, Yuen PM. Pitfalls in diagnosis of interstitial pregnancy. *Acta obstetrica et gynecologica Scandinavica*. 2003 Sep;82(9):867-70.
4. Saraswathi K, Prasad MS, Kumari BK. Tubal ectopic pregnancy: comparative study of laparoscopy vs laparotomy. *JOURNAL OF EVOLUTION OF MEDICAL AND DENTAL SCIENCES-JEMDS*. 2015 Nov 5;4(89):15447-9.
5. Sel G, Harma Mİ, Harma M, Barut A, Arıkan İİ. Case report of a Successful Treatment of Interstitial Pregnancy with Systemic Methotrexate. *Abant Med J*. 2017;6(3):120-2.
6. Goran A. Spontaneous uterine rupture. In: *Acute Abdomen During Pregnancy*. Springer, Cham, 2014. p. 495-527.
7. Ong C, Su LL, Chia D, Choolani M, Biswas A. Sonographic diagnosis and successful medical management of an intramural ectopic pregnancy. *Journal of Clinical Ultrasound*. 2010 Jul;38(6):320-4.
8. Grobman WA, Milad MP. Conservative laparoscopic management of a large cornual ectopic pregnancy. *Human reproduction (Oxford, England)*. 1998 Jul 1;13(7):2002-4.
9. Moawad NS, Mahajan ST, Moniz MH, Taylor SE, Hurd WW. Current diagnosis and treatment of interstitial pregnancy. *American journal of obstetrics and gynecology*. 2010 Jan 1;202(1):15-29.
10. Ng S, Hamontri S, Chua I, Chern B, Siow A. Laparoscopic management of 53 cases of cornual ectopic pregnancy. *Fertility and sterility*. 2009 Aug 1;92(2):448-52.
11. Weissman A, Fishman A. Uterine rupture after conservative surgery for interstitial pregnancy. *Eur J Obstet Gynecol Reprod Biol* 1992;13(44):237-9.

The National Library of Medicine (NLM) citation style guide is used in this paper.

Suggested citation: Patrias K. Citing medicine: the NLM style guide for authors, editors, and publishers [Internet]. 2nd ed. Wendling DL, technical editor. Bethesda (MD): National Library of Medicine (US); 2007-[updated 2015 Oct 2; cited Year Month Day]. Available from: <http://www.nlm.nih.gov/citingmedicine>