

## Acute retroperitoneal hematoma mimicking intraperitoneal hemorrhage caused by renal angiomyolipomas associated with tuberous sclerosis

Tuberosklerozla ilişkili renal anjiomiyolipomun sebep olduğu intraperitoneal kanamayı taklit eden akut retroperitoneal hematom

İlker Seçkiner<sup>1</sup>, Aykut Altunkaya<sup>2</sup>, Ömer Bayrak<sup>1</sup>, Bülent Akduman<sup>3</sup>, Aydın Mungan<sup>3</sup>

<sup>1</sup>Department of Urology, Faculty of Medicine, University of Gaziantep, Gaziantep

<sup>2</sup>Department of Thorax Surgery, Bağcılar Education and Research Hospital, İstanbul

<sup>3</sup>Department of Urology, Faculty of Medicine, Zonguldak Karaelmas University, Zonguldak

### Abstract

Tuberous sclerosis complex (TSC) is known as a neurological and dermatological disorder, but its renal manifestations are frequent and may cause death. We report a patient with TSC who showed bilateral multiple renal angiomyolipomas. Spontaneous retroperitoneal hematoma caused by renal angiomyolipoma that mimicking intraperitoneal hemorrhage was diagnosed in her clinical follow-up. We performed right total nephrectomy for controlling hemorrhage, but she died due to poor respiratory function, in fifteenth day postoperatively.

**Keywords:** Angiomyolipoma; hemorrhage; tuberous sclerosis

### Özet

Tuberoskleroz kompleksi (TSC) nörolojik ve dermatolojik bir hastalık olarak bilinmekteyse de; böbrekte meydana getirdiği değişiklikler nedeniyle sıklıkla karşılaşılabilmekte ve ölüme neden olabilmektedir. Biz bilateral multipl renal anjiomiyolipomu olan tuberosklerozlu bir hastayı sunmak istedik. Renal anjiomiyolipomu olan hastada spontan retroperitoneal hematom meydana geldi ve klinik takiplerinde intraperitoneal kanamayı taklit etmesiyle tanı kondu. Hemorajiyi kontrol etmek için sağ total nefrektomi yapıldı. Ancak hasta post operatif 15. gün zayıf solunum fonksiyonları nedeniyle kaybedildi.

**Anahtar kelimeler:** Anjiomiyolipom; hemoraji; tuberoskleroz

### Introduction

Tuberous sclerosis complex (TSC) is an autosomal dominant disorder that affects approximately 1/6000 individuals. This disease is characterized by the widespread development of benign tumors termed hamartomas, frequently leading to skin rashes, seizures and mental retardation (1). The commonest manifestation in the kidney is angiomyolipoma. The angiomyolipomas associated with TSC usually show multiple, bilateral and symptomatic natures compared with sporadic angiomyolipomas (2).

We report a patient with TSC who showed spontaneous retroperitoneal hematoma caused by renal angiomyolipoma that mimicking intraperitoneal hemorrhage.

### Case

A 40-year-old woman presented to our emergency department with right spontaneous pneumothorax. Her past medical history included epilepsy, and she was taking carbamazepine. Diffused bullous emphysema had been observed, and pleurodesis was carried out. In her clinical follow-up, two episodes of spontaneous pneumothorax was observed in the following twenty days.

**İletişim/Correspondence to:** Ömer Bayrak, Department of Urology, Faculty of Medicine, University of Gaziantep, Gaziantep, TURKEY

Tel: +90 342 3606060 / 76223 dromerbayrak@yahoo.com

Forty days after the first clinical evaluation, fever, decreasing urine output and weakness developed. Hemoglobin decreased to the level of 9 mg/dl, and abdominal computerized tomography (CT) was done. CT of the abdomen revealed massive bilateral renal angiomyolipomas and free fluid in the abdomen (Figure 1). The patient underwent laparotomy with these findings. During the operation, massive intraabdominal hemorrhage and rupture of posterior peritoneum on the right side were seen, and urology consultation was requested. We observed large retroperitoneal hematoma and increased kidney size. Right total nephrectomy was performed. The pathologic examination of the kidney revealed a 22x14x10 cm specimen that contained numerous angiomyolipomas up to 78 mm in greatest size. A total of 7 units blood was transfused to the patient. Preoperative serum creatinine level which was 0.7 mg/dl, increased to the level of 3.4 mg/dl early postoperative period. In cranial and thorax CT scan, diffuse subependymal calcified nodules and multiple parenchymal air cysts in lungs were determined and TSC was diagnosed in conjunction with other findings (Figures 2 and 3). None of the relatives had a history of TSC. Because of the progressive rising of serum creatinine level and decreasing urine output, temporary peritoneal dialysis was performed. Unfortunately, the patient died due to poor respiratory function, in fifteenth day postoperatively.

**Received:** 15.10.2011 **Accepted:** 06.02.2012

**Geliş Tarihi:** 15.10.2011 **Kabul Tarihi:** 06.02.2012

DOI: 10.5455/GMJ-30-2012-72

www.gantep.edu.tr/~tipdergi

ISSN 1300-0888

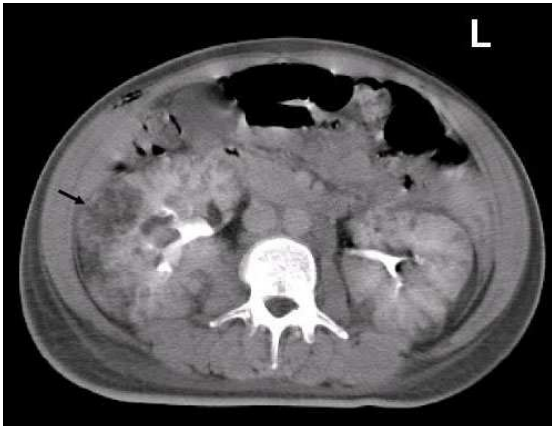


Figure 1. Abdominal CT showed bilateral multiple renal angiomyolipomas.

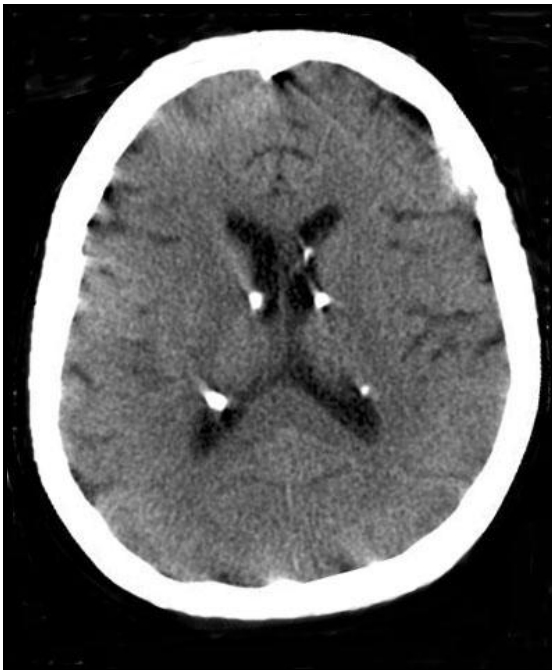

Figure 2. Cranial CT showed subependymal nodules.

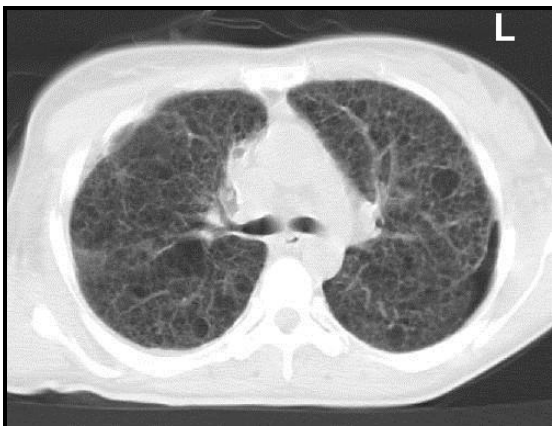


Figure 3. Thorax CT showed multiple parenchymal cysts in lungs.

### Discussion

This patient showed spontaneous retroperitoneal hematoma caused by angiomyolipoma that mimicking intraperitoneal hemorrhage. While bleeding and retroperitoneal hematoma are not rare conditions, intraperitoneal rupture of retroperitoneal hematoma is the first condition according to our knowledge.

Oesterling and co-workers (3) reviewed more than 600 cases of renal angiomyolipomas and concluded that lesions less than 4 cm had a low potential for hemorrhage or growth and recommended conservative management.

Van Baal et al. (2) reexamined 20 patients after 5 years and found that 20% had enlarged tumors, 35% had renal hemorrhage requiring hospitalization, 10% required nephrectomy and 5% died.

Harabayashi et al. (4) were retrospectively analyzed 12 patients with TSC, and they concluded that immediate arterial embolisation is mandatory for symptomatic tumors and that annual follow-up is sufficient for asymptomatic tumors, especially for those showing slow growth or in patients after decade three.

In a case, Kushwaha et al. (5) were reported that multifocal renal angiomyolipoma presenting as massive intraabdominal hemorrhage. During surgery large right-sided renal mass was found measuring 15x15x10 cm and four hundred milliliter of blood was present in peritoneum. In another case, Granata et al. (6) were reported that spontaneous retroperitoneal hemorrhage due to massive rupture of renal angiomyolipoma. It was an unusual onset of TSC, and was treated with nephrectomy (6). Tan and Toh (7) were reported life threatening intraperitoneal hemorrhage with abdominal compartment syndrome because of unusual presentation of renal angiomyolipoma. First they were made to carry out an emergency laparostomy. Laparostomy was achieved the effect of relieving the intraperitoneal hypertension, the nephrectomy was carried out after 48 hour of optimization in the Surgical Intensive Care Unit (7).

Although traditionally recognized as a neurological and dermatological disorder, renal disease is a frequent manifestation of TSC and the leading cause of death in adults with TSC (8). This patient's cause of death was not directly renal, but it may be accelerated by acute hemorrhage, massive transfusion and operative distress. TSC patients with large renal angiomyolipomas should be evaluated in their routine follow-up with cautious for potential risks of hemorrhage.

### References

1. Young J, Povey S. The genetic basis of tuberous sclerosis. *Mol Med Today* 1998;4(7):313-9.
2. Van Baal JG, Smits NJ, Keeman JN, Lindhout D, Verhoef S. The evolution of renal angiomyolipomas in patients with tuberous sclerosis. *J Urol* 1994;152(1):35-8.
3. Oesterling JE, Fishman EK, Goldman SM, Marshall FF. The management of renal angiomyolipoma. *J Urol* 1986;135(6):1121-4.

4. Harabayashi T, Shinohara N, Katano H, Nonomura K, Shimizu T, Koyanagi T. Management of renal angiomyolipomas associated with tuberous sclerosis complex. *J Urol* 2004;171(1):102-5.
5. Kushwaha R, Dhawan I, Arora R, Gupta K, Dhupia JS. Multifocal renal angiomyolipoma presenting as massive intraabdominal hemorrhage. *Indian J Pathol Microbiol* 2010;53(2):340-1.
6. Granata A, Basile A, Figuera M, Mignani R, Fiore CE. Spontaneous retroperitoneal hemorrhage due to massive rupture of renal angiomyolipoma treated with nephrectomy: an unusual onset of tuberous sclerosis complex. *Clin Nephrol* 2009;71(4):441-4.
7. Tan BW, Toh KL. Life threatening intraperitoneal hemorrhage with abdominal compartment syndrome: unusual presentation of renal angiomyolipoma. *Int J Urol* 2010;17(9):820-1.
8. Shepherd CW, Gomez MR, Lie JT, Crowson CS. Causes of death in patients with tuberous sclerosis. *Mayo Clin Proc* 1991;66(8):792-6.