

Parotid gland papillary adenocarcinoma in a child

Bir çocukta parotis bezi papiller adenokarsinoma

Baharudin Abdullah¹, Izny Hafiz Zainon¹, Farveen Marican², Mukarramah Che Ayub²

¹Universiti Sains Malaysia, School of Medical Sciences, Department of Otolaryngology-Head and Neck Surgery, Kubang Kerian, Kelantan

²Department of Pathology, Hospital Raja Perempuan Zainab II, Kota Bharu, Kelantan

Abstract

Papillary adenocarcinoma or cystadenocarcinoma is a rare malignancy of salivary gland which usually affects major salivary gland such as parotid. Although, papillary adenocarcinoma has a higher incidence in older age group, it should also be considered in younger patients. Local excision such as total parotidectomy with or without neck dissection, followed by radiotherapy is the main treatment. A case of parotid gland papillary adenocarcinoma in a 14 years old patient was reported. A total parotidectomy and postoperative radiotherapy were performed. There was no recurrence of tumor after 1 year of follow up.

Keywords: Cystadenocarcinoma; papillary adenocarcinoma; parotid

Özet

Papiller adenokarsinoma veya kistadenokarsinoma, parotis gibi genellikle majör tükürük bezini etkileyen tükürük bezinin nadir malign tümördür. Papiller adenokarsinoma yaşlılarda daha yüksek insidense sahip olmasına karşın genç hastalarda da dikkate alınmalıdır. Boyun diseksiyonlu veya diseksiyonsuz total parotidektomi gibi lokal eksizyon sonrasında radyoterapi ana tedavidir. On dört yaşında bir hastada parotis bezi papiller adenokarsinoma olgusu bildirildi. Total parotidektomi ve postoperatif radyoterapi gerçekleştirildi. Bir yıllık takip sonrasında tümör nüksü yoktu.

Anahtar kelimeler: Kistadenokarsinom; papiller adenokarsinom; parotis

Introduction

Papillary adenocarcinoma (also known as papillary cystadenocarcinoma or mucous producing adenopapillary carcinoma) is a rare neoplasm which histologically is characterized by fingerlike projection of connective tissue into cyst or cavity of glands and follicle and covered by neoplastic epithelium (1). It is first defined by WHO in 1991 as a distinct form of malignant neoplasm and grouped in the low grade adenocarcinoma (2). In this case report, we presented a 14 years old patient who has parotid gland papillary adenocarcinoma.

Case

A 14 years old Malay girl presented with a history of painless swelling at the right post auricular region for more than 2 years, which gradually increased in size. Patient denied any constitutional symptoms of loss of weight or loss of appetite. There was also no history of facial nerve palsy. Examination showed a mass at right post auricular region measuring 3 cm by 3 cm, non tender and soft to firm in consistency. Other examinations were unremarkable.

Fine needle aspiration cytology of the mass was done twice and both results showed many large groups of loosely cohesive cells and mucoid material. Most were of the intermediate type with few goblet or mucin secreting cells. There was no squamous epithelium seen. These results were consistent with mucoepidermoid

carcinoma.

Computed tomographic (CT) scan of the neck (Figure 1) showed a well defined round homogeneously enhancing lesion in the superficial lobe of right parotid gland posterior to the right auricle, measuring 2.1 cm by 1.7 cm. No calcification and no dilated parotid duct were seen.

A total parotidectomy with facial nerve preservation was performed. Intraoperatively, there was a heterogeneous mass of right parotid with bluish skin color. Enlarged lymph nodes at the pre parotid area also was removed and sent for histopathological assessment. The patient recovered post operatively without any complications. The histopathological findings of the tumor were consistent with papillary adenocarcinoma of the right parotid with lymph nodes metastasis (Figure 2).

Microscopically, there was a fairly well capsulated nodular lesion which composed of well defined papillary and complex glandular structures which were lined by columnar cell. Nuclei were round to oval and vesicular with fairly abundant cytoplasm. Abundant mucin production was seen with few cystic spaces and capsule was infiltrated by tumor cells. A few microcalcification (psammoma bodies) was seen. Section of all lymph nodes also showed tumor deposit similar to main tumor (Figure 3). The deep lobe of parotid gland was within normal limit. The patient was then referred to the oncology team and completed the radiotherapy treatment.

İletişim/Correspondence to: Baharudin Abdullah, Department of Otolaryngology-Head and Neck Surgery, School of Medical Sciences, Universiti Sains Malaysia, 16150 Kubang Kerian, Kelantan, MALAYSIA
Tel: +6 0976 76416 baharudin@kb.usm.my

Received: 19.03.2011 **Accepted:** 16.04.2012
Geliş Tarihi: 19.03.2011 **Kabul Tarihi:** 16.04.2012

DOI: 10.5455/GMJ-30-2012-88
www.gantep.edu.tr/~tipdergi
ISSN 1300-0888

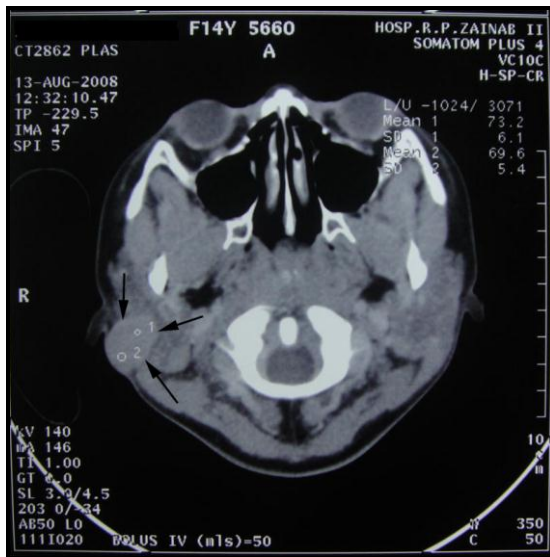

Figure 1. Axial view of CT scan showed a well defined round homogeneously enhancing lesion in the superficial lobe of the right parotid gland posterior to the right auricle.

Discussion

Papillary adenocarcinoma or cystadenocarcinoma is a rare malignant tumor which consists less than 3% of all salivary gland and oral cavity tumors (3,4). It usually affects adults with mean age of 59 years old and involving major salivary gland such as parotid. In 1996, Foss et al. (5) reported a large series of this tumor with a total of 57 cases, age ranging from 20 to 86 years old and 71% of them aged more than 50 years old. Incidence in younger age is very rare and only two cases of papillary cystadenocarcinoma have been reported at the age of 8 and 12 years old (6,7). Czarniecki et al. (6) reported a case of twelve years old boy with submandibular papillary adenocarcinoma while Agarwal et al. (7) reported an eight years old boy with minor salivary gland papillary adenocarcinoma of the right cheek.

Clinically, patient may just present with asymptomatic mass and sometimes with typical malignant changes. Even though it is classified as low grade adenocarcinoma, it has more aggressive biologic behavior compared with other low grade adenocarcinoma. It has a tendency to recur and 17% of cases reported also had cervical lymph node metastasis during first presentation (8).

Grossly the tumor may appear to be large, hemorrhagic with necrosis. Microscopic findings of papillary adenocarcinoma may reveal presence of nuclear pleomorphism with prominent papillary growth pattern. It usually has mucin production with no squamous or intermediate component. Present of stromal invasion usually denotes poor prognosis. When cystic component is prominent, it is termed as papillary cystadenocarcinoma. Differential diagnosis include polymorphous low grade adenocarcinoma, mucoepidermoid carcinoma, acinic cell carcinoma or metastatic carcinoma particularly from thyroid (1).

Imaging such as CT scan or MRI may not revealed typical features of malignant neoplasm as it is a low grade malignancy. Fine needle aspiration cytology is helpful in the diagnosis. Typically it will show papillary clusters of atypical columnar and cuboidal cells with nuclear atypia. However, it is also reported that cystadenocarcinoma may cause difficulty in cytological diagnosis (9).

Treatment of papillary adenocarcinoma consists of primarily local excision such as parotidectomy (5). Facial nerve or bone resection also should be undertaken if involved. If there is detectable lymph nodes metastasis, neck dissection followed by radiotherapy treatment is advisable (10).

Our patient typically presented with a history of painless swelling at the right post auricular region for more than 2 years, which gradually increased in size.

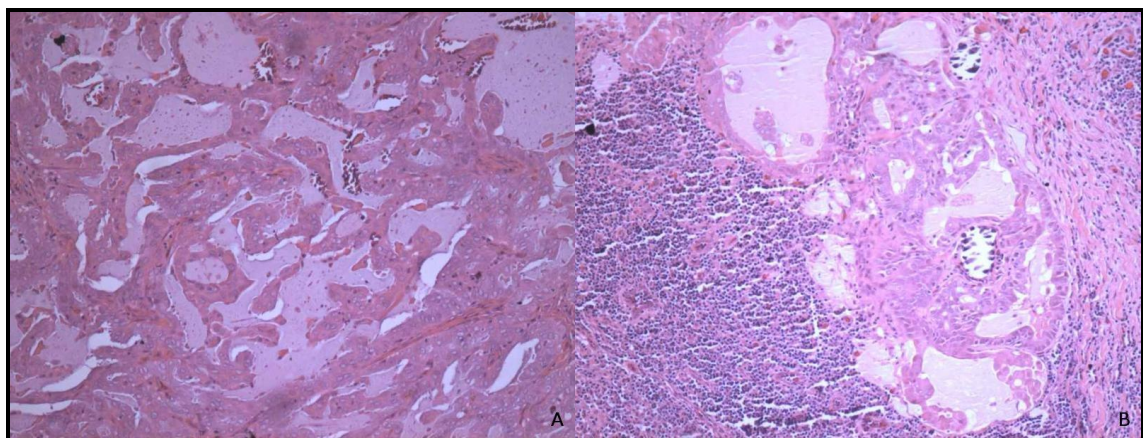


Figure 2. A) The tumor is arranged in papillary configuration and B) Psammoma bodies in the tumor (Low power magnification, x 10 with hematoxylin and eosin staining).

The fine needle aspiration cytology showed a mucoepidermoid carcinoma and CT scan showed a well defined round homogeneously enhancing lesion in the superficial lobe of right parotid gland. She was managed by total parotidectomy with facial nerve preservation. Postoperatively, the histopathology confirmed lymph nodes metastasis and she received complete radiotherapy treatment for six weeks. There was no recurrence of tumor after 1 year of follow up.

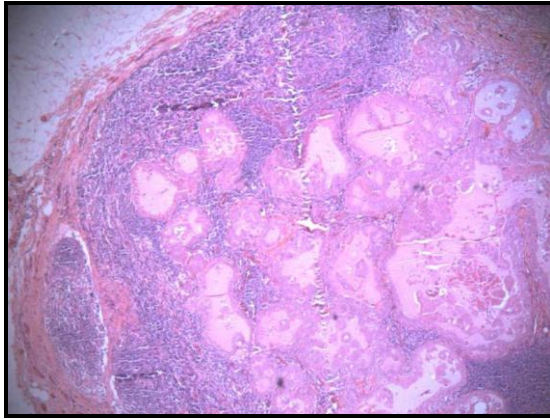


Figure 3. Tumor metastasis into the pre parotid lymph node (Low power magnification, x 10 with hematoxylin and eosin staining).

In conclusion, papillary adenocarcinoma is a rare malignant salivary gland tumor with high incidence in the older age group. However, presentation in younger

age group also should be considered. Our patient, a 14 years old girl was initially misdiagnosed as mucoepidermoid tumor based on cytological examination. However, post operative histopathology confirmed it as papillary adenocarcinoma.

References

1. Nakagawa T, Hattori K, Iwata N, Tsujimura T. Papillary cystadenocarcinoma arising from minor salivary glands in the anterior portion of the tongue: a case report. *Auris Nasus Larynx* 2002;29(1):87-90.
2. Seifert G, Sobin LH. *Histological Classification of Salivary Gland Tumours*, Second ed. Berlin, Springer, 1991:1-38.
3. Blanck C, Eneroth CM, Jakobsson PA. Mucus-producing adenopapillary (non-epidermoid) carcinoma of the parotid gland. *Cancer* 1971;28(3):676-85.
4. Nagao T, Sugano I, Matsuzaki O, Hara H, Kondo Y, Nagao K. Intraductal papillary tumors of the major salivary glands: case reports of benign and malignant variants. *Arch Pathol Lab Med* 2000;124(2):291-5.
5. Foss RD, Ellis GL, Auclair PL. Salivary gland cystadenocarcinomas. A clinicopathologic study of 57 cases. *Am J Surg Pathol* 1996;20(12):1440-7.
6. Czarnecki EJ, Spickler EM, Keohane M, Roennecke W. Cystic papillary adenocarcinoma of the submandibular gland in a child. *AJNR Am J Neuroradiol* 1996;17(6):1038-40.
7. Agarwal S, Das P, Singh MK, Sharma A, Karak AK. Papillary cystadenocarcinomas of salivary glands with oncocyctic epithelial lining: report of 2 cases. *Int J Surg Pathol* 2008;16(3):341-4.
8. Mostofi R, Wood RS, Christison W, Talerma A. Low-grade papillary adenocarcinoma of minor salivary glands. Case report and literature review. *Oral Surg Oral Med Oral Pathol* 1992;73(5):591-5.