

Case report

Bilateral implant-retained auricular prosthesis in a patient with Treacher Collins syndrome: a case reportSeçil Karakoca Nemli,^{1*} Esma Başak Gül,²Merve Bankoğlu Güngör¹¹Department of Prosthodontics, Faculty of Dentistry, Gazi University, Ankara, ²Department of Prosthodontics, Faculty of Dentistry, İnönü University, Malatya, Turkey**ABSTRACT**

INTRODUCTION: Treacher Collins Syndrome (TCS), a rare autosomal dominant disorder, primarily affects the development of facial structures. Although surgical reconstruction is the treatment of choice for auricular deformities that result from TCS, the implant-retained auricular prosthesis must be considered when surgical reconstruction is not possible.

CASE REPORT: In this case report, reconstruction of the bilateral congenitally missing ears of a patient resulting from TCS with implant-retained facial prosthesis was described. Three extraoral implants were placed at bilateral defect sites. After 3-month healing period, osseointegration was confirmed manually objectively by means of resonance frequency analysis. Implant-retained silicone auricular prostheses with bar-clips attachments were fabricated. Follow-up examination was carried out every 6 months.

CONCLUSION: After 4 years of function, implants were successful, however deterioration of the prosthesis was observed and replacement prostheses were provided. Prosthetic rehabilitation of the patient resulted in acceptable functional and cosmetic results and enabled the patient return comfortably to society.

KEYWORDS: Ear deformities; Franceschetti-Klein syndrome; mandibulofacial dysostosis; maxillofacial prosthesis implantation; Treacher Collins syndrome

CITATION: Karakoca Nemli S, Gül EB, Bankoğlu Güngör M. Bilateral implant-retained auricular prosthesis in a patient with Treacher Collins syndrome: a case report. *Acta Odontol Turc* 2014;31(1):31-5

INTRODUCTION

Treacher Collins Syndrome (TCS), also known as mandibulofacial dysostosis or Franceschetti-Klein syndrome, is a rare autosomal dominant disorder of the cranio-facial morphogenesis that affects 1:50.000 live births.¹ This disorder was described by British ophthalmologist Edward Treacher Collins in 1900 and re-evaluated by the Swiss ophthalmologist Adolphe Franceschetti and Klein in 1949. TCS is thought to be caused by impaired development of structures derived from the first and second branchial arches between the fifth and eighth week of intrauterine growth.²

Symptoms of the syndrome ranges from mild to severe. Characteristic features are usually symmetrical and include abnormalities of the external ear, atresia of the auditory canal, bilateral conductive hearing loss, hypoplasia of the zygomatic complex and mandible, cleft palate, and down slanting palpebral fissures, frequently accompanied by lower eyelid coloboma and a paucity of eyelashes medial to the defect. Cognitive development and intelligence is not affected in TCS however, associated hearing loss and oral malformation can lead to delays in speech.³

Facial deformities may have a significant impact on patients' speech and quality of life. In addition, absence of an auricle, in the presence of an auditory canal, affects hearing; because the auricle gathers sound and directs it into the canal. The auricle also helps to localize sounds, especially in conjunction with the other ear.⁴ Alternatives for ear reconstruction are autogenous and prosthetic reconstruction. Autogenous techniques yield consistent results in majority of patients with congenital auricular deformity.⁵ However it has disadvantages those often requires numerous surgical procedures spanning several years and the resulting structure may not be anatomically correct and esthetically pleasing.^{5,6} Prosthetic reconstruction of the auricle became a viable alternative with extraoral use of osseointegrated implants.

Osseointegrated implants enhance retention and stability of the prostheses and overcome the complications of previous methods.⁷ Attachments facilitate proper

Received: May 03, 2013; Accepted: June 24, 2013

*Corresponding author: Seçil Karakoca Nemli, Gazi University, Faculty of Dentistry, Department of Prosthodontics, 8. cadde, 82. sokak, 06510, Emek, Ankara, Türkiye;
e-posta: secilkarakoca@yahoo.com

positioning of prostheses, skin and mucosa are protected from irritation caused by mechanical retention devices or adhesives, enhanced esthetics can be obtained by creation and maintenance of fine feathered margins, the longevity of the prostheses is also extended by the use of implants, as marginal degradation due to daily application and removal of adhesives is eliminated.⁸ Therefore, implant retention is currently considered the standard of care in facial rehabilitation. In the present report, reconstruction of the bilateral congenitally missing ears of a patient resulting from TCS, with implant-retained facial prosthesis was described.

CASE REPORT

A 17-year-old female patient affected by TCS presented for reconstructive treatment. Clinical examination revealed that the patient had bilateral completely anotic ears, hypoplasia of zygomatic complex and maxilla, and down-slanting palpebral fissures (Figure 1). The patient's medical history revealed that atresia of the auditory canal was treated. For esthetic reconstruction, bilateral implant-retained auricular prosthesis was planned. Potential implant sites were evaluated for bone quantity by means of computed tomography scans. The objective of this evaluation was to determine optimal implant positions for functionally and esthetically pleasing prostheses. The optimal implant site was found to have insufficient bone, therefore bilateral implants were placed posteriorly. Implants inserted using a two-stage procedure.⁷ Three extraoral implants, 5 mm in length, (EO implant; Institut Straumann AG, Basel, Switzerland) were placed at each site. After 3-month healing period, implants were exposed. Implant stability was assessed manually and also measured objectively by means of resonance frequency analysis (RFA) described by Meredith *et al.*⁹ A standardized abutment (Smartpeg, Integration Diagnostics AB, Goteburg, Sweden) was inserted into the implants. The probe of magnetic wireless resonance frequency analyzer (Osstell Mentor, Integration Diagnostics AB, Goteburg, Sweden) was held until the instrument beeped and displayed the implant stability quotient (ISQ) value (Figure 2). The ISQ value was used as a measurement of implant stability. ISQ values ranging between 1 and 100 indicates that the higher the ISQ, the more stable is the implant.⁹ ISQ values of 6 implants were ranging between 32 and 49 at abutment connection. The mean ISQ values of right and left site implants were 46.8 ± 4.2 and 44 ± 4.4 , respectively. ISQ values were also measured at 6 months (right: 43.7 ± 4.2 and left: 45.7 ± 4.9), 12 months (right: 47.3 ± 2.5 and left: 49.7 ± 1.5), 24 months (right: 50.7 ± 1.2 and left: 50 ± 3.2) and 36 months (right: 50.3 ± 1.5 and left: 49.7 ± 2.1) follow-up controls.

Abutments were connected to the implants and tightened with a torque control device (Institut Straumann

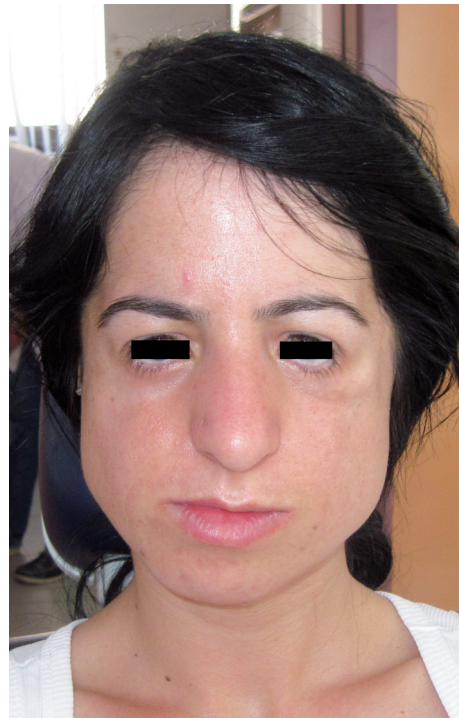

Figure 1. Frontal view of the patient affected by the Treacher Collins Syndrome

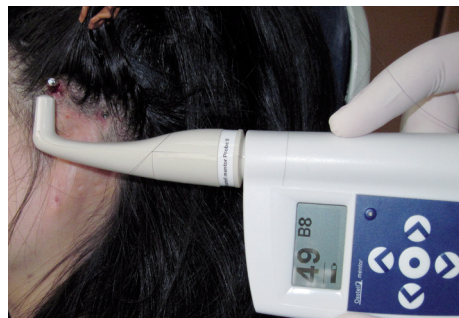

Figure 2. RFA measurement of one of the implants in the defect site

AG), up to 15 Ncm, as recommended by the manufacturer. The skin flap was sutured (Silk Suture, Boz; Ankara, Turkey) and gauze packing was applied. The peri-implant tissue was allowed to heal for 2 weeks.

Hair bearing skin was lubricated with petroleum jelly. Impression copings (Institut Straumann AG), were secured on abutments and impressions were made using a vinyl polysiloxane impression material (Express; 3M ESPE, St Paul, MN, USA). The impression was poured in type III dental stone (Labstone; Heraeus Kulzer, Armonk, NY, USA) and allowed the stone to set. Before fabricating the bar which is used to splint the implants and provide retention by means of clips, the wax patterns of the prostheses were fabricated to determine optimal bar position. On the left side, uppermost implant was decided not to be used for supporting the bar-clip retention system because of unfavorable angulation.

On the cast including implant and abutment analogues, the bars (Dolder Bar Matrix; Institut Straumann AG), were fabricated. The accuracy of the fitting of the bar was verified on the patient (Figure 3). Acrylic resin (Panacryl; Arma Dental, Istanbul, Turkey) substructures that housed the retentive clips were fabricated. Wax pattern of the prostheses were then completed on the definitive cast. The size, shape, position and fit were evaluated on the patient. The auricular prostheses were fabricated from silicone which was intrinsically pigmented. Silicone was processed as described previously (Figure 4).¹⁰ Color matching of the prostheses was found sufficient by the patient and the clinicians, therefore extrinsic coloration was not applied (Figures 5,6). The prostheses were inserted and the patient was instructed in home care. The patient was instructed to clean the prosthesis and skin around the abutments daily with a soft tooth brush and irrigate with warm water and soap to remove skin accretions. Also, the patient was told not to sleep with the prostheses. After delivery of the prosthesis, the patient was examined a week later. Then, clinical follow-up examinations were carried out every 6 months, unless some complications occurred sooner. The patient has been wearing the prostheses for 4 years. The skin around the attachments appeared healthy, and retention of the prostheses was good. The patient was happy with the appearance of the prostheses as she wore earrings. However, discoloration and deterioration at thin edges of the prostheses was observed at the third year recall examination, therefore replacement prostheses were provided. The patient provided written informed consent that the data and the photographs can be used for scientific purposes.

DISCUSSION

High success rates has been reported for the implants in the auricular site ranging from 93-100%.^{6,11-14} The success criteria for craniofacial implants¹⁵ was proposed by modifying dental implant success criteria described by Albertsson *et al.*¹⁶ The clinical manifestation of osseointegration is the absence of implant mobility, both at placement and during function. Widely used clinical technique to determine craniofacial implant mobility is assessing the implant abutments manually for the presence of clinically detectable mobility by means of lateral application of pressure to the implant by two opposing instruments, and recording as positive or negative. However an objective method to measure stability of craniofacial implants might be beneficial. Measuring implant stability by means of RFA, a reliable, easy, predictable and objective method, primary and secondary stability of implants can be quantified. Therefore, in cases with low stability at placement or at the end of the healing period,

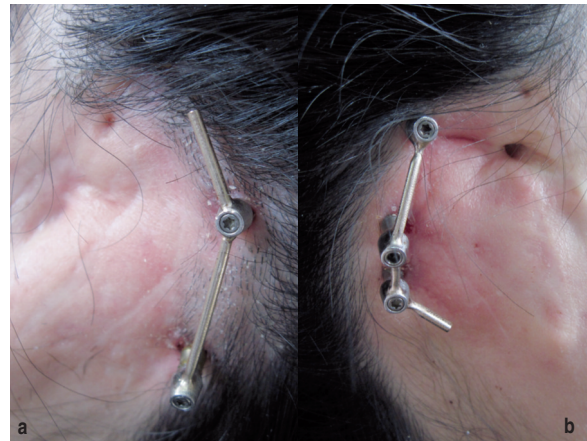

Figure 3. Dolder bar in place with passive fit for both sides

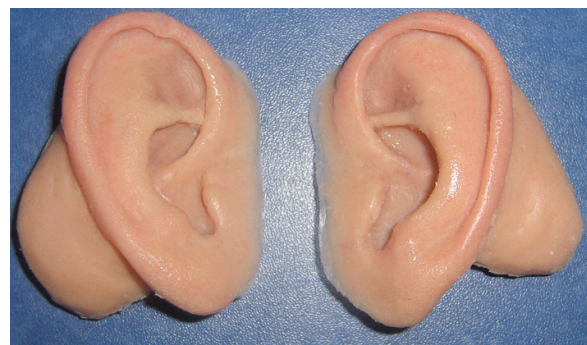

Figure 4. Silicone auricular prostheses

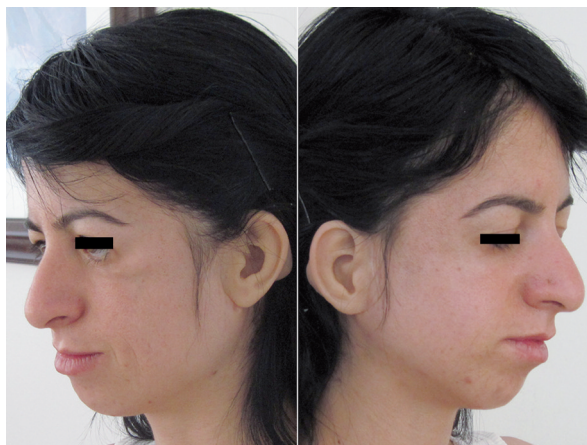

Figure 5. Right and left side profile view of the patient with auricular prostheses

extending the healing period may be a simple approach to gain additional stability. A low ISQ value at a post-loading examination may indicate disintegration of implant-bone interface and ongoing failure. In such a case, superstructure of the implant may be removed and unloaded healing period may give the implant sufficient time to regain stability.¹⁷ In the present case, RFA method was applied at the placement, at the end of

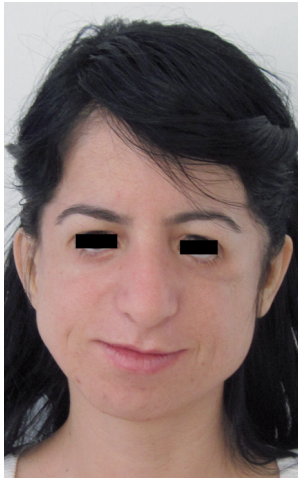


Figure 6. Frontal view of the patient with auricular prostheses

healing period and at postloading examinations. As quantitative measurement of craniofacial implant stability has very limited application in the literature^{17,18} comparison of the ISQ values of the present case is not reliable. However, increase over time in the ISQ values for clinically successful implants may be a good predictor of implant prognosis. According to the authors' opinion, routine clinical application of RFA to craniofacial implants may be beneficial for monitoring implant prognosis.

To achieve an optimal prosthetic result, location of implants is critical. During treatment planning, consultation of the surgeon and the maxillofacial prosthodontist is necessary in order to avoid suboptimal implant placement. A surgical template is recommended for accurate placement at the time of surgery. For auricular defects, two or three osseointegrated implants are placed along an arc approximately 20 mm posterior to the external auditory meatus at the 6:00, 9:00, and 12:00 positions for the right ear and at the 12:00, 3:00, and 6:00 positions for the left ear. The distance between implants should be approximately 11 mm.⁷ This arc corresponds to antihelix portion of a correct positioned ear. Antihelix is the thickest portion of an auricular prosthesis. Thus, implants, abutments, retentive attachments, and acrylic resin substructure can be hidden under the prosthesis. However, placement of craniofacial implants for extraoral prosthetic rehabilitation in patients with abnormal bone and soft tissue anatomy can be a challenge for surgeons. In case of improper implant positions, modifications in retentive system are required. In the present case, implants were placed posterior to optimal implant site due to unavailability of bone. Dolder bars were fabricated to splint implants. To enable the placement of auricular prostheses at the ideal position, the acrylic resin substructure part of the retention system was mod-

ified to extend under antihelix portion. Thus, the acrylic resin substructure did not only carry retentive clips but also gave rigidity to the silicone prostheses. The patients' hair could hide the posterior extension of the prostheses. In the left site, implants were placed in the hair bearing scalp compulsorily due to inadequate bone of the desired implant site. To prevent these implants from complications, the patient was instructed to shave the skin around the implants regularly. Thereby, immobilization of the skin could be provided. In the literature, a case report of a patient with congenitally missing ears also indicated posterior location of implants than optimal position.¹⁹ They designed a modified bar framework to place auricular prostheses at the ideal position.¹⁹

The complications of the treatment were discoloration and deterioration of the thin edges of the prostheses over time, and retention degradation of the clips. Discoloration and deterioration of edges are complications related to silicone material. A remarkable discoloration was detected at the end of the three-years. In the literature, life span for facial prostheses has been reported to vary between one to two years.^{4,6,8,20} It has been reported that intrinsic characteristics of the material, pigments, personal habits of the wearer (cleaning regimes and use of cosmetics), and environmental staining (climate, fungal, and body oil accumulation) contribute to the lifespan of prostheses.⁸ According to the authors' experience, personal habits and exposing the prostheses to environment have more effect on prostheses' lifespan than other factors. In the present case, extended lifespan of the prostheses may be attributed to protection of the prostheses by hair and meticulous maintenance carried out by the patient. Retention degradation was observed 10, 18, and 30 months after the insertion of the first prostheses. Retention was improved by activating Dolder bar matrix with the activator device and instructions in insertion and removal of the prostheses were reminded to the patient. Requirements for clip activation in bar-clips retained prostheses were also reported in the literature.^{6,20}

CONCLUSION

Implant retention for auricular prostheses improves patient's confidence, and sense of security in social life enhances the quality of life, providing high satisfaction with the prostheses. Implants reveal high success in the auricular region. However, in patients with abnormal bone anatomy, implant placement in suboptimal positions might be required. In these cases, modifications in the prosthetic design may be performed. Despite limited lifespan of the silicone material, implant-retained prostheses provide a satisfying reconstructive option for the patients with auricular defects.

ACKNOWLEDGEMENTS

This case was presented in the 18th Congress of Balkan Stomatological Society 25-28 April 2013, Skopje, Macedonia.

Conflict of interest disclosure: The authors declare no conflict of interest related to this study.

REFERENCES

- Marsella P, Scorpecci A, Pacifico C, Tieri L. Bone-anchored hearing aid (Baha) in patients with Treacher Collins syndrome: tips and pitfalls. *Int J Pediatr Otorhinolaryngol* 2011;75:1308-12.
- Dixon J, Trainor P, Dixon MJ. Treacher Collins syndrome. *Orthod Craniofac Res* 2007;10:88-95.
- Marres HA, Cremers CW, Dixon MJ, Huygen PL, Joosten FB. The Treacher Collins syndrome. A clinical, radiological, and genetic linkage study on two pedigrees. *Arch Otolaryngol Head Neck Surg* 1995;121:509-14.
- Menner AL. *A Pocket Guide to the Ear*. 1st edn. New York: Thieme Medical Publishers; 2003. p.1-143.
- Thorne CH, Brecht LE, Bradley JP, Levine JP, Hammerschlag P, Longaker MT. Auricular reconstruction: indications for autogenous and prosthetic techniques. *Plast Reconstr Surg* 2001;107:1241-52.
- Aydin C, Karakoca S, Yilmaz H, Yilmaz C. Implant-retained auricular prostheses: an assessment of implant success and prosthetic complications. *Int J Prosthodont* 2008;21:241-4.
- Henry PJ. Maxillofacial prosthetic considerations. Wortington P, Branemark PI, eds. *Advanced Osseointegration Surgery: Applications in the Maxillofacial Region*. 1st edn. Chicago: Quintessence; 1992. p.313-26.
- Hooper SM, Westcott T, Evans PL, Bocca AP, Jagger DC. Implant-supported facial prostheses provided by a maxillofacial unit in a U.K. regional hospital: longevity and patient opinions. *J Prosthodont* 2005;14:32-8.
- Meredith N, Alleyne D, Cawley P. Quantitative determination of the stability of the implant-tissue interface using resonance frequency analysis. *Clin Oral Implants Res* 1996;7:261-7.
- Seelaus R, Troppmann RJ. Facial prosthesis fabrication: coloration techniques. Taylor TD ed. *Clinical Maxillofacial Prosthetics*. 1st edn. Chicago: Quintessence Pub. Co; 2000. p.233-44.
- Wright RF, Zemnick C, Wazen JJ, Asher E. Osseointegrated implants and auricular defects: a case series study. *J Prosthodont* 2008;17:468-75.
- Jacobsson M, Tjellstrom A, Fine L, Andersson H. A retrospective study of osseointegrated skin-penetrating titanium fixtures used for retaining facial prostheses. *Int J Oral Maxillofac Implants* 1992;7:523-8.
- Nishimura RD, Roumanas E, Sugai T, Moy PK. Auricular prostheses and osseointegrated implants: UCLA experience. *J Prosthet Dent* 1995;73:553-8.
- Leonardi A, Buonaccorsi S, Pellacchia V, Moricca LM, Indrizzi E, Fini G. Maxillofacial prosthetic rehabilitation using extraoral implants. *J Craniofac Surg* 2008;19:398-405.
- Abu-Serriah MM, McGowan DA, Moos KF, Bagg J. Outcome of extra-oral craniofacial endosseous implants. *Br J Oral Maxillofac Surg* 2001;39:269-75.

16. Albrektsson T, Zarb G, Worthington P, Eriksson AR. The long-term efficacy of currently used dental implants: a review and proposed criteria of success. *Int J Oral Maxillofac Implants* 1986;1:11-25.

17. Karakoca-Nemli S, Aydin C, Yilmaz H, Sarisoy S. Ostell stability measurements of craniofacial implants by means of resonance frequency analysis: 1-year clinical pilot study. *Int J Oral Maxillofac Implants* 2012;27:187-93.

18. Heo SJ, Sennerby L, Odersjö M, Granström G, Tjellström A, Meredith N. Stability measurements of craniofacial implants by means of resonance frequency analysis. A clinical pilot study. *J Laryngol Otol* 1998;112:537-42.

19. Kumar PS, Satheesh Kumar KS, Savadi RC. Bilateral implant-retained auricular prosthesis for a patient with congenitally missing ears. A clinical report. *J Prosthodont* 2012;21:322-7.

20. Visser A, Raghoebar GM, van Oort RP, Vissink A. Fate of implant-retained craniofacial prostheses: life span and aftercare. *Int J Oral Maxillofac Implants* 2008;23:89-98.

Treacher Collins sendromlu bir hastada bilateral implant destekli kulak protezi uygulaması: bir olgu bildirimini

ÖZET

TANITIM: Treacher Collins Sendromu (TCS) başta yüz yapılarının gelişimini etkileyen, nadir görülen, otozomal dominant bir bozuktur. TCS olgularında kulak deformitelerinin tedavisinde cerrahi rekonstrüksiyon yöntemleri ilk tedavi seçeneği olarak düşünülür. Cerrahi yöntemlerin uygulanmadığı durumlarda implant destekli kulak protezleri düşünülür.

OLGU BİLDİRİMİ: Bu olgu bildiriminde TCS sonucu çift taraflı kulak deformitesine sahip bir hastada implant destekli kulak protezi uygulaması sunulmuştur. Her bir defekt bölgesine 3 adet ekstra oral implant yerleştirilmiştir. Üç aylık iyileşme dönemi sonunda implantların osseointegrasyonu hem manuel olarak hem de rezonans frekans analizi yöntemi ile objektif olarak tespit edilmiştir. Bar-klips ataçman sistemine sahip implant destekli silikon protezler yapılmıştır. Hasta 6 aylık kontrollere çağrılarak değerlendirilmiştir.

SONUÇ: Hastanın 4 yıllık takibi sonucunda implantların başarılı olarak fonksiyon gördüğü gözlenmiştir. Ancak silikon protezin yapısındaki bozulma sebebiyle yeni bir protez yapılmıştır. Protezler hastaya fonksiyonel ve estetik açıdan uygun bir tedavi seçeneği olmuş ve hastanın toplum yaşamına geri dönmesini sağlamıştır.

ANAHTAR KELİMELER: Çene-yüz protezi implantasyonu; Franceschetti-Klein sendromu; kulak deformiteleri, mandibulofasiyal dizostozis; Treacher Collins sendromu