



ARAŞTIRMA / RESEARCH

Bladed peek cage using the anterior approach in multiple-level degenerative cervical disc herniation: a case series of 156 patients

Çoklu seviye dejeneratif servikal disk hernilerinde anterior yaklaşımla bıçaklı kafes uygulaması: 156 olguluk klinik seri

Emre Bilgin¹, Gökhan Çavuş¹, Vedat Açık¹, Ali Arslan¹, Semih Kıvanç Olguner¹, İsmail İstemem¹, Yurdal Gezeran¹, Ali İhsan Ökten¹

¹Adana City Training and Research Hospital, Department of Neurosurgery, Adana, Turkey

Cukurova Medical Journal 2019;44(Suppl 1):383-390.

Abstract

Purpose: This study aimed to evaluate the efficacy of cervical discectomy with bladed peek cage and differences in clinical outcomes, complication rates, and radiological findings of patients with multiple-level cervical degenerative disc herniation in terms of age, sex, and number of levels.

Materials and Methods: The following data were assessed: demographic data, patient complaints, symptoms, neurologic examination and radiologic findings, postoperative outcomes, and complications of surgery. We assessed 156 patients who had level 2, 3, and 4 cervical degenerative disc herniation detected between 2012 and 2018 via radiological examination.

Results: Of the patients, 41.6% (n = 65) were men and 58.4% (n = 91) women. The patients were aged 32–76 years, with an average age of 50.68 years. Moreover, 85.2% (n = 133), 13.5% (n = 21), and 1.3% (n = 2) of patients presented with level 2, 3, and 4 cervical degenerative disc herniation, respectively. All patients received medications as a conservative treatment during the preoperative period, and 79.5% (n = 124) underwent physiotherapy. In terms of complications, five patients developed neurological deficit and one developed superficial wound infection during the early postoperative period.

Conclusion: The fusion rate may be similar to the stabilization, and cervical region movements may be achieved after performing anterior cervical plaque surgery with cage as well as anterior cervical discectomy and bladed peek cage surgery in patients with level 2 or higher cervical degenerative disc herniation and/or cervical spondylosis.

Keywords: Anterior discectomy, bladed cage, cervical degenerative disc herniation

Öz

Amaç: Klinik çalışmamızda multiple seviyeli servikal dejeneratif disk hernilerinde (2-4 seviye) yaş, cinsiyet, seviye sayısı, şikayet ve bulgular gözönünde bulundurularak anterior servikal diskektomi ile beraber bıçaklı kafes uygulaması ve cerrahi sonrası hastaların klinik düzelmeleri, komplikasyon oranları ve radyolojik olarak değerlendirilmeleri amaçlanmıştır.

Gereç ve Yöntem: 2012-2018 yılları arasında 2,3 ve 4 seviyeli servikal dejeneratif disk hernisi tespit edilen 156 hastanın şikayet, semptom, nörolojik muayene, radyolojik bulgular ve cerrahi olarak uygulanan diskektomi ve bıçaklı kafes ile postoperatif sonuçlar ve komplikasyonlar değerlendirilmiştir.

Bulgular: Hastaların %41.6'sı (65 hasta) erkek, %58.4'ü (91 hasta) kadındı. Yaş aralıkları 32-76 ve yaş ortalamaları 50.68'di. %85.2'si (133 hasta) iki mesafe, %13.5'i (21 hasta) üç mesafe, %1.3'ü (2 hasta) dört mesafe servikal disk hernisine sahipti. Hastaların hepsi daha önce konservatif tedavi olarak ilaç kullanmış ve %79.5'i (124 hasta) fizik tedavi görmüştü. Hastalar postoperatif 3-36 ay ortalama 18 ay izlendi. Komplikasyon olarak, postoperatif erken dönemde 5 hastada nörodefisit, 1 hastada yüzeysel yara enfeksiyonu gelişti.

Sonuç: İki ve daha fazla seviyeli servikal dejeneratif disk hernili ve spondilozlu hastalara uygulanan anterior servikal diskektomi ve bıçaklı kafes ameliyatları ile anterior plakla stabilizasyona gerek kalmaksızın servikal bölgenin hareketlerinin korunması sağlanabilir.

Anahtar kelimeler: Anterior diskektomi, bıçaklı kafes, servikal dejeneratif disk hernisi

Yazışma Adresi/Address for Correspondence: Dr. Emre Bilgin, Adana City Training and Research Hospital, Department of Neurosurgery, Adana, Turkey E-mail: dremreblgn@gmail.com

Geliş tarihi/Received: 12.05.2019 Kabul tarihi/Accepted: 06.08.2019 Çevrimiçi yayın/Published online: 27.09.2019

INTRODUCTION

Cervical disc herniation develops due to degenerative processes, and it is a group of disease affecting the spinal cord and roots. Such condition is commonly observed during the third and fourth decades of life, causing symptoms, such as herniation of the nucleus pulposus and tears in the annulus fibrosis in acute or chronic process. As discs continue to degenerate with age, changes in adjacent bones and soft tissues can be observed, and cervical spondylotic myeloradiculopathy occurs secondary to ischemia and due to pressure within the cord with nerve root involvement^{1,2}. Radiculopathy, myelopathy, or both may be observed. Surgical treatment aims to remove herniated disc and/or osteophyte causing pressure on the spinal cord³.

In 1954, Smith and Robinson first performed anterior discectomy, and fusion techniques were initially used by Cloward in 1961⁴. Fusion aims at place bone graft to the discectomy distance. Moreover, in 1964, Hirsch has emphasized that bone fusion was not required in every case of cervical disc disease, and simple discectomy in single-level disc herniation is an effective method⁵. In 1970, Caspar et al. have shown that the internal fixation and instrumentation method can be used in cervical discectomy⁶.

Initially, grafts obtained from the iliac bone were used in fusion; however, the use of such method was discontinued due to complications, such as severe pain in the graft region during the postoperative period, graft collapse, graft displacement, and infection⁷.

Anterior cervical discectomy and fusion are standard treatment methods for disc herniation, and both methods have high fusion rates and satisfactory clinical outcomes as they relieve spinal cord pressure. Approximately 75% of degenerative cervical disc pathologies, such as disc herniation and osteophyte, occur anteriorly^{8,9,10}. The reformation of cervical sequence destroyed in the preoperative period may be achieved with the use of grafts or cages placed in disc distance or between vertebral bodies using the anterior approach^{9,11}, which is easier and causes less trauma than the posterior approach. Neural structures are directly relieved with this approach, and regression in osteophytes with fusion, protection in disc distance height, and extension in the foramen may be achieved. The aim of such method is to

protect or reproduce the sequence and balance the vertebral column. If appropriate cervical sequence may not be formed or lost in the postoperative period, axial neck pain will occur due to the use of insufficient surgical materials, neurological deterioration, and neighboring segment disease in subsequent years^{9,11}.

The use of the anterior surgical approach for degenerative cervical herniation affecting two or more levels, anterior cervical discectomy for cervical spondylosis, and bladed cage, was emphasized. Thus, this study aimed to assess the efficacy of such procedures in protecting the physiological disc distance height without anterior plaque support, thereby preventing foramen stenosis and nerve tissue compression^{10,11}.

In our study, unlike the literature, we recommend the use of bladed peek cage in anterior procedures in multiple level cervical disc hernia.

MATERIALS AND METHODS

Anterior cervical discectomy and spinal surgery with cage were performed on 156 patients with cervical degenerative disc herniation affecting two or more levels, radiculopathy, and/or myelopathy detected between 2012 and 2018 in our clinic. However, anterior cervical plaque was not used in this study. The study was initiated Adana City Training And Research Hospital and The study was approved by the Adana City Training And Research Hospital Ethics Committee (Date: 08.05.2019, Decision Number: 442).

Patients whose symptoms were not relieved after medical treatment for at least 6 weeks and those presenting with neck and arm pain who had at least two levels of cervical degenerative disc between C3 and C7 and who underwent cervical magnetic resonance imaging (MRI) were included in the study.

Data collection

The following data were obtained: age of the patients, sex, patient complaints, herniation level and number, neurologic examination findings, type of surgery, and postoperative complications. The patients were assessed retrospectively, and file information, monitoring results, and surgical notes were evaluated.

Since degeneration in the discs occurs at multiple levels and cervical prosthesis is used in more than one

level of cervical disc herniation, patients with single-level cervical disc herniation; those with instability on dynamic radiographs; those with a history of cervical spinal trauma and previous cervical spinal surgery; those younger than 30 years; those with active rheumatic disease, osteoporosis (DEXA T score < -1.0), metabolic bone disease, or psychological disorders; and those who were morbidly obese and were on immunosuppressive treatment within the last year were excluded.

VAS scale

VAS scale of 10 cm from line and evaluating the severity of pain (VAS; 1, minimum; 10, maximum). Patients at the base point: no pain, no endpoint, expressed as severe pain in life. When calculating, the distance between the marked point and the starting point is measured in cm. The higher the score, the more severe the pain. The pain in the shoulder and arm of the patients was assessed using the visual analog scale (VAS)¹² before surgery, during the early period after surgery, and after 1 and 3 months from surgery.

Radiological evaluation

Dynamic cervical radiographs, cervical computed tomography (CT) scan, and cervical spinal MRI were performed on all patients. The angle between the C2 vertebra corpus on the posterior limit and the straight lines drawn from the posterior limit of the C7 vertebra corpus on the lateral cervical graphs were used to evaluate cervical axis. If the axis was < 0°, the patient was diagnosed with kyphosis. If the axis was 0°–10°, the patient had a straight spine, and if the axis was > 10°, the patient was diagnosed with lordosis (Figure 1).

Surgical technique

The technique was performed via a standing anteromedial approach from the right side. Discectomy was performed using a blade, curette, and pituitary forceps. Both anterior cortical cartilage and endplate were preserved, while the posterior longitudinal ligament and bony spurs were removed.

Discectomy and excision of osteophytes if available were performed on patients whose preoperative herniation levels were detected via fluoroscopy using the anterior approach. The blades of the cage were opened under fluoroscopic guidance, and the herniation levels were detected after cervical bladed

cages were placed in the emptied disc distances (Figure 2).

Odom's criteria have been used for evaluation of healing. Excellent corresponds to all preoperative symptoms relieved; abnormal findings improved. Good corresponds to minimal persistence of preoperative symptoms; abnormal findings unchanged or improved. Fair means definite relief of some preoperative symptoms; other symptoms unchanged or slightly improved whereas poor describes symptoms and signs unchanged or exacerbated.

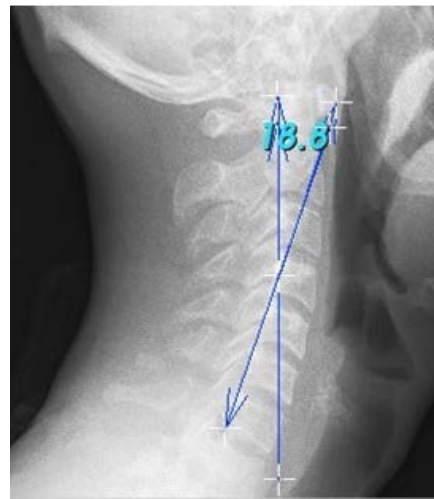


Figure 1. Angle measurement of cervical lordosis

Statistical analysis

The evaluation changing in cervical axis assessed by the visual analogue scale and 'patient Healing', assessed by the Odom's criteria. Statistically rating is done by SPSS Programming Languages. For numerical variables we use student-t testing and for nominal ordinary variables we use pearson χ^2 testing For Odom's Criteria¹³.



Figure 2. Bladed cervical peek cage (Spain) used in our patients

RESULTS

Of the 156 patients, 65 (41.6%) were men and 91 (58.4%) were women. The patients were aged 32–76 years, with an average age of 50.68 years. Approximately 85.2% (n = 133), 13.5% (n = 21), and 1.3% (n = 2) of the patients had two, three, and four distance degenerative cervical disc herniation. Herniation was commonly detected at C5-6 level in all patients, followed by at C6-7 level in 82 (52.5%) and C4–C5 in 41 (26.2%) patients. All patients received medical treatment for pain. Approximately 79.5% (n = 124) of the patients received physiotherapy with different number of sessions in the preoperative period, and 20.5% (n = 32) did not. Pain the neck and arm, which is the most common complaint, was observed in 89.8% (n = 140) of patients. Approximately 10.2% (n = 16) of patients complained of loss of motor strength. The onset of symptoms varied from 3 to 36 months.

Hypoesthesia was observed in dermatome areas appropriate for herniation levels in all patients (10.2%) who experienced loss of motor strength based on the neurological examination. Moreover, such condition was observed at the anterior part in C4-5, C5-6, C6-7, and C7-T1 sensory areas in 87.2% (n = 122) of patients with pain in the neck and arm. Dynamic radiograph, cervical CT scan, and MRI were performed in all patients in the preoperative period. Cervical radiograph and MRI were performed on patients who came for follow-up.

A total of 126 (80.7%) patients had a straight pain. Meanwhile, 22 (14.1%) presented with lordosis and eight (5.2%) with kyphosis based on cervical axis measurements on lateral cervical radiographs (Table 1). Lordosis was detected in 140 (89.7%) and kyphosis in five (3.2%) patients, and 11 (7.1%) patients had a straight spine according to postoperative cervical axis measurements (Table-1), (Figure-3).

Table 1. Preop and postoperative cervical axis (C2-C7) measurements

Preop Lordosis	Preop Straight Spain	Preop Kyphosis	Total
22 (14.1%)	126 (80.7%)	8 (5.2%)	156
Postop Lordosis	Postop Straight Spain	Postop Kyphosis	Total
140 (89.7)	11 (7.1%)	5 (3.2)	156

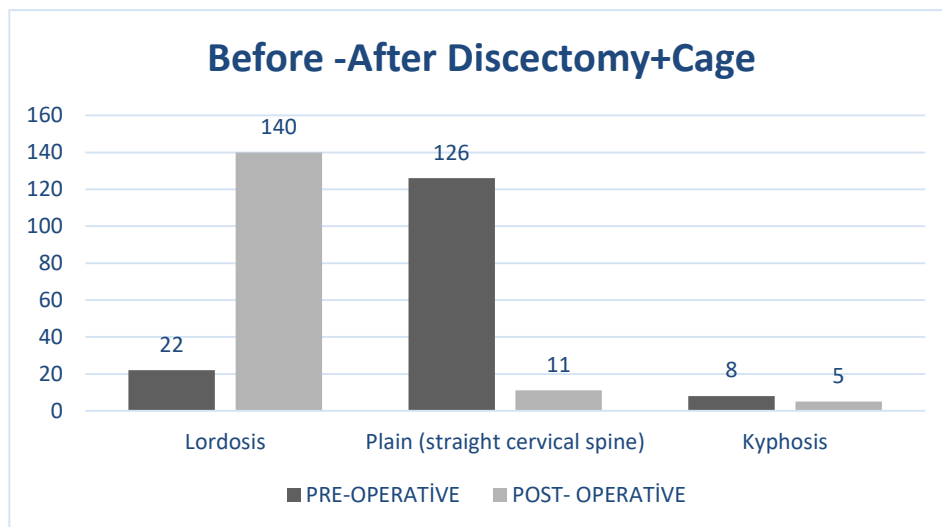


Figure 3. Pre-Operative and Post-Operative cervical axis (C2-7) measurements.

Table 2. Preoperative and postoperative VAS scores

Vas Score After Surgery	Early Postoperative Period	1 Month After Surgery	3 Months After Surgery
n = 122, VAS score of 8	n = 122, VAS score of 5	n = 110, VAS score of 4	n = 84, VAS score of 2
n = 18, VAS score of 7	n = 10, VAS score of 5 n = 8, VAS score of 6	n = 11, VAS score of 5	n = 5, VAS score of 5

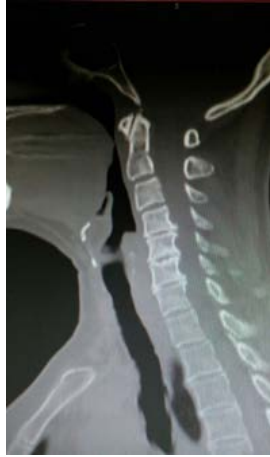

Figure 4. Preoperative sagittal computed tomography scan of C4-5, C5-6, and C6-7 level Herniopathy (HNP), osteophyte, and osteophyte.

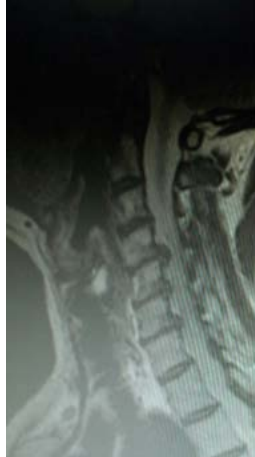

Figure 5. Preoperative sagittal magnetic resonance imaging of C4-5, C5-6, and C6-7 level HNP, osteophyte, and osteophyte.

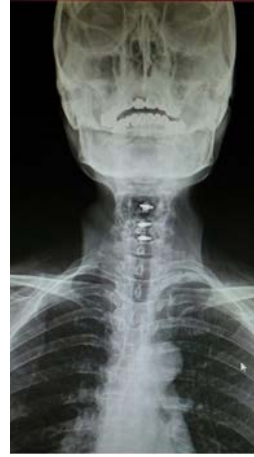

Figure 6. Postoperative anterior and posterior direct radiograph of C4-5, C5-6, and C6-7 bladed cage.

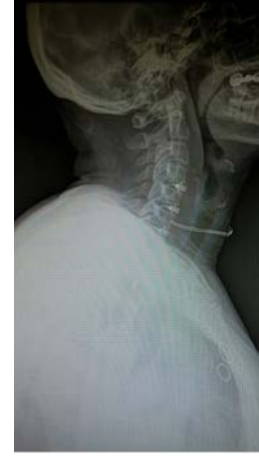

Figure 7. Postoperative lateral direct radiograph of C4-5, C5-6, and C6-7 bladed cage.

Quadriplegia, which was 3/5, became 2/5 by worsening in our patients, who had four distance cervical interventions, and in three of our patients, who had three distance cervical interventions, at the postoperative early period. Treatment with methylprednisolone was initiated according to the NASCIS protocol in the early period. Three patients recovered and underwent short-term passive physical treatment program. However, two patients did not recover based on the desired level. Superficial wound infection was observed in one patient, and appropriate antibiotic therapy was provided.

The patients were monitored for 18 months on average 3–36 months after surgery. Unsatisfactory outcome due to the use of insufficient bladed cages, neighboring segment disease, and deterioration in the cervical axis (cervical kyphosis) were observed after 13 months on average after the first surgery in four patients with level 2, one patient with level 3, and in

3.2% of all patients based on postoperative radiological and clinical findings during follow-up. Thus, fusion was performed with anterior cervical corpectomy cage and anterior cervical plaque by performing corpectomy on patients who required re-surgery. On radiological and clinical follow-up, deterioration was not observed.

Treatment for cervical disc disease primarily aims to relieve root and/or spinal cord pressure. The short-term clinical outcomes of decompression were similar. Meanwhile, the short-term outcomes of appropriate decompression performed were based on whether only discectomy or only cage after discectomy or cage + graft or disc prosthesis after discectomy was performed. However, long-term problems still persist. Therefore, when choosing the appropriate surgery, patients should be comprehensively evaluated by performing clinical assessment and radiologic procedures prior to

surgery to identify the best surgical approach. Long-term results should be considered, and decisions should be taken accordingly.

In conclusion, anterior discectomy with bladed peek cage is an appropriate surgical option even without the use of anterior cervical plaque support in terms of protecting and providing sufficient neural decompression and cervical sequence in cervical degenerative disc diseases and cervical spinal spondylosis. The long-term outcomes of patients who underwent fusion by placing cages + autograft bones were similar to those with prosthesis and cages or those whose discs are supported by anterior plaques.

DISCUSSION

The size of the cages should be adjusted in each patient. Smaller cages according to the disc distance cause dislocation and subsiding danger, whereas bigger cages according to the disc distance increase the risk of neighboring distance degeneration and cause stress in facet joints and accordingly pain. To provide fusion, the segment level with lesion should be accurately identified, and whether the use of a cage is the best option to treat the lesion must be considered. Moreover, the most appropriate implant should be chosen for the disc distance emptied in terms of structure, size, and shape, and bone graft should also be used with the implant for a successful fusion since cage fusion alone is not sufficient. In our study, herniation was commonly detected at the C5-6 level in all our cases, followed by at the C6-7 level in 82 (52.5%) and the C4-5 level in 41 (26.2%) patients. Such result was not in accordance with that of a previous study showing that of 37 patients, 12 (33%), 19 (51%), 2 (5%), 3 (8%), and 1 (3%) had herniation in the C5-6, C6-7, C3-4, C4-5, and C7-T1 level, respectively¹⁴.

Surgical treatment aims to decrease pressure in the spinal cord and nerve roots, protect cervical spinal sequence if it is deteriorated, prevent deterioration and instability after surgery, and increase the quality of life of patients by relieving symptoms. Various surgical approaches are used for the cervical spine in accordance with this aim^{8,9}.

The risk of developing neurologic deficit due to traction of the spinal cord and nerve roots is high, and the pressure from the anterior area may not be relieved using posterior approaches^{8,11,15}. The development of postoperative kyphosis and even

swan neck deformity may occur after posterior decompressions without instrumentation^{8,11,15}. However, neighboring segment degeneration may be observed as a long-term complication, which is observed in 25% of patients within 10 years after surgery¹⁶.

The anterior cervical approach may be performed in two ways: anterior cervical discectomy with and without fusion. A graft may be placed at the disc level after discectomy. These grafts may be autograft, allograft, synthetic graft, or cages. In recent years, cervical disc prosthesis is more commonly used in one-level cervical disc herniation, and the utilization of cervical disc prosthesis after discectomy still differs in the literature. In the study of Traynelis et al. in 2013, making a certain statement correlated to the usage of cervical disc prosthesis in cervical disc herniation is not possible after they have retrospectively investigated 10 series in which disc prostheses are used¹⁷.

When the stress distributions of intervertebral discs are analyzed, an increase in longitudinal stress was observed after anterior cervical discectomy and fusion^{18,19}. However, the use of cervical disc prosthesis facilitates continuous movement at the surgical level and decreases stress to reduce neighboring segment degeneration. Hybrid surgery performed by using cervical disc prosthesis may be preferred for mobile level if there is insufficient cervical movement in one level in patients with level 2 disc disease as an alternative to level 2 anterior cervical discectomy and fusion^{20,21}. The utilization of prosthesis is contraindicated in patients with insufficient cervical movement in terms of the presence of osteophyte forming bridge in case of collapse in more than 50% of disc distance^{22,23}. We used cervical disc prosthesis, which is an expensive device, only in patients with single-level disc herniation. We did not use disc prosthesis and hybrid system in our patients with two and more herniations.

In our postoperative follow-ups, arm and neck pain in 122 (87.1%) of 140 patients significantly and progressively decreased within the first 3 months. Arm pain in the remaining 18 (12.9%) patients decreased at a more distinct rate (68%) than neck pain. The preoperative VAS scores of 122 (87%) and 18 (23%) patients were 8 and 7, respectively. The VAS was used to evaluate the severity of neck and arm pain. In the early postoperative period, the VAS score decreased from 8 to 5 in the entire patient group; from 7 to 5 in 10 patients; and from 7 to 6 in

eight patients. A VAS score of 5 remained consistent 1 and 3 months after surgery. When VAS results of 110 patients coming for checkups in the postoperative 1st month were evaluated, VAS degree of 84 patients, who came for control in the postoperative 3rd month, reduced to 2 in terms of the patients, all of whose preoperative degrees were 4 (Table 2). The results of the current study were similar to those of previous studies, which used the hybrid system²⁴. The clinical outcomes were satisfactory in previous studies in which the iliac bone grafts were used for two distance anterior cervical discectomy and fusion²⁵. Although we did not use iliac graft in our study, a similar fusion rate was achieved using bones obtained from the patient's own osteophyte and vertebra corpus within the peek cages. In terms of the type of surgery, graft, plaque, screw systems must be performed in the anterior approach, and lateral mass screws and fusion in addition to laminectomy should be performed in the posterior approaches when instability was observed on dynamic radiograph images obtained during the preoperative period. Only discectomy and bladed cage implementation were performed since instability was not detected on dynamic radiograph.

Some of the points emphasized in our study include the protection of physiological disc distance height via anterior cervical discectomy and cage without the use of anterior cervical plaque, prevention of foramen stenosis and nerve root compression, and reduction of morbidity. All cages used in our study were bladed cages. Pereira et al. have performed anterior cervical discectomy and used peek cages. However, anterior cervical plaque was not used in 23 patients with level 3 disc herniation and in seven patients with level 4 disc herniation of the 30 patients included in their study. Moreover, they have emphasized that anterior discectomy and grafting may be performed safely and efficiently in patients with level 4 disc herniation²⁶. Cheng-Wei Chu et al. have reported that the long-term results of cage fusion without plaque in cervical degenerative disc disease are satisfactory²⁷. Mootaz Shousha et al. have shown that the importance of fixation support to implant in multi-level cervical spinal canal stenosis is still questioned²⁸. In our study, anterior plaque was not used, and we observed that the physiological height was protected based on the measurements of intervertebral disc distance after the use of cages in our controls.

Loss in disc height in anterior cervical discectomy

without fusion causes foramen collapse and foraminal stenosis in time. Recurrent radicular pain occurs and results in the recurrence of symptoms in patients whose osteophytes are not properly cleaned and foraminotomy is not performed well. Re-surgery may be required. The importance of support with plaque fixation to protect or to reform cervical lordosis was also discussed. Segmental kyphosis develops in numerous cases after anterior cervical discectomy without fusion^{27,29}. Repetition of surgery was planned, and support was provided by cage and anteridr plaque fixation together with the corpectomy as fractions in the upper and lower vertebra corpus, degeneration in upper or lower disc distances. Then, neighboring segment disease due to collapse in the cages was observed in five (3.2%) patients who were followed-up in our study. Anterior discectomy and fusion both correct sagittal deformity and effects caused by pressure in patients whose cervical lordosis is deteriorated or in those with kyphosis.

After performing clinical and radiologic examination in the postoperative period, the results were found to be similar with those of other studies performed. Notably, the usage of anterior cervical discectomy and cages achieved satisfactory long-term results even without the use of anterior plaques^{26,27,28,30}.

Yazar Katkıları: Çalışma konsepti/Tasarımı: EB; Veri toplama: VA, GÇ, SKO; Veri analizi ve yorumlama: VA, GÇ, AA; Yazı taslağı: EB, AİÖ; İçeriğin eleştirel incelenmesi: AİÖ, YG; Son onay ve sorumluluk: EB SKO, GÇ, VA, İİ, AA, AİÖ, YG; Teknik ve malzeme desteği: EB, YG, AİÖ; Süpervizyon: AİÖ; Fon sağlama (mevcut ise): yok.

Bilgilendirilmiş Onam: Katılımcılardan yazılı onam alınmıştır.

Hakem Değerlendirmesi: Dış bağımsız.

Çıkar Çatışması: Yazarlar çıkar çatışması beyan etmemişlerdir.

Finansal Destek: Yazarlar finansal destek beyan etmemişlerdir.

Author Contributions: Concept/Design : EB; Data acquisition: VA, GÇ, SKO; Data analysis and interpretation: VA, GÇ, AA; Drafting manuscript: EB, AİÖ; Critical revision of manuscript: AİÖ, YG; Final approval and accountability: EB SKO, GÇ, VA, İİ, AA, AİÖ, YG; Technical or material support: EB, YG, AİÖ; Supervision: AİÖ; Securing funding (if available): n/a.

Informed Consent: Written consent was obtained from the participants.

Peer-review: Externally peer-reviewed.

Conflict of Interest: Authors declared no conflict of interest.

Financial Disclosure: Authors declared no financial support

REFERENCES

1. Nadiri S. Servikal spondilolitik miyelopatide cerrahi yaklaşımın seçimi. *Türk Nöroşirürji Dergisi*. 2000;10:137-43.
2. Erol F. Servikal spondilolitik myelopatide klinik, tanı ve ayırıcı tanı. In *Servikal Dejeneratif Disc Hastalığı ve Üst Ekstremitte Tuzak Nöropatileri*, (Eds Koç RK): 234-44. Ankara, Buluş Tasarım ve Matb. 2009.
3. Ishihara H, Kanamori M, Kawaguchi Y, Nakamura H, Kimura T. Adjacent segment disease after anterior

- cervical interbody fusion. *Spine J.* 2004;4:624-8.
4. Cloward RB. The anterior approach for removal of ruptured cervical discs. *J Neurosurg.* 1958;15:602-16.
 5. Hirsch C. Cervical disc rupture: diagnosis and therapy. *Acta Orthop Scand.* 1964;30:172-86.
 6. Caspar W, Barbier DD, Klara PM. Anterior cervical fusion and caspar plate stabilization for cervical trauma. *Neurosurgery.* 1989;25:491.
 7. Savolainen S, Rinne J, Hernesniemi J. A prospective randomized study of anterior single-level cervical disc operations with long-term follow-up: surgical fusion is unnecessary. *Neurosurgery.* 1998;43:51-5.
 8. Zileli M. Servikal spondilolitik myelopatiye laminektomi. In *Servikal Dejeneratif Disc Hastalığı ve Üst Ekstremité Tuzak Nöropatileri*, (Eds Koç RK): Ankara, Buluş Tasarım ve Matb. 2009;285-96.
 9. Çaylı SR. Servikal spondilolitik myelopatiye anterior dekompresyon ve füzyon. In *Servikal Dejeneratif Disc Hastalığı ve Üst Ekstremité Tuzak Nöropatileri*, (Eds Koç RK): Ankara, Buluş Tasarım ve Matb., 2009;262-9.
 10. Bohlman HH, Emery SE, Goodfellow DB, Robinson JP. Robinson anterior cervical discectomy and arthrodesis for cervical radiculopathy. Long-term follow-up of one hundred and twenty-two patients. *J Bone Joint Surg Am.* 1993;75:1298-307.
 11. Fehlings MG, Barry S, Kopjar B, Yoon ST, Arnold P, Massicotte EM et al. Anterior corpectomy versus posterior laminoplasty for multilevel cervical myelopathy: A systematic review and meta-analysis. *Eur Spine J.* 2014;23:362-72.
 12. Carlsson AM. Assessment of chronic pain. I. Aspects of the reliability and validity of the visual analogue scale. *Pain.* 1983;16:87-101.
 13. Hee Jun Yoo, Jin Hoon Park, Han Yu Seong, and Sung Woo Roh: Comparison of surgical results between soft ruptured disc and foraminal stenosis patients in posterior cervical laminoforaminotomy. *Korean J Neurotrauma.* 2017;13:124-9.
 14. Yolas C, Ozdemir NG, Okay HO, Kanat A, Senol M, Atci İB et al. Cervical disc herniation operations through posterior laminoforaminotomy. *J Craniovertebr Junction Spine.* 2016;7:91-5.
 15. Janssen M, Bono C, Sasso R, Dekutoski M, Gokaslan ZL. Anterior versus posterior surgical approaches to treat cervical spondylotic myelopathy. Outcomes of the prospective multicenter AOSpine North America CSM study in 264 patients. *Spine.* 2013;38:2247-52.
 16. Hilibrand AS, Carlson GD, Palumbo MA, Jones PK, Bohlman HH. Radiculopathy and myelopathy at segments adjacent to the site of a previous anterior cervical arthrodesis. *J Bone Joint Surg Am.* 1999;81:519-28.
 17. Traynelis VC, Arnold PM, Fourney DR, Bransford RJ, Fischer DJ, Skelly AC. Alternative procedures for the treatment of cervical spondylotic myelopathy: arthroplasty, oblique corpectomy, skip laminectomy: evaluation of comparative effectiveness and safety. *Spine.* 2013;38:210-31.
 18. Eck JC, Humphreys SC, Lim TH, Jeong ST, Kim JG, Hodges SD et al. Biomechanical study on the effect of cervical spine fusion on adjacent-level intradiscal pressure and segmental motion. *Spine.* 2002;27:2431-4.
 19. Schwab JS, Diangelo DJ, Foley KT. Motion compensation associated with single-level cervical fusion: where does the lost motion go? *Spine.* 2006;31:2439-48.
 20. Duggal N, Pickett GE, Mitsis DK, Keller JL. Early clinical and biomechanical results following cervical arthroplasty. *Neurosurg Focus.* 2004;17:E9.
 21. Yoon DH, Yi S, Shin HC, Kim KN, Kim S. Clinical and radiological results following cervical arthroplasty. *Acta Neurochir (Wien).* 2006;148:943-50.
 22. Yi S, Ahn PG, Kim DH, Lee DY, Kim KN, Shin HC. et al. Cervical artificial disc replacement. Part 2: clinical experience with the cervical artificial disc. *Neurosurg Q.* 2008;18:96-103.
 23. Kim DH, Cammisa FP, Fessler RG. *Dynamic Reconstruction of the Spine.* 1st ed: New York, Thieme, 2006.
 24. Sasso RC, Smucker JD, Hacker RJ, Heller JG. Artificial disc versus fusion: a prospective, randomized study with 2-year follow-up on 99 patients. *Spine.* 2007;32:2933-40.
 25. Silber JS, Anderson DG, Daffner SD, Brislin BT, Leland JM, Hilibrand AS et al. Donor site morbidity after anterior iliac crest bone harvest for single-level anterior cervical discectomy and fusion. *Spine.* 2003;28:134-9.
 26. Pereira EAC, Chari A, Hempenstall J, Leach J, Chandran H, Cadoux-Hudson T. Anterior cervical discectomy plus intervertebral polyetheretherketone cage fusion over three and four levels without plating is safe and effective long-term. *J Clin Neurosci.* 2013;20:1250-5.
 27. Chu CW, Kung SS, Tsai TH, Huang TY, Hwang SL. Anterior discectomies and interbody cage fusion without plate fixation for 5-level cervical degenerative disc disease: A 5 year follow-up. *Kaohsiung J Med Sci.* 2011;27:524-7.
 28. Shousha M, Ezzati A, Boehm H. Four-level anterior cervical discectomies and cage-augmented fusion with and without fixation: *Eur Spinal J.* 2012;21:2512-9.
 29. Abd-Alrahman N, Dokmak AS, Abou-Madawi A. Anterior cervical discectomy (ACD) versus anterior cervical fusion (ACF), clinical and radiological outcome study. *Acta Neurochir (Wien).* 1999;141:1089-92.
 30. Choi MK, Kim SB, Park CK, Kim SM. Comparison of the clinical and radiologic outcomes obtained with single- versus two-level anterior cervical decompression and fusion using stand alone PEEK cages filled with allograft. *Acta Neurochir.* 2016;158:481-7.