



Efficacy of Intramedullar Locking Plate in Mild to Moderate Hallux Valgus Deformity: Early Outcomes

Hafif Orta Evre Halluks Valgus Tedavisinde Intramedullar Plak Uygulamasının Etkinliği: Erken Dönem Sonuçlar


Erdem DEĞİRMENCİ¹

 0000-0002-7988-4261

Ali Berat GERMAN²

 0000-0002-5875-6295

İstemi YÜCEL³

 0000-0002-0074-4654

¹Duzce University Medical Faculty
Department of Orthopedics and
Traumatology, Duzce

²Silivri State Hospital Department of
Orthopedics and Traumatology,
Istanbul

³Private Mehmet Toprak Hospital
Department of Orthopedics and
Traumatology, Istanbul

Sorumlu Yazar

Corresponding Author

Erdem DEĞİRMENCİ
erddegir@gmail.com

Geliş Tarihi / Received : 07.05.2019

Kabul Tarihi / Accepted : 26.07.2019

Çevrimiçi Yayın Tarihi /

Available Online : 30.07.2019

ABSTRACT

Aim: Hallux valgus is a complex deformity of the first metatarsophalangeal joint characterized by varus deformity of the first metatarsal bone, valgus deformity of the big toe, and lateral deviation of the extensor tendons and sesamoid bones. Several surgical methods have been described for correction of the deformity. Distal metatarsal osteotomy is a commonly used procedure in mild-to moderate hallux valgus. Different materials have been used for the fixation of osteotomy. The aim of this study was to evaluate radiological and clinical efficacy of intramedullar locking plate in hallux valgus surgery.

Material and Methods: Postoperative 6th month data of patients with mild-to moderate hallux valgus deformity who underwent distal metatarsal osteotomy using an intramedullary locking plate between 2012 and 2014 were evaluated retrospectively. The surgical procedure was applied by Mitchell technique. Clinical and radiological features of the patients were analyzed.

Results: Thirty-six (29 female, 7 male) patients with a mean age of 51.00±12.96 years were enrolled the study. Eight patients underwent bilateral surgery. There were statistically significant improvement in hallux valgus angle, distal metatarsal articular angles, and American Orthopaedic Foot and Ankle Society hallux valgus scores in the postoperative 6th month (all p values <0.001). No statistically significant difference were found between the preoperative and postoperative 6th month inter-metatarsal angle values (p=0.058).

Conclusion: The intramedullar locking plate usage in surgery of mild-to moderate hallux valgus deformity is an effective method providing strong fixation and quick recovery that led patients to gain an early improvement in the daily life activities.

Keywords: Hallux valgus; intramedullar locking plate; distal metatarsal osteotomy.

ÖZ

Amaç: Halluks valgus, birinci metatarsal kemiğin varus deformitesi, başparmağın valgus deformitesi, sesamoid kemikler ve ekstensör tendonların laterale yer değiştirmesi ile karakterize, birinci metatarso-falangial eklemin kompleks deformitesidir. Bu deformitenin düzeltilmesi için çeşitli cerrahi yöntemler tarif edilmiştir. Distal metatarsal osteotomi hafif orta evre halluks valgus cerrahisinde en sık kullanılan yöntemlerden biridir. Metatars osteotomi hattının fiksasyon materyali olarak çeşitli implantlar kullanılmaktadır. Bu çalışmanın amacı halluks valgus cerrahisinde intrameduller plak uygulamasının kısa dönem klinik ve radyolojik sonuçlarını ortaya koymaktır.

Gereç ve Yöntemler: 2012-2014 yılları arasında distal metatarsal osteotomi sonrası osteotomi hattı intrameduller kilitleli plak kullanılarak tespit edilen halluks valgus hastalarının operasyon sonrası 6. ay verileri retrospektif olarak değerlendirildi. Cerrahi yaklaşım olarak Mitchell distal metatarsal osteotomi tekniği uygulandı. Hastaların klinik ve radyolojik özellikleri incelendi.

Bulgular: Çalışmaya yaş ortalaması 51,00±12,96 yıl olan toplam 36 (29 kadın, 7 erkek) hasta dahil edildi. Sekiz hastaya her iki ayağından cerrahi uygulandı. Ameliyat sonrası 6. ayda yapılan değerlendirmelerde halluks valgus açısı, distal metatarsal eklemler ve Amerikan Ortopedik Ayak ve Ayak Bileği Birliği halluks valgus skorlarında istatistiksel olarak anlamlı düzelmeye izlendi (her üç p değeri <0,001). İntermetatarsal açı değerlendirildiğinde preoperatif ve ameliyat sonrası 6. ay arasında anlamlı bir değişiklik saptanmadı (p=0,058).

Sonuç: Hafif orta evre halluks valgus cerrahisinde osteotomi hattının tespitinde intrameduller kilitleli plak uygulaması, güçlü bir tespit sağlama ve hastaların günlük yaşam aktivitelerine hızlı dönüş imkanı sağlama açısından efektif bir yöntemdir.

Anahtar kelimeler: Halluks valgus; intrameduller kilitleli plak; distal metatarsal osteotomi.

INTRODUCTION

Hallux valgus (HV) is a complex deformity of the first metatarsophalangeal (MTP) joint, characterized by varus deformity of the first metatarsal bone, valgus deformity of the big toe, and lateral deviation of the extensor tendons and sesamoid bones (1). Several surgical methods have been described for the correction of HV deformity (2). The location, characteristics, and the severity of the pathology play an important role in choosing the surgical method. However, there is no universal method. Nevertheless, distal metatarsal osteotomy (DMO) is a commonly used procedure in mild-to moderate HV deformity (3,4).

Intramedullar locking plate (ILP) is one of the new generation implants with titanium which is used in the surgical treatment of HV. It has two types in clinical use with mono and multi locking distal holes. The ILP type with multi locking holes is widely used for more lateralization and stable fixation of big metatarsal head (Figure 1). Additionally, different materials such as screw, kirshner-wire, staple and plates have been used for the fixation of osteotomy (5). Despite the successful results reported about these implants, some complications such as implant loosening, recurrence, rotation, malunion, soft tissue irritation or foreign body reaction were mentioned in literature (6-8).

Based on these aspects, the aim of this study was to evaluate the early outcomes of ILP in patients with HV deformity in terms of radiological and clinical efficacy. According to our literature knowledge and review, our study is the first to assess the early outcomes of the ILP system in HV surgery.

MATERIAL AND METHODS

This retrospective study includes the patients with mild-to moderate HV who were above 18 years old, and underwent DMO with the Mitchell technique using ILP between the years 2012 and 2014. Study was approved by the Ethics Committee of Duzce University (Date: 13.07.2018 and Number: 2018/112).

Surgical Procedure

All the patients underwent surgery with the Mitchell technique using an ILP (V-TEK titanium) for fixation. The surgical procedures were performed in the supine position under spinal anesthesia and with a pneumatic tourniquet

by the same surgical team. An approximately 3-cm dorsal medial incision over the first MTP joint, and a linear capsular incision were made. Release of articular space and of soft tissues was made from same incision. The bunion was then shaved (exostectomy). A transverse osteotomy was performed using a 10×35×0.4 mm oscillating saw blade from the level of the metatarsal neck. The osteotomy was translocated and an appropriate-size plate was inserted intramedullary to the proximal part of first metatarsal under fluoroscopic imaging. It was fixed with 2 screws to the proximal cortex with the help of a guide. The lateralized metatarsal head was fixed with distal lag screws to the plate. The MTP joint capsule was closed by placing it in the joint reduction position. The tourniquet was opened after skin closure and bandage application and bleeding control was provided by compression. On the first postoperative day, a partial weight-bearing was allowed with modified HV shoe.

Clinical Evaluation

Clinical evaluation comprised extensive ligamentous laxity, ankle deformity, the presence of bursitis, deformities in other toes, and skin thickening of the foot. American Orthopaedic Foot and Ankle Society (AOFAS) HV scores were used in assessments (9). Patients were evaluated with monthly follow-up visits within six months period, postoperatively. During these follow-up visits, all patients were interviewed face-to-face to evaluate the sensitivity of the operation site and mobilization.

Full weight-bearing was permitted by modified HV shoes after the removal of the skin sutures in the 15th day, postoperatively. In the 1st month following surgery, all patients were allowed to turn their normal daily activities.

Radiological Assessment

HV angle (HVA) was measured by plain radiogram, in which the angle between the longitudinal axis of the first metatarsal and proximal phalanx was calculated (10,11). The distal metatarsal articular angle (DMAA) was evaluated as the angle between the long axis of the first metatarsal and the perpendicular line passing through the distal articular surface and the most distal line connecting the medial and lateral margins (12).

When the lateral side of the proximal phalanx passes the lateral joint boundary of the first metatarsal bone, the first MTP joint was considered as the subluxation (10). The tibial sesamoid position was graded according to the standard recommendations (13). The severity of the disease was based on the HVA value as follows: <15° normal, 16-20° mild, 21-39° moderate and >39° severe (14).

The improvement in the HVA was considered to be the most important indicator of the success of the surgical procedure (10). Bone bridging was evaluated in 4 cortices on the radiographs (15). A postoperative HVA above 20° was accepted as recurrence (16,17). On lateral views, the metatarsal osteotomy line was considered as malunion if it was welded to the long axis of the sagittal plane bone (18).

Statistical Analysis

The data were analyzed using the SPSS v.22 statistical package. Shapiro-Wilk test was used to analyze normality assumption and paired sample t-test was used to compare preoperative and follow-up inter-metatarsal angle (IMA), HVA, DMAA and AOFAS scores, a value of $p < 0.05$ was considered statistically significant.



Figure 1. Two kinds of intramedullar locking plate (v-tek titanium)

RESULTS

A total of 36 patients (29 females, 7 males) with a mean age of 51.00 ± 12.96 years (range 19-75 years) were included in this study. Bilateral surgery was applied to 8 patients.

The mean HV, DMAA, and AOFAS scores were determined to have significantly improved at the postoperative 6-month follow-up visit compared to the preoperative values (all p values <0.001). There was no statistically significant difference between the preoperative and postoperative 6 month IMA values of the patients ($p=0.058$) (Table 1).

In the evaluation of complications, the cortical fissure was seen in 2 patients and a drill was broken intra-medullary in one patient. Fixation with cerclage wires was applied to 2 patients and broken or of drill was left in place. Union problem was not observed in these patients. (Figure 2). Superficial wound infection was seen in 5 patients. None of the complications such as avascular necrosis, malunion, non-union, recurrence or nerve insult were observed.

Table 1. Comparison of preoperative and postoperative 6th month HVA, IMA, DMAA and AOFAS scores

	Baseline	Postoperative 6 th month	p
HVA	25.65±6.67	12.91±3.60	<0.001
IMA	12.98±5.14	12.09±5.03	0.058
DMAA	20.95±6.88	8.40±2.98	<0.001
AOFAS	48.14±8.70	86.30±5.20	<0.001

The data are given as mean±standard deviation, HVA: Halluks Valgus Angle, IMA: Inter-Metatarsal Angle, DMAA: Distal Metatarsal Articular Angles, AOFAS: American Orthopaedic Foot and Ankle Society

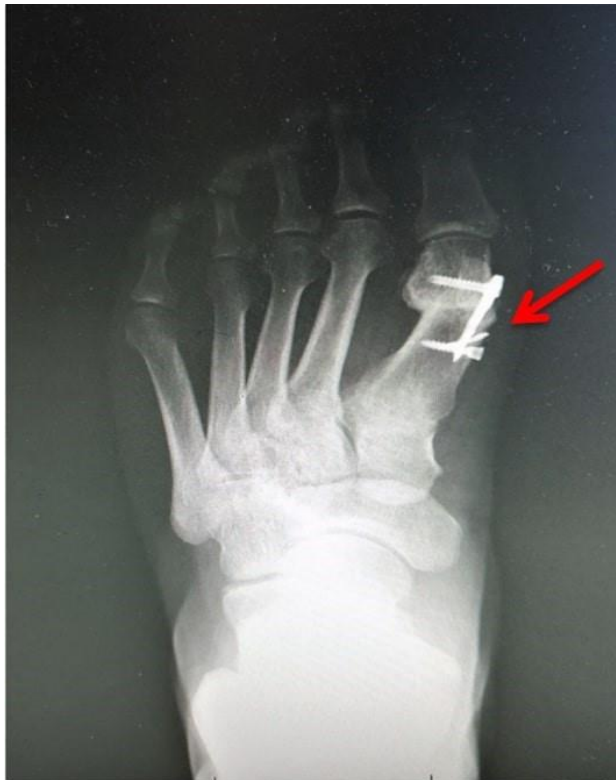

Figure 2. Broken drill did not cause any nonunion or poor outcome

DISCUSSION

This study aimed to evaluate the clinical and radiological outcomes of the ILP used by Mitchell technique for the treatment of mild-to moderate HV deformity and to discuss the results on healing time and return to daily life in the light of the pertinent literature.

Surgical treatment should be performed in patients who do not respond to conservative methods. The selected surgical technique should correct all components of the deformity: the medial bulge, increased valgus angulation of the proximal phalanx, increased first-second IMA, compliance of the MTP joint, sesamoid subluxation, pronation of the big toe, normal biomechanics of the first MTP joint and pain relief (10). At the same time, the chosen surgical method should not impair the function/biomechanics of the forefoot. When surgical treatment for HV deformity is planned, it is helpful for the physician to determine the radiographic examination findings together with the underlying complaint to which the surgical procedure is to be applied (19).

Surgical treatment options in HV include MTP soft tissue reconstruction, distal or proximal osteotomy of the first metatarsal, proximal phalangeal osteotomy, medial cuneiform osteotomy, MTP joint arthrodesis, and resection arthroplasty (19). In this context, different surgical methods such as proximal metatarsal osteotomy or DMO have been previously described (2). Mitchell technique has been accepted as an effective surgical method for mild to moderate HV surgery for many years (20). DMO has a limited efficacy in patients with severe HV that is more likely to develop postoperative complications (6,21).

The fixation materials are vital because of their primarily effect on the outcomes. Reduction problems or recurrence can also be seen due to fixation complications (6,16,22). The application of an ILP has some advantages over other methods, in terms of union, stability, and recovery time, as well as the complication rates, which are more likely to be reduced (23). In our study this fixation method showed not only radiological, but also clinical improvement. Furthermore, no recurrence, malunion, removal of the plate, or wound complications developed during the follow-up period.

The ILP system allows correction at the metatarsal head in a prone, supine or neutral position after transverse DMO. ILP provides strong fixation on osteotomy site, early bone bridging and weight-bearing. Compared to other endolog implants, the main disadvantage is that the locking screws, which are inserted into the metatarsal cottage in osteoporotic patients, can create fissures in the cortex, but this can be prevented with cerclage wires (23). This complication developed in 2 patients of the current study but they had no complaints of discomfort or unstable fixation. At all the stages of surgery, procedure is short and the method is easy to apply. Major advantages of the ILP system that we have demonstrated in our study were strong fixation, avoidance of metatarsal head migration, and rotation.

Supporting the literature knowledge revealing that early mobilization and full weight-bearing leading to an early maintenance of daily living activities after ILP usage in HV (24), our results were found to be consistent in which the patients were able to maintain full and early weight bearing one month after HV surgery with ILP (Figure 3).

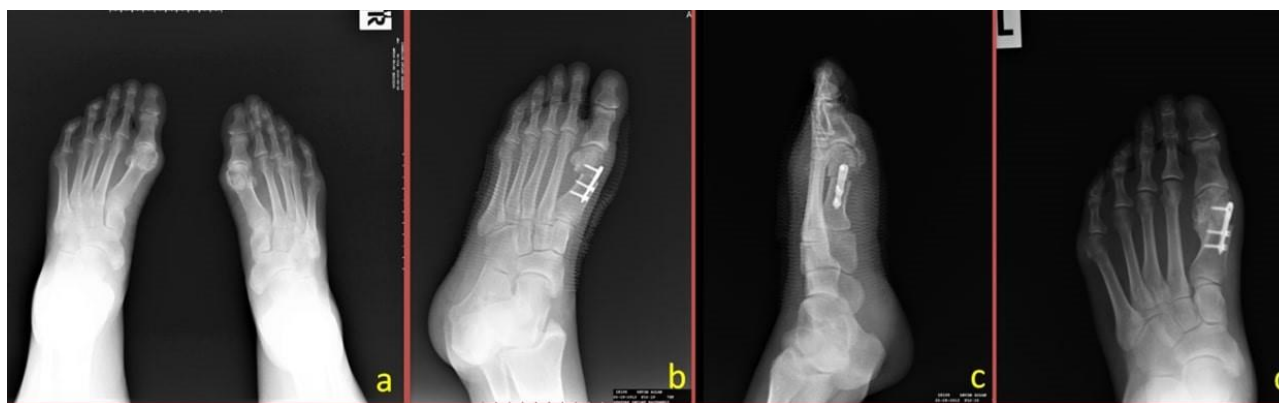

Figure 3. (a) Preoperative A-P x-ray, (b-c) Postoperative 2th day x-ray, (d) Postoperative 6th month x-ray

Limitations of our study were the lack of control group to make a comparison, and the short postoperative duration to observe the outcomes of HV surgery with ILP. Further prospective, and larger scale studies with comparison groups are needed to evaluate and demonstrate the efficacy of ILP in HV surgery in details.

CONCLUSION

According to our literature knowledge and review, our study is the first to assess the early outcomes of the ILP system in HV surgery, in which strong fixation and an early return to daily living activities were gained. ILP system in HV can be considered as a safer, easier, and effective surgical option in HV surgery.

Conflict of Interest: None

Financial Disclosures: None

Acknowledgement: Special thanks to Yıldız DEĞİRMENCİ, MD for been involved in drafting and translating the manuscript.

REFERENCES

- Nikolaou VS, Korres D, Xypnitos F, Lazaretos J, Lалlos S, Sapkas G, et al. Fixation of Mitchell's osteotomy with bioabsorbable pins for the treatment of hallux valgus deformity. *Int Orthop*. 2009;33(3):701-6.
- Wulker N, Suckel A. Osteotomien des Mittelfußes beim Hallux valgus [Metatarsal osteotomies for hallux valgus]. *Orthopade*. 2005;34(8):726-34.
- Coughlin MJ, Mann RA. Hallux valgus. In: Coughlin MJ, Mann RA, Saltzman CL, editors. *Surgery of the foot and ankle*. 8th ed. Philadelphia, PA: Mosby Elsevier; 2007. p.183-362.
- Chuchpaiwong B. Comparing proximal and distal metatarsal osteotomy for moderate to severe hallux valgus. *Int Orthop*. 2012;36(11):2275-8.
- Robinson AH, Limbers JP. Modern concepts in the treatment of hallux valgus. *J Bone Joint Surg Br*. 2005;87(8):1038-45.
- Acevedo JI. Fixation of metatarsal osteotomies in the treatment of hallux valgus. *Foot Ankle Clin*. 2000;5(3):451-68.
- Magnan B, Pezzè L, Rossi N, Bartolozzi P. Percutaneous distal metatarsal osteotomy for correction of hallux valgus. *J Bone Joint Surg Am*. 2005;87(6):1191-9.
- Burchard R, Massa R, Soost C, Richter W, Dietrich G, Ohrndorf A, et al. Biomechanics of common fixation devices for first tarsometatarsal joint fusion-a comparative study with synthetic bones. *J Orthop Surg Res*. 2018;13:176.
- Kitaoka HB, Alexander IJ, Adelaar RS, Nunley JA, Myerson MS, Sanders M. Clinical rating systems for the ankle hindfoot, midfoot, hallux, and lesser toes. *Foot Ankle Int*. 1994;15(7):349-53.
- Deenik AR, de Visser E, Louwerens JW, de Waal Malefijt M, Draijer FF, de Bie RA. Hallux valgus angle as main predictor for correction of hallux valgus. *BMC Musculoskelet Disord*. 2008;9:70.
- Roukis TS. Percutaneous and minimum incision metatarsal osteotomies: a systematic review. *J Foot Ankle Surg*. 2009;48(3):380-7.
- Coughlin MJ, Freund E. The reliability of angular measurements in hallux valgus deformities. *Foot Ankle Int*. 2001;22(5):369-79.
- Smith RW, Reynolds JC, Stewart MJ. Hallux valgus assessment: report of research committee of American Orthopaedic Foot and Ankle Society. *Foot Ankle*. 1984;5(2):92-103.
- Coughlin MJ. Hallux valgus. *J Bone Joint Surg Am*. 1996;78(6):932-66.
- Galasso O, Mariconda M, Romano G, Capuano N, Romano L, Iannò B, et al. Expandable intramedullary nailing and platelet rich plasma to treat long bone non-unions. *J Orthop Traumatol*. 2008;9(3):129-34.
- Chiang CC, Lin CF, Tzeng YH, Huang CK, Chen WM, Liu CL. Distal linear osteotomy compared to oblique diaphyseal osteotomy in moderate to severe hallux valgus. *Foot Ankle Int*. 2012;33(6):479-86.
- Huang PJ, Lin YC, Fu YC, Yang YH, Cheng YM. Radiographic evaluation of minimally invasive distal metatarsal osteotomy for hallux valgus. *Foot Ankle Int*. 2011;32(5):S503-7.
- Radwan YA, Mansour AM. Percutaneous distal metatarsal osteotomy versus distal chevron osteotomy for correction of mild-to-moderate hallux valgus deformity. *Arch Orthop Trauma Surg*. 2012;132(11):1539-46.
- Doğan A, Üzümcügil O, Akman YE. Halluks Valgus. *TOTBID Dergisi* 2007;6(3-4):88-94.
- Glynn MK, Dunlop JB, Fitzpatrick D. The Mitchell distal metatarsal osteotomy for hallux valgus. *J Bone*

- Joint Surg Br. 1980;62-B(2):188-91.
21. Giannini S, Faldini C, Vannini F, Digennaro V, Bevoni R, Luciani D. The minimally invasive osteotomy "S.E.R.I." (simple, effective, rapid, inexpensive) for correction of bunionette deformity. *Foot Ankle Int.* 2008;29(3):282-6.
 22. Portaluri M. Hallux valgus correction by the method of Bösch: a clinical evaluation. *Foot Ankle Clin.* 2000;5(3):499-511.
 23. Di Giorgio L, Touloupakis G, Simone S, Imparato L, Sodano L, Villani C. The Endolog system for moderate-to-severe hallux valgus. *J Orthop Surg (Hong Kong).* 2013;21(1):47-50.
 24. Schuh R, Hofstaetter SG, Adams SB Jr, Pichler F, Kristen KH, Trnka HJ. Rehabilitation after hallux valgus surgery: importance of physical therapy to restore weight bearing of the first ray during the stance phase. *Phys Ther.* 2009;89(9):934-45.