



## Air Embolism in Liver: A Rare Location

### Karaciğerde Hava Embolisi: Nadir Bir Yerleşim Yeri


Gülçin PATMANO<sup>1</sup>

 0000-0001-9138-035X

Remzi SALAR<sup>2</sup>

 0000-0002-5078-9367

Ahmet KAYA<sup>1</sup>

 0000-0002-8751-5298

#### ABSTRACT

Air embolism is a rare clinical entity that must be well recognized with high morbidity and mortality rates. Sensitive early diagnosis methods are available for air embolism, but these methods are not always easy to reach. With the detection of venous air embolism, mortality and morbidity can be reduced by rapid aspiration of air and concomitant treatment. It is important to recognize and prevent the problems that embolism may cause in the early period. In venous air embolism, the amount of aspirated air is directly proportional to mortality and morbidity. The most important approach here is to try to prevent the development of air embolism and to make an early diagnosis in possible cases, keeping in mind that it can always develop. In this case report, we present a 51-year-old female patient with the diagnosis of air embolism in the postoperative period and the treatments applied.

**Keywords:** Air embolism; laparoscopy; liver; intensive care unit.

#### ÖZ

Hava embolisi nadir görülen ancak yüksek morbidite ve mortalite oranları ile iyi tanınması gereken bir klinik durumdur. Hava embolisi için sensitif erken tanı yöntemleri bulunmaktadır, ancak her zaman bu yöntemlere ulaşmak kolay olmamaktadır. Venöz hava embolisinin saptanması ile birlikte, havanın hızla aspire edilmesi ve yandaş tedavilerin uygulanması ile mortalite ve morbiditede azalma sağlanabilmektedir. Önemli olan erken dönemde embolinin ortaya çıkarılabileceği sorunların tanınması ve önlenmeye çalışılmasıdır. Venöz hava embolilerinde, aspire edilen hava miktarı ile mortalite ve morbidite doğru orantılıdır. Burada en önemli yaklaşım hava embolisi gelişimini engellemeye çalışmak ve her zaman gelişebileceğini akılda tutarak olası durumlarda erken tanı koymaktır. Bu olgu sunumunda 51 yaşında kadın hastada postoperatif dönemde hava embolisi tanısı konması ve uygulanan tedaviler sunulmuştur.

**Anahtar kelimeler:** Hava embolisi; laparoskopi; karaciğer; yoğun bakım ünitesi.

#### INTRODUCTION

Gas embolism is an iatrogenic clinical problem mainly caused by gas entering the vascular system. In the literature, the term air embolism is used because air is the most common culprit in most clinical situations. However, embolism may occur following the use of other gases such as carbon dioxide (used during laparoscopy) and nitrogen protoxide. In arterial air embolism (AAE), air passes from heart defects or transpulmonary shunts into the systemic circulation and is referred to as paradoxical air embolism (PAE). Venous and arterial embolism have different presentations and effects that can be fatal if not recognized or treated.

Sorumlu Yazar

Corresponding Author

Gülçin PATMANO

gulcinpatmano@gmail.com

Geliş Tarihi / Received : 02.06.2019

Kabul Tarihi / Accepted : 22.08.2019

Çevrimiçi Yayın Tarihi /

Available Online : 23.08.2019

Presented as an oral presentation at 1<sup>st</sup> International Harran Congress on Multidisciplinary Studies (March 08-10, 2019, Sanliurfa).

The air entering the arterial system is well tolerated by most organs. However, organs with high oxygen consumption such as brain and heart are more prone to damage. Hypoperfusion and hypoxia develop as a result of end-arteriolar obstruction in these organs and cause cell damage. This further reduces oxygenation by causing edema in the tissue (1).

For the formulation of venous air embolism (VAE), there must be a connection between the gas and the vein and the pressure difference between them requires the gas to enter the venous system. The damage will depend on the amount of air entering, the speed of air entry and the position of the patient. Very high amounts of air such as 5 ml/kg are often required for major effects such as cardiovascular stability and cardiac arrest. However, clinical symptoms may occur even with small amounts such as 0.5 ml/kg/min (2).

With the detection of VAE, rapid aspiration of air can reduce mortality and morbidity. In sudden VAEs, the amount of aspirated air is directly proportional to mortality and morbidity (3). The frequency of VAE is reported in varying proportions depending on the monitoring methods used (4). Prudence and fast action are key to preventing morbidity and mortality in clinical situations at risk.

Air embolism is an uncommon complication in laparoscopic surgery, but can be fatal if encountered (5). After the pneumoperitoneum is formed, it may occur as a result of the progression of the operation and the transition of the gas into the opened venous system, or by accidentally introducing the gas into the vascular structure instead of the abdomen. In this case report, we aimed to present a case report of air embolism during laparoscopy and subsequent localization of the liver.

### CASE REPORT

A 51-year-old female patient underwent surgery for elective laparoscopic nephrectomy (LN) because of the presence of a common source of infection. The patient had no additional problems other than known hypertension. The preoperative laboratory values of the patient were within normal limits. After routine non-invasive monitoring (ECG, noninvasive blood pressure, pulse oximeter), anesthesia was induced with propofol 2 mg/kg, rocuronium 0.6 mg/kg and fentanyl 1 µg/kg. Anesthesia was maintained with desflurane MAC 1 and 50% FiO<sub>2</sub> oxygen-nitrogen mixture. End-tidal carbon dioxide (EtCO<sub>2</sub>) monitoring was performed.

After the left lateral decubitus position, a veress needle was placed and carbon dioxide gas was tried to be given. However, resistance was encountered. Insufflation ceased. The laparoscopy method was abandoned without the placement of the trocars and it was decided to perform nephrectomy with open access technique (Hasson technique). The patient's hemodynamic parameters were stable. After the peritoneum was opened, the patient's EtCO<sub>2</sub> level decreased to 18. Blood pressure was arterial (TA): 53/33, heart rate (HR): 40 and SpO<sub>2</sub>: 83. ST elevation was observed on the ECG monitoring. Surgery was terminated and emergency closure was started. Nephrectomy could not be performed. The patient was ventilated with 100% O<sub>2</sub>. Ephedrine 15 mg and atropine 1 mg were administered to the patient. The patient's TA and end-tidal levels recovered rapidly. 0.6 mg enoxaparin

sodium was administered subcutaneously. The patient was started to awaken with suggamadex 200 mg when TA: 127/67, HR: 97, SpO<sub>2</sub>: 99 and EtCO<sub>2</sub>: 29. The patient was extubated without any problem. The patient's saturation after extubation was around 90 with mask oxygen. The patient was taken to intensive care unit with the preliminary diagnosis of myocardial infarction (MI) and pulmonary thromboembolism (PTE).

On admission to the intensive care unit, TA: 138/78, SPO<sub>2</sub>: 93 (with oxygen), and KH: 88. The pH of the patient's blood gas was 7.35, PO<sub>2</sub>: 59 and PCO<sub>2</sub>: 34. Cardiac enzymes, D-Dimer, hemogram, biochemistry parameters, PT-INR were studied. A 12-lead ECG was obtained. T negativity was observed in V 4-5-6 on ECG. Biochemistry values were reported as troponin: 22 ng/L and CK-MB: 1.57 µg/L. The patient was consulted with cardiology clinic. Echocardiography showed no evidence of PTE. ECG changes were evaluated as nonspecific changes. D-Dimer was reported as 0 mg/L. The control troponin value was reported as 47 ng/L. MI diagnosis was ruled out. Intravenous contrast-enhanced thorax computed tomography (CT) was performed. Tomography was reported as 'PTE was not observed. There are air densities in the liver entering the gravitational area' (Figure 1). It was concluded that the patient developed air embolism. The patient had abdominal pain. She was consulted with general surgery clinic. Analgesic was not applied to the patient and a follow-up decision was made. Because of air embolism in the intestines, necrosis was thought to occur and lower-upper abdominal CT with intravenous contrast was performed. Abdominal CT showed disappearance of air densities observed in the liver (Figure 2). No pathology was observed in the bowel. Non-cardiogenic pulmonary edema was detected in the lungs. The patient's lung pathology improved and she was taken to the service for two days and discharged home without any problem.

### DISCUSSION

With the development of laparoscopic devices and technology in recent years, laparoscopy has started to play an important role in the treatment of genitourinary problems. LN was described in 1991 by Clayman et al. (6). The reasons for LN being superior to open surgery can be listed as: lower mortality, less blood loss, shorter return to daily life and better cosmetic appearance (7).

In a multicenter study of laparoscopic complications in retroperitoneal and pelvic extraperitoneal cases, the most common type of complication was vascular injury (8). Veress needle was held responsible for 18% of input injuries (9). In fact, although this needle is thinner than the trocar, it causes a higher rate of injury than the trocar.

Complications due to carbon dioxide insufflation have been reported in 2-4% of cases. Common complications are cardiopulmonary system disorders, hypercarbia and pulmonary acidosis. Gas (air) embolism is the most feared but rare complication of carbon dioxide. In the treatment of gas embolism, it is necessary to stop the insufflation and evacuate pneumoperitoneum. Rapid treatment is the most important factor determining morbidity and mortality. The patient is moved to the trendelenburg and left lateral decubitus position, which helps to move the gas bubble from the pulmonary circulation to the right heart. The patient is hyperventilated with 100% oxygen.

Transesophageal ultrasound can be used to display the air and aspirate it by a central venous catheter. Hyperbaric oxygen therapy (HBOT) should be considered especially in hemodynamic disorders, cardiopulmonary insufficiency, neurological deficit and end-organ damage (10).

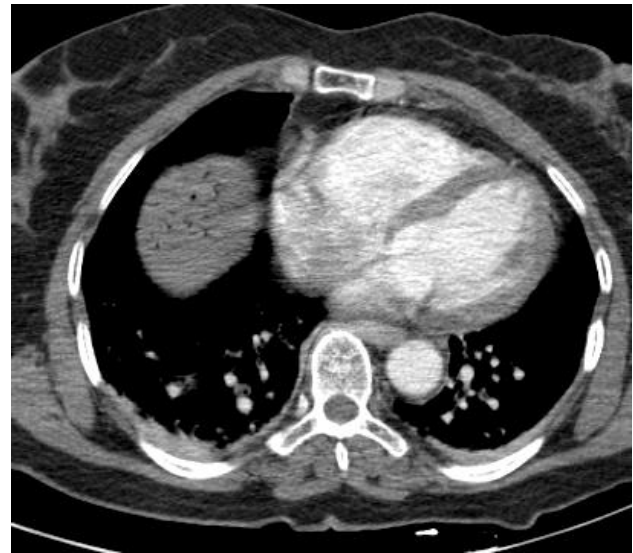In our case, VAE was diagnosed with sudden decrease in EtCO<sub>2</sub> and hemodynamic disturbance as a result of ventilation perfusion incompatibility. First, PTE and MI were ruled out. In our case, it was observed that a small amount of air accidentally delivered to the systemic circulation went to the liver which is the top organ due to the patient's position. Since air embolism was not suspected initially in the patient, central catheter was not inserted and air was not aspirated. However, since there was no massive embolism, there was no life-threatening condition and the patient's hemodynamics recovered rapidly with supportive therapy.

The aim of this case report is to consider the suspicion of air embolism in case of resistance to CO<sub>2</sub> insufflation after the placement of veress needle in laparoscopic surgery as in our case. In such a case, CO<sub>2</sub> insufflation should be stopped first and the patient should be followed closely for hemodynamics, EtCO<sub>2</sub> and blood gases for at least 5-10 minutes in terms of air embolism. If necessary, postoperative intensive care therapy may be required.

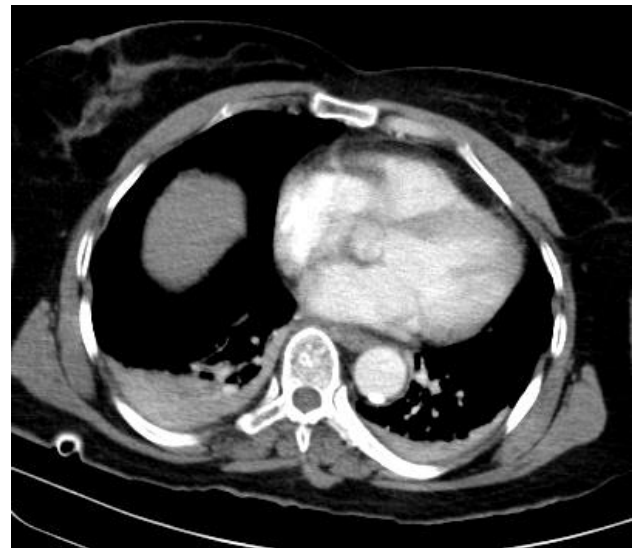
**Informed Consent:** Informed Consent was obtained from patient about case presentation.

#### REFERENCES

1. Webber S, Andrzejowski J, Francis G. Gas embolism in anaesthesia. *BJA CEPD Reviews*. 2002;2(2):53-7.
2. Adornato D, Gildenberg PL, Ferrario CM, Smart J, Frost EA. Pathophysiology of intravenous air embolism in dogs. *Anesthesiology*. 1978;49(2):120-7.
3. Mirski MA, Lele AV, Fitzsimmons L, Toung TJ. Diagnosis and treatment of vascular air embolism. *Anesthesiology*. 2007;106(1):164-77.
4. Kampen J, Koch A, Struck N. Methodological remarks on transcranial Doppler ultrasonography for PFO detection. *Anesthesiology*. 2001;95(3):808-9.
5. Hong Y, Xin Y, Yuue F, Qi H, Jun C. Randomized clinical trial comparing the effects of sevoflurane and propofol on carbon dioxide embolism during pneumoperitoneum in laparoscopic hepatectomy. *Oncotarget*. 2017;8(16):27502-9.
6. Clayman RV, Kavoussi LR, Soper NJ, Dierks SM, Meretyk S, Darcy MD, et al. Laparoscopic nephrectomy: initial case report. *J Urol*. 1991;146(2):278-82.
7. Dağgüllü M, Utanğaç MM, Bozkurt Y, Dede O, Bodakçi MN, Sancaktutar AA, et al. Our laparoscopic radical nephrectomy experiences. *Dicle Med J*. 2014;41(4):732-7.
8. Gill IS, Clayman RV, Albalá DM, Aso Y, Chiu AW,



**Figure 1.** Air densities in liver



**Figure 2.** Air densities in liver are lost, pleural fluid is increased

- Das S, et al. Retroperitoneal and pelvic extraperitoneal laparoscopy: an international perspective. *Urology*. 1998;52(4):566-71.
9. Hulka JF, Levy BS, Parker WH, Phillips JM. Laparoscopic-assisted vaginal hysterectomy: American Association of Gynecologic Laparoscopists' 1995 membership survey. *J Am Assoc Gynecol Laparosc*. 1997;4(2):167-71.
10. Topal T, Korkmaz A. Hyperbaric oxygen therapy: medical education. *Turkiye Klinikleri J Med Sci*. 2008;28(2):206-16.