

Case Report / Olgu Sunusu

Mandibulada Keratokistik Odontojenik Tümör- Nadir Bir Olgu Sunusu

Keratocystic odontogenic tumor in the mandible – an unusual case report

Anoop Kurian Mathew¹, Prashanth Shenai¹, Laxmikanth Chatra¹, KM Veena¹, Prasanna Kumar Rao¹, Rachana Vishnudas Prabhu¹

¹ Yenepoya Dental
College
Karnataka- India

Corresponding Author:
Dr. AnoopKurian Mathew

Oral Medicine & Radiology
Yenepoya Dental College
Yenepoya University
University Road
Nithyananda Nagar Post
Mangalore - 575018
Karnataka- India

Email:
drakm86@yahoo.com

Başvuru Tarihi/Received :
26-10-2012

Kabul Tarihi/Accepted:
15-01-2013

ÖZET

Keratocystic Odontojenik Tümör yüksek nüks oranı ile ağız boşluğunda meydana gelen bir lezyondur. Bu lezyonun çeneyi etkileyen diğer lezyonları taklit etme yeteneği vardır. Tümör çeşitli klinik ve radyografik şekillerde belirir. Bu makalede, bir gömülü diş ile ilişkili ve alışılmadık bir radyolojik görüntü ile prezente olan, sağ alt çenede asemptomatik bir şişlik ile başvuran 45 yaşındaki erkek hasta olgusu sunuldu.

Anahtar Kelimeler: Odontojenik tümör, keratokist, tekrar

ABSTRACT

Keratocystic Odontogenic Tumor is a lesion occurring in the oral cavity that has a high recurrence rate. This lesion has an ability to mimic other lesions affecting the jaw. The tumor has a varied clinical and radiographic presentation. This article presents a case report of a 45 year old male patient presenting with an asymptomatic swelling on the right lower jaw associated with an impacted tooth and depicts an unusual radiographic picture.

Key words: Odontogenic tumor, keratocyst, recurrence

Introduction

Keratocystic Odontogenic Tumor (KOT) defined by the WHO, as a benign, intraosseous neoplasm of dental origin, with a characteristic parakeratinized stratified squamous epithelium.^[1] It was previously known as Odontogenic keratocyst and was first described by Phillipsen in 1956.^[2] The term Keratocystic odontogenic tumor was recommended by WHO which describes its neoplastic nature. It has a slight male predilection, usually between the second and third decades of life,, it can be located anywhere in the jaws, most commonly occurring in the mandibular posterior region^[3].

The radiographic appearance varies widely, which makes diagnosis difficult. Herewith in this article, we report a case of KOT in a 45 year old male patient who presented with an asymptomatic swelling in the right lower jaw that has varied distinguishing clinical and radiological features.

Case Report:

A 45 year old male visited the department of Oral Medicine and Radiology, Yenepoya Dental College, Yenepoya University, Mangalore with a complaint of asymptomatic swelling in the left lower jaw since 1 month. He noticed the swelling one month back which gradually increased to the present size. Swelling began following a tooth ache and was associated with throbbing type of pain which aggravates upon touch and mastication. His medical and family history was noncontributory. Extra oral examination revealed presence of diffuse swelling over left lower jaw (figure 1) measuring approximately 4×3 cm in size, extending inferiorly 0.5 cm below the inferior border of mandible. Swelling was non fluctuant, non-compressible and hard in consistency.

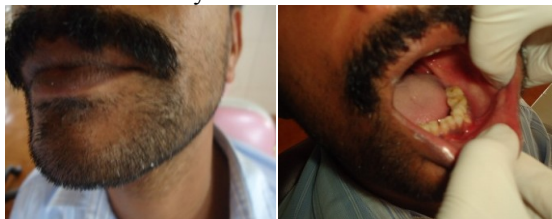

Figure 1. Asymptomatic swelling in the left mandible
Figure 2: Obliteration of left buccal vestibule

Intraoral examination revealed diffuse swelling involving left buccal vestibule extending posteriorly towards the retromolar region leading to obliteration of the left buccal vestibule (figure 2). Swelling was non tender and hard in consistency. 33 was found to be missing and there was erosion of bone in relation to 32 and 34 (figure 3) through which purulent discharge was visualized. Buccal cortical expansion was evident and there is thinning of bone lingually. Severe cervical abrasion was noted in relation to 34, 35 & 36. Aspiration revealed yellow colored fluid. On vitality test, all mandibular

teeth except 45, 46 and 47 showed no response. Considering the history and clinical examination, provisional diagnosis of radicular cyst was given.

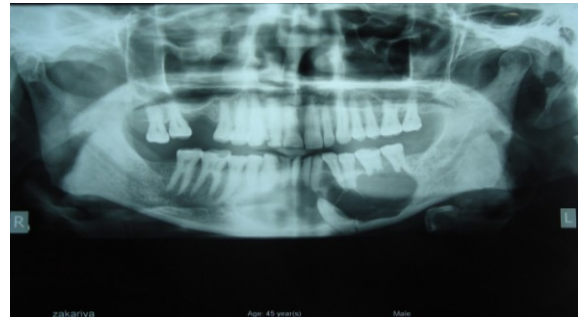

Figure 3: Panoramic radiograph reveals a well-defined hazy radiolucent lesion with superior scalloped margin with an evidence of resorption and displacement of teeth and an impacted tooth

Panoramic radiograph revealed well defined hazy radiolucent lesion involving the lower jaw (figure 4). Margins appear to be smooth, regular and non-corticated. Superior aspect of the lesion has a scalloped margin. The lesion extends from the distal aspect of 37, grows anteroposteriorly, and crosses the midline and reach till the distal aspect of 45. Displacement of teeth and resorption of roots of the teeth are evident. Presence of multiple septae within the radiolucent lesion gives a multilocular appearance. Also there is presence of tooth like radiopacity suggestive of an impacted tooth within the lesion, near the inferior border of the mandible, which is intact.

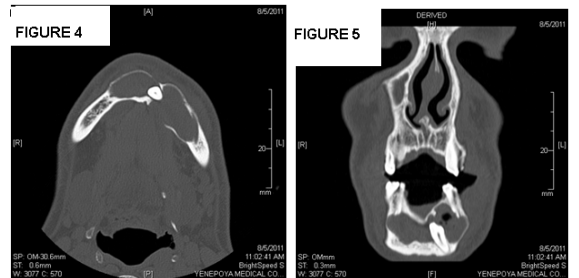


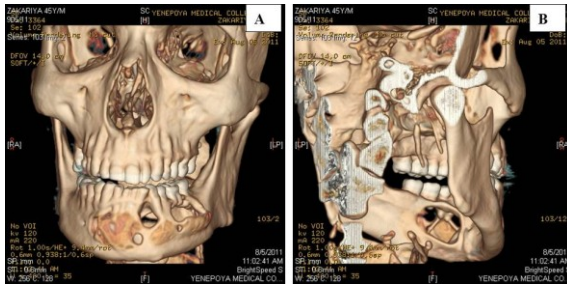
Figure 4: CT axial view showing the extent of the lesion with the evidence of an impacted tooth and perforation of lingual cortical plate

Figure 5: CT coronal view of the extensive lesion showing superoinferior extension

Computed tomographic (CT) axial view showed a well-defined hypodense area involving the mandible with its buccolingual and anteroposterior extension (figure 5) crossing the midline. Buccal cortical plates appear to be intact but there is perforation of lingual cortical plate on the left side of the jaw. There is also an evidence of hyperdense structure in the centre suggestive of an impacted tooth. Similarly, coronal (figure 6) and sagittal views showed the superoinferior and anteroposterior extension of the hypodense lesion (figure 7A & 7B).

3D view showed the exact extension of the lesion with an evidence of through and through perforation (figure 8A & 8B). On the basis of history, clinical and radiographic examination a final diagnosis of Keratocystic odontogenic tumor was

made. Here, seeing the extent of the lesion a surgical excision was planned. Surgical removal of the tumor was performed along with partial mandibulectomy and the specimen was sent for histopathological examination.



Figures 6A & B: 3 Dimensional representations showing the extensive lesion with buccal and lingual cortical plate perforations and, bony septa within the lesion

Histology showed parakeratinized stratified squamous epithelium largely of a uniform thickness overlying a fibrous connective tissue showing focal areas of severe inflammation. Epithelial connective tissue interface is flat with basal cells of epithelium showing palisading appearance. Areas also showed proliferation and rete ridge formation with loss of surface keratinization. Histopathology was suggestive of infected odontogenic keratocyst (figure 9). Enucleation of the lesion with partial resection of the mandible followed by surgical plating was done. Patient was reviewed after 6 months, reported with no recurrence.

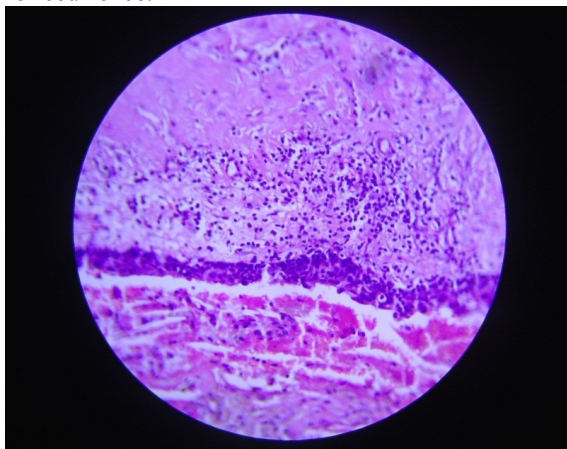


Figure 7: Histopathologic picture showing parakeratinized stratified squamous epithelium and basal cells of epithelium showing palisading appearance (10X zoom)

Discussion:

KOT is a benign unicystic or multicystic, intraosseous tumor of odontogenic origin. KOT form approximately 11% of all jaw cysts and they have a very high recurrence rate. The reason for the high recurrence rate is due to the proliferation of islands of odontogenic epithelium that may be present in the wall giving rise to satellite microcysts. It has been reported that KOT most commonly occur between second and third decade of life but may be diagnosed at any age.^[3] It was reported that the incidence was highest in the older age groups, and a

decade younger in woman than in men.^[4] The mandible is involved more frequently than the maxilla, the percentage of KOT occurring in the mandible ranges from 65-83% of cases.^[5] The tumor can occur at any site in the mandible but most of the lesions arises in the posterior body, angle and ascending ramus of the mandible.^[4] The lesion is symptomless unless infected. They sometimes form around an unerupted tooth; sometimes adjacent teeth may be displaced. The present case was a 45 year old male patient with an asymptomatic swelling in the mandible with an evidence of an unerupted tooth.

Unlike other lesion, the epithelium of KOT appears to have an innate growth potential. This difference in growth mechanism gives it a different radiographic condition. Conventional radiographs such as panoramic radiographs may be adequate in most of the cases to determine the location and estimate the size of KOT. Advanced imaging modalities such as computerized tomography may be required to assess the full extension of the lesion.^[5]

KOTs occur as well defined lesion which may be unilocular or as multilocular.^[6] Most of the lesions are unilocular and often appears with smooth and regular borders. In this case, panoramic radiograph showed a well-defined multilocular hazy radiolucent lesion with superior scalloped border crossing the midline in the mandible with the presence of multiple septae making the lesion multilocular. The presence of septae within the bony cavity is the most striking feature of ameloblastoma, which serve to produce partial loculation of the cavity.^[7] Scalloping of the sclerotic margin of the lesion that extend between the roots of the teeth is a characteristic feature of traumatic bone cyst. Here, scalloping of the margins was seen over the anterior part of the lesion which is a distinguishing feature. Since the lesion is associated with an impacted tooth, dentigerous cyst should also be considered in the differential diagnoses.^[7] Here the lesion emerges from the middle third root portion of the impacted tooth, and not from the cemento-enamel junction of the tooth, which is most frequently seen in case of a dentigerous cyst. The lesion here extends from the posterior aspect of 37 and is not localized surrounding the impacted tooth.

On intraoral examination, thinning of lingual cortical plate with increased fluctuation was felt, suggestive of perforation of the cortical plate. The exact dimension of the lesion and perforation of cortical plates were visualized by CT images.

Parakeratotic variety has a more aggressive clinical presentation and is more frequent (80%) than the orthokeratotic variants.^[8] Present case is a parakeratinized variety with areas of proliferation and rete ridge formation, which has a more chance for recurrence.

The main goal of treatment is to reduce the risk of recurrence and morbidity of extensive resection.^[9] Treatment modalities such as

decompression, simple enucleation with or without curettage and resection have been employed in the treatment of KOT.^[10] Here enucleation along with partial resection of the mandible has been carried out.

Conclusion

Most of the patients with KOT are asymptomatic which are discovered incidentally during radiographic interpretation. Histopathology is must in the diagnostic process of KOT although clinical and radiographic appearance is highly suggestive. CT scan is usually performed to assess the full extent of the lesion. A long term follow up is required since it has an aggressive and recurrent nature.

References

1. Philipsen HP. Keratocystic odontogenic tumor. In: Barnes L, Eveson JW, Reichart P, Sidransky D, eds. World Health Organization classification of tumors: pathology and genetic of head and neck tumors. Lyon: IARC Press. 2005: 306–7.
2. Philipsen HP. Om keratocystedr (Kolesteratomer) and kaeberne. Tandlaegebladet 1956; 60:963–71.
3. Myoung H, Song HP, Hong SD, Lee JI, Lim CY, Choung Ph, et al. Odontogenic keratocyst: review of 256 cases for recurrence and clinicopathologic parameters. Oral Surg Oral Med Oral Pathol Oral Radiol Endod 2001; 91(3):328-333.
4. Oda D, Rivera V, Ghanee N, Kenny MA, Dawson KH. Odontogenic keratocyst: the Northwestern USA experience. J Contemp Dental Pract 2000; 1(2):1-7.
5. Asokan G, Jeelani S, Parthiban J, Prabhushankar K., Prakash C, Shankar K.A. .Keratocystic Odontogenic Tumor – A Case Report And Review Of Literature. Int J Dent Case Reports 2012; 2(1): 87-91.
6. Gupta A, Rai B, Nair MA, Bhut MK. Keratocystic odontogenic tumor with impacted maxillary third molar involving the right maxillary antrum: An unusual case report. Indian J Dent Res 2011; 22:157-60.
7. H. M. Worth. Principles and Practice Oral Radiologic Interpretation. Year Book Medical Publishers Inc. Chicago.1988.
8. Cakur B, Miloglu O, Yolcu U, Goregen M, Gursan N. Keratocystic odontogenic tumor invading the right maxillary sinus: A case report. J Oral Sci 2008; 50:345- 9.
9. Leite TC, Meirelles V, Janini ME. Odontogenic Keratocystic Tumor: Clinical and Histopathologic Retrospective Study Based on the New WHO Classification. Int. J. Odontostomat 2011; 5(3):227-234.
10. Yildirim G, Ataoglu H, Kalayci A, Ozkan BT, Kuvuk K, Esen A. Conservative Treatment Protocol for Keratocystic Odontogenic Tumour: a Follow-up Study of 3 Cases J Oral Maxillofac Res 2010;1(3);e7:1-11.