

**Case Report / Olgu Sunusu**

**Torsion of a Wandering Pelvic Spleen; Acute Abdomen in a Child**

**Çocukta Akut Batın; Wandering Pelvik Spleen Torsiyonu**

Metin Gunduz, Adnan Abasiyanik

<sup>1</sup>Department of Pediatric Surgery, Konya Education and Research Hospital, 42080 Konya,

<sup>2</sup>Department of Pediatric Surgery, Meram Medical School of Konya University, 42080 Konya, Turkey

**Corresponding Author:**

Dr. Metin Gündüz  
Konya Education and  
Research Hospital  
42080 Konya –TURKEY

Tel: (90) 332 223 67 09

Fax: (90) 332 323 67 23

E-mail:  
drmetingunduz@yahoo.com

Başvuru Tarihi/Received :  
26-03-2012  
Kabul Tarihi/Accepted:  
17-04-2012

**ÖZET**

Wandering spleen çok yaygın olmayan hayatı tehdit eden bir klinik tablodur. Karın ağrısı, hassasiyet ve karın orta hatta kitlesi olan 11 yaşında kız hasta opere edildi. Preoperatif dönemde yapılan bilgisayarlı tomografide uzun pedikülü etrafında saat yönünde 720° torsiyone olmuş, büyük, iskemik gezgin dalak tespit edildi. Detorsiyon sonrası kanlanma düzelmedi ve splenektomi yapıldı.

**Anahtar kelimeler:** Wandering spleen, dalak torsiyonu, akut karın

**ABSTRACT**

Wandering spleen is an uncommon clinical entity. Acute splenic torsion of wandering spleen is a potentially fatal surgical emergency case, and its correct and early identification continues to represent a challenge especially in children. A 11 years old girl was taken to the operative room for an explorative laparotomy due to abdominal pain, tenderness, and a midabdominal mass. Preoperative computerise tomography showed a torsion of an enlarged wandering pelvic spleen which was in a serious ischemic suffering due to a 720 degrees clock torsion around its exceptionally long pedicle. Splenectomy has been the treatment for symptomatic wandering spleen as in our case.

**Key words:** Wandering spleen; spleen torsion; acute abdomen

## Introduction

Wandering spleen is an uncommon clinical entity. Acute splenic torsion of wandering spleen is a potentially fatal surgical emergency case, and its correct and early identification continues to represent a challenge (1) especially in children. Causes for spleen hypermobility may be hormonal changes during pregnancy or failure of fusion of the dorsal peritoneum (1). Congenital absence of splenocolic, splenorenal, or splenophrenic ligaments, which points to the failure of the dorsal mesogastrium to fuse with the posterior abdominal wall during the second month of embryogenesis, is the best explanation for the pathophysiology of wandering spleen (2). Wandering spleen is predisposition for torsion (3). The aim of this report is to increase clinical awareness of torsion of wandering spleen in childhood and the need of a rapid diagnosis.

## Case

A 11 year-old girl was admitted to the hospital with intermittent abdominal pain of 2 month's duration and abdominal distension. On admission, her axillary temperature was 39.2°C, pulse was 102 beats per minute, and blood pressure was 110/70 mm Hg. Physical examination showed a tense abdomen with generalized pain and a midabdominal mass. Ultrasound demonstrated enlarged spleen in abnormal position and minimal free fluid in the peritoneal cavity. The CT scan showed a torsion of an enlarged (16x12x5cm) wandering pelvic spleen compressing surrounding bowel loops, and indicating partial or total infarction

White blood cell count was  $14.8 \times 10^3/\mu\text{L}$ , hemoglobin level was 10.0 g/dL, and platelet count was  $107 \times 10^3/\mu\text{L}$ . The patient underwent a laparotomy, and a 720° splenic torsion was found (Fig 1). After detorsion, it did not regain its normal vascularity, and splenectomy was carried out. Histopathologic examination demonstrated hemorrhagic necrosis of the spleen. Postoperative recovery was uneventful.

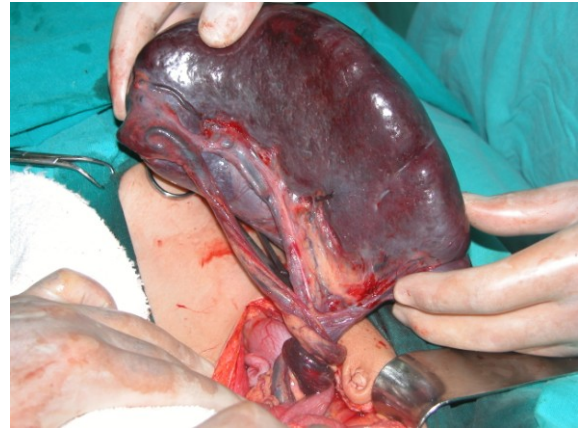


Figure 1 Splenic torsion of 720°

## Discussion

A wandering spleen is a rare entity. Acute, chronic or intermittent torsion of the spleen is the major complication of an abnormally mobile spleen. Due to intermittent abdominal pain of 2 month's duration and abdominal distension we think that our case had chronic torsion of spleen. The increased mobility of the spleen results from absence or laxity of splenocolic, splenorenal, or splenophrenic ligaments, that normally anchor the spleen in its normal position (4). As shown in figure 1, splenocolic, splenorenal, and splenophrenic ligaments were absent. The clinical presentation of a wandering spleen can be variable. Affected patients may be asymptomatic and this condition may be discovered incidentally as an

abdominal mass on physical examination or on imaging for other unrelated reasons. Patients may have mild intermittent abdominal pain due to splenic congestion with intermittent torsion and spontaneous detorsion, or may present with an acute abdomen due to torsion of the splenic pedicle with subsequent infarction. With acute torsion, the condition can be confused with appendicitis or ovarian torsion. Other clinical symptoms include nausea, vomiting, fever, leukocytosis, peritoneal signs, and a palpable mass in the abdomen or pelvis (5). Splenic shadow absence may suggest the diagnosis at radiography (6). For the definitive diagnosis of a wandering spleen ultrasonography or CT is typically required to confirm the diagnosis (7). We confirmed the diagnosis wandering pelvic spleen with CT . Splenectomy has been the treatment for symptomatic wandering spleen as in our case. With increasing appreciation for the importance of the spleen in reticuloendothelial function, there has been renewed interest in splenopexy. After detorsion, if the spleen regains its normal appearance, splenopexy can be performed with a retroperitoneal pouch (8). Detorsion and splenopexy may be considered a reasonable surgical option even in these patients, when there is no evidence of infarction and thrombosis (9). However, in cases of splenic torsion with infarction, splenectomy is required. Attention to vaccination for encapsulated organisms should be performed, usually 1 to 2 weeks after splenectomy (9). We consulted our patient with pediatric haematology department. Although wandering torsion of spleen is a rare condition it must kept

in mind in patients with abdominal mass and pain as reported case.

## References

1. Ben Ely A, Zissin R, Copel L, et al. The wandering spleen: CT findings and possible pitfalls in diagnosis. *Clin Radiol* 2006;61(11):954-8.
2. Taori K, Ghonge N, Prakash A. Wandering spleen with torsion of vascular pedicle: early diagnosis with multiplaner reformation technique of multislice spiral CT. *Abdom Imaging* 2004;29(4):479-81.
3. Nemcek AA Jr, Miller FH, Fitzgerald SW. Acute torsion of a wandering spleen: diagnosis by CT and duplex Doppler and color flow sonography. *AJR Am J Roentgenol*. 1991 Aug;157(2):307-9.
4. Sheflin JR, Lee CM, Kretchmar KA: Torsion of wandering spleen and distal pancreas. *AJR Am J Roentgenol* 1984, 142:100-101
5. Herman TE, Siegel MJ: CT of acute splenic torsion in children with wandering spleen. *AJR Am J Roentgenol* 1991, 156:151-153.
6. Swischuk LE, Williams JB, John SD. Torsion of wandering spleen: the whorled appearance of the splenic pedicle on CT. *Pediatr Radiol* 1993 23:476-477
7. Dillman JR, Strouse PJ.. The "wandering" spleen. *Pediatr Radiol*. 2009 10.1007/s00247-009-1376-5
8. Ida Di Crosta, Alessandro Inerra, Carlos Pueyo Gil, Mara Pisani, Antonio Ponticelli. Abdominal pain and wandering spleen in young children: the importance of an early diagnosis *J Ped. Surgery* (2009) 44, 1446-1449
9. Soleimani M, Mehrabi A, Kashfi A, Fonouni H, Büchler MW, Kraus TW: Surgical treatment of patients with wandering spleen: report of six cases with a review of the literature. *Surg Today* 2007, 37(3):261-9.