

Case report / Olgu sunusu

**A case report of Marfans Syndrome patient with epilepsy-A Rare
concomitance**
Epilepsi ile birlikte Marfan Sendromu olgu sunusu- nadir bir birliktelik

Deepa Dsouza¹, Subhas Babu G¹, Shishir Ram Shetty¹, Preethi Balan¹

¹Department of Oral
Medicine and
Radiology, AB Shetty
Memorial Institute of
Dental Sciences, Nitte
University.

Mangalore / India

İletişim / Corresponding
Author:

Deepa Dsouza

Department of Oral
Medicine and Radiology
AB Shetty Memorial
Institute of dental
Sciences, Nitte
University
Mangalore / India

Phone number:
+918951362580

Email:
dr.deepasdsouza@live.c
om

Received / Başvuru
Tarihi:
28-07-2011

Accepted / Kabul
Tarihi:
20-02-2012

Özet

Marfan Sendromu, değişken ekspresyon durumlarının olduğu otozomal dominant kalıtmımlı bir bağ dokusu bozukluğudur ve klasik biçimiyle, iskelet, kardiyovasküler ve oküler anomalileri kapsar. Bu fibrillin genindeki mutasyon bir kusur olarak atfedilir. Sendrom hafiften şiddetliye geniş bir ifade yelpazesine sahiptir. Bazen semptomlar çok belirsizdir, sadece birkaç semptom oluşabilir. Çoğu durumda hastalık yaşla birlikte ilerler, bağ dokusunda değişikliklerin belirmesi ile Marfan Sendromu belirginleşir. Bugüne kadar bildirilen vakaların çoğu kalp-damar anormallikleri ile ilişkilidir. Biz epilepsi ile ilişkili Marfan Sendromu olgusunu sunduk

Anahtar kelimeler: Marfan Sendromu, Araknodaktili, Mavi sklera, Epilepsi.

Abstract

Marfans Syndrome is a disorder of the connective tissue inherited as an autosomal dominant condition of variable expression and its classical form comprises of skeletal, cardiovascular and ocular abnormalities. It is attributed as a defect in the mutation in the fibrillin gene. The syndrome has a wide range of expression from mild to the severe forms. Sometimes the symptoms are so mild that only few of the symptoms occur. In most cases, the disease progresses with age and symptoms of Marfans Syndrome become noticeable as changes in the connective tissue occur. Most of the reported cases so far are associated with cardiovascular abnormalities. We report a case of Marfans Syndrome associated with epilepsy.

Key words: Marfans Syndrome, Arachnodactly, Blue sclera, Epilepsy.

Introduction:

Marfans syndrome is a variable autosomal dominant disorder of the connective tissue.¹ It was first described by Marfan in 1896.² Approximately 85% of the case are familial with the rest arising as a result of new mutations.³ Mutations in the FBN1 is associated with a broad spectrum of phenotypes.⁴ Marfans syndrome may affect cardiovascular, central nervous system, musculoskeletal, pulmonary, ocular and integumentary systems.⁵ The diagnosis is commonly considered in young patients with tall, thin body habitus, long limbs, arachnodactyly, pectus deformity and scoliosis. Other findings are high arched palate with crowding of teeth.¹ According to Ghents classification 1 major and 4 minor features supports the diagnosis in this case.⁴ We report a case of Marfans syndrome with similar features and CNS findings.

Case report:

A 14-year-old female patient reported to the department with a complaint of forward placement of teeth. She was aware of the condition following the eruption of the permanent teeth causing severe esthetic discomfort. Patient presented with a history of epileptic seizures that were occasional and transient. The patient was on an ayurvedic medication for the same for epilepsy and had no episodes of seizures since the past one year. She also reported of a history of myopia (near sightedness) which was corrected with spectacles. She was wearing them since young ages.

The patient was well oriented with time, place and was cooperative during the clinical examination. On examination, skeletal findings like tall stature with slender limbs, long narrow face (leptoprosopic), long narrow head (dolicocephalic), thin body habitus with increased arm span to height ratio, long slender limbs, long fingers and toes (arachnodactyly),



Figure 1a –Photograph showing Tall stature with thin body habitus

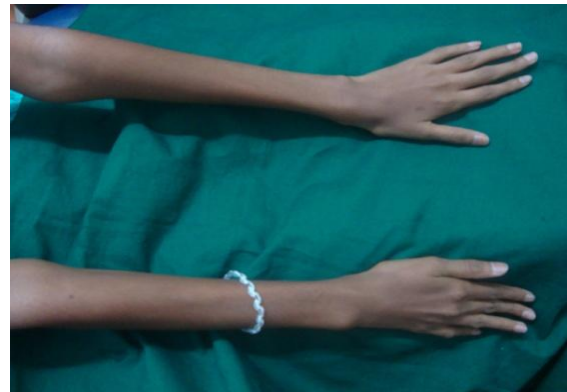

Figure 1b- Long slender upper limbs and fingers

deformities of the chest (pectus carinatum), abnormal curvature of the spine (scoliosis), joint hypermobility, flat feet, downward slanting palpebral fissures, malar hypoplasia were observed (Fig. 1a & 1b). Walker sign (wrist) and Steinberg sign (thumb) was positive (Fig 2a & 2b).

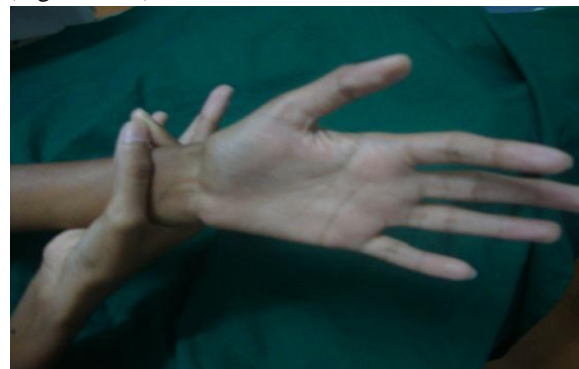

Figure 2a- Photograph showing wrist sign (Walker Sign positive)

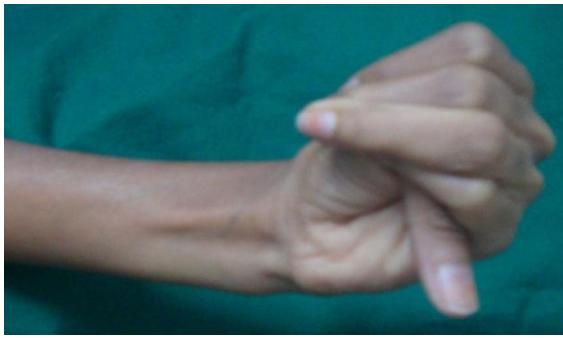

Figure 2b- Photograph showing Steinberg's sign

Ocular findings under slit lamp examination performed by a qualified ophthalmologist revealed ectopia lentis (subluxation of the lens) that was bilaterally symmetrical and upwards, blue sclera (Fig. 3).

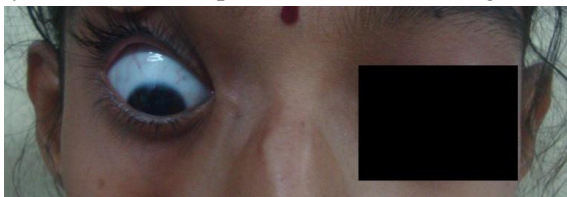


Figure 3 –Photograph showing blue sclera

Qualified cardiologist evaluated the patient and a electrocardiography was carried out which revealed no abnormalities. Oral findings were microstomia, incompetent lips, proclination of upper anteriors with high arched palate (Fig.4).

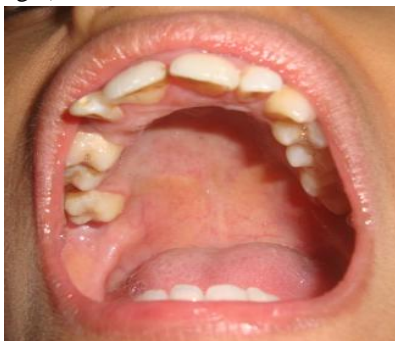

Figure 4-Photograph showing high arched palate.

Orthopantomogram revealed the presence of impacted canine in the maxilla and dilacerated premolar in the mandible (Fig 5). Based on these clinical presentations and opinions from the medical professional a provisional diagnosis of Marfans syndrome associated with epilepsy was constituted. Oral prophylaxis was carried out and orthodontic treatment was initiated for the correction of malocclusion.

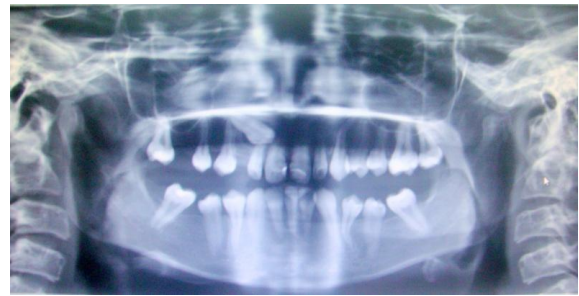


Figure 5-Orthopantomogram showing impacted canine in the maxilla and dilacerated premolar in the mandible.

Discussion:

Marfans syndrome (MFS) is a variable autosomal dominant disorder of the connective tissue.¹ It was first discovered by Antonie Marfan (French pediatrician) in the year 1896 as dolicoostenomelia which means long limbs. It was first seen in a 5-year-old patient, later it was referred as MFS.² It is caused due to mutation in the FBN1 gene located on chromosome 15, band q15-q23 which codes for the connective tissue fibrillin.³ The incidence is 1 in 9800 births and 27% of cases occur due to new mutations.¹ Mutations in FBN1 gene have been associated with a broad spectrum of phenotypes.⁴ More than 135 new mutations have been identified in the FBN1 gene.⁵ Neonatal MFS constitutes 14% of the total cases. The presentation in adults and adolescents is well known.⁶ Fibrillin-1 forms an important component of microfibrillin. It is a glycoprotein synthesized as a precursor that is processed and secured in the extracellular matrix (ECM). It polymerises to form microfibrillin and helps to stabilize the latent transforming growth factor- β binding protein (LTBPs) in the ECM. LTBPs hold the TGF- β (TGF- β) in inactive stage. A failure of interaction between fibrillin-1 and LTBPs may result in excess of TGF- β signaling. Most Fibrillin-1 mutations are a missense, suggesting a dominant negative effect on the microfibrillar assembly.¹ Fibrillin-1 is essential for the formation of extracellular matrix and maintenance of elastin fibres. Elastin fibres are found in the aorta, ligaments and ciliary zones of the eyes and these areas are the most affected.⁷

Table:1 Criteria for Diagnosis of Marfan Syndrome(1996 Ghent classification system)

System Affected	Major Criteria	Minor Criteria
Cardiovascular system	Dilatation of the ascending aorta, with or without aortic regurgitation, involving at least the sinuses of Valsalva Dissection of the descending aorta	Dilatation or dissection of the descending thoracic or abdominal aorta before 50 years of age Dilatation of a main pulmonary artery before 40 years of age Mitral valve prolapse with or without mitral valve regurgitation Calcification of the mitral annulus before 40 years of age
Musculoskeletal system	Scoliosis with a curvature greater than 20° or spondylolisthesis Pectus carinatum Pectus excavatum requiring surgery Acetabular protrusion Reduced upper-to-lower segment ratio, or arm span-to-height ratio greater than 1.05 Wrist and thumb signs Reduced extension of the elbow (< 170°) Medial displacement of the medial malleolus causing pes planus	Pectus excavatum of moderate severity Joint hypermobility Highly arched palate with crowding of teeth Abnormal facial appearance (dolichocephaly, malar hypoplasia, enophthalmos, retrognathism, down-slanting palpebral fissures)
Central nervous system	Lumbosacral dural ectasia at CT or MR imaging	None
Pulmonary system	None	Spontaneous pneumothorax Apical blebs
Ocular system	Ectopia lentis	Abnormal flat cornea Increased axial length of the globe Hypoplastic iris or hypoplastic ciliary muscle causing decreased miosis
Integumentary system	None	Striae atrophicae Recurrent or incisional hernia

Abnormalities in protein synthesis causes a myriad of distinct clinical problems of which the musculoskeletal, cardiac and ocular problems predominate.⁸ There is a striking intrafamilial and individual variability in the clinical manifestations of MFS, variability that is suggestive of some phenotype and genotype correlation.⁷ The severe end of the clinical contiguum is defined as a rapidly progressive form that is present at birth and is associated with functional impairment and death in early childhood.⁴ Diagnosis is further complicated by the age dependency of symptoms and signs, which leads to a changing clinical picture in younger patients who are suspected with the disorder but do not fulfill the clinical diagnostic criteria should be offered repeated clinical evaluations.⁹ The diagnosis of MFS was based on the Berlin classification (1986) and was later revised as the Ghent classification in 1996. The presence of 2 major features and 1 minor feature or the presence of 1 major and 4 minor features supports the diagnosis of MFS because of the presence of ectopia lentis and musculoskeletal abnormalities. (Table:1)⁷ This case report satisfies the criteria required to support the diagnosis of MFS. Rare instance of neurological findings such as epilepsy have been reported.⁸ On rare events association of mental retardation and lumbosacral meningocele has also been reported.⁹ Vascular abnormalities can be a cause of cerebral and spinal ischemia/haemorrhage events involving the brain/spinal cord are estimated in 10-20% of the patients in MFS.¹² Since there is the risk of the offsprings inheriting the genetic predisposition to the disorder parents should be counseled well in advance.⁴ New method of diagnosis can include investigation of mutation analysis (FBN1 gene). As of 1995, the life expectancy of those affected with the syndrome has increased to 72 years, up from 48 years in 1972, which is attributed to the new surgical techniques, improved diagnosis and newer techniques of medical treatment.¹³ Advancement of research in MFS holds support of further improvements in the future.

REFERENCES:

- 1) John CS. Marfans syndrome: Clinical diagnosis and management. *Eu J Hum Genet* 2007; 15:724-33.
- 2) Goh KL, Hassan Z, Tan CT. Infective endocarditis in Marfans syndrome. *Singapore Med J* 1986;5:46-9.
- 3) Gorlin RJ, Cohen MM, Levin LS. Syndromes of the head and neck, 3rd edition, Oxford University Press ,267-72.
- 4) Robert AM, Michael TG, Evelyn B, Bruce TG, Maureen Johnson et al. Mutiple molecular mechanisms underlying subdiagnostic variants of marfans syndrome. *Am j Hum Genet* 1998;63:1703-11.
- 5) Hong IH, Jon BS, Imaging of Marfans syndrome: Multisystemic manifestations. *Radiographics* 2007;27:981-1004.
- 6) Fenetta P, Sukanya G. Neonatal Marfans Syndrome- A case report. *Curr Pediatric Res* 2010;14:143-44.
- 7) Judge DP, Dietz CH. Marfans Syndrome. *Lancet* 2005;366:1-21.
- 8) Goenka S, Mehta AV. Petit mal seizure in a child of Marfans syndrome. *Tenn Med* 1999;92(2):53-4.
- 9) Chu NS. Marfans syndrome and epilepsy: report of two cases with review of literature. *Epilepsia* 1983; 24(1):49-55.
- 10) Rajendra R, Sivapathasundharam B. Shafer's textbook of oral pathology. 5th.Elsevier, 958-60.
- 11) Rangashetty CU, Karnath MB. Clinical signs of Marfans syndrome. *Hospital physician* 2006:33-38.
- 12) Robert JW, Zanferarri C, Oppenheice S. Complications of Marfans syndrome-A Retrospective hospital study. *Stroke* 2002; 33:680-84.
- 13) Jaiswal S et al Marfans syndrome with aortic valve endocarditis. *KMUJ* 2003;2:230-33.