

Case Report / Olgu Sunusu

Bezold's Abscess Secondary to Chronic Otitis Media: A Case Report

Kronik Otitis Mediaya Bağlı Bezold Absesi : Olgu Sunumu

Abdullah Onur Goksel¹, İlhan Topaloglu², Yavuz Atar³

¹ Department of
Otorhinolaryngology,
Kastamonu Dr. Munif
Islamoglu Government
Hospital, Kastamonu,
Turkey.

² Department of
Otorhinolaryngology Head
and Neck Surgery, Yeditepe
University Hospital,
Istanbul, Turkey

³ Department of
Otorhinolaryngology,
Okmeydanı Training and
Research Hospital, Istanbul,
Turkey.

Corresponding Author:

Uzm. Dr. Abdullah Onur
GÖKSEL

Camikebir Mh. Mevlana Sk.
No:6 D:3 37400 Taşköprü /
Kastamonu, Turkey

E-mail:

onurgoksel@yahoo.com

Tel: 0090-3664174810

Fax: 0090-3664173902

Başvuru Tarihi/Received :

11-12-2013

Düzeltilme Tarihi/Revised:

28-12-2013

Kabul Tarihi/Accepted:

09-01-2014

Abstract

Bezold's abscess is a very rarely seen complication of chronic suppurative otitis media and mastoiditis. Its diagnosis is significant. Bezold's abscess was detected in a 16-year-old male patient who was admitted to our clinic, and the diagnosis was confirmed by surgery. The patient was discharged after postoperative recovery. We report this case and review the literature regarding Bezold's abscess.

Keywords: Otitis media, suppurative, mastoiditis, abscess, complication.

Özet

Bezold absesi, kronik süpüratif otitis medianın ve mastoiditin çok nadir bir komplikasyonudur. Tanınması önemlidir. Kliniğimizde yatan 16 yaşındaki bir erkek hastada Bezold absesi saptandı ve hastanın operasyonu sırasında da tanı doğrulandı. Postoperatif düzelme ile hasta taburcu edildi. Biz bu vakayı sunduk ve bu olgu nedeniyle Bezold absesi ile ilgili literatürü gözden geçirdik.

Anahtar Kelimeler: Otitis media, süpüratif, mastodit, abse, komplikasyon.

Introduction

Bezold's abscess was first defined by the German otolaryngologist Friedrich Bezold. In a cadaver work-up, Bezold reported a suppuration extending from the medial side of the mastoid process to the digastric incisures, and he indicated that this suppuration spread down the neck, the facial plans of sternocleidomastoideus (SCM), and the digastric muscles, extending around large vessels, the retropharyngeal area, the larynx, the mediastinum, and even the muscles of the vertebral column.^[1-5]

Bezold's abscess must be kept in mind even though it is a rare complication. The diagnosis is often made late because this event is not generally recognized.^[6] The abscess evolves over time by the spread of the suppuration into the deep tissues by the erosion of the mastoid.

The incidence of Bezold's abscess is now very rare because of the use of antibiotics.^[3,7-9] Doan et al.^[10] reported seeing 27 cases of Bezold's abscess between 1966 and 2001.^[10] Uchida et al.^[11] reported 18 Bezold's abscess cases between 1960 and 2002. Coalescent mastoiditis developed in 50% of otitis media cases in the beginning of the 20th century, while 20% of patients suffering from mastoiditis developed subperiosteal abscess at the time when Bezold was working.^[5]

The development of Bezold's abscess is usually slow. It may develop after weeks or even months.^[11] It can hardly be palpated because it is a deep neck abscess.^[12] Fever, ear pain, ear discharge, swelling at the neck, movement disability, or neck pain are among the symptoms. Bezold's abscess can be fatal if it spreads to the central nervous system.^[11] The treatment is urgent mastoidectomy and antibiotic therapy.^[1,11]

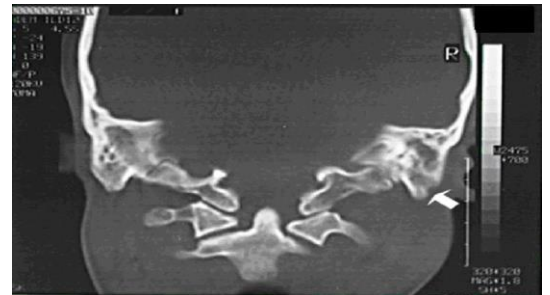
We report a Bezold's abscess case, secondary to left chronic suppurative otitis media, on whom we performed surgery.

Case report

A 16-year-old boy who suffered from ear discharge for approximately 6 years was treated with oral antibiotic therapy and locally acting ear drops containing antibiotics. His symptoms regressed temporarily, but he experienced recurrent exacerbations. The patient was taken to a hospital close to his home, diagnosed with chronic otitis media, and treated medically as an inpatient. The patient was referred to our clinic after a second admission because his condition had not improved.

The patient's general status was good and his consciousness was clear at the time of admission to our clinic. Extreme fatigue was detected. A mild fever was present. Upon examination, the left ear was normal. A purulent and foul-smelling discharge from the right ear was detected. Edema on the external auditory canal and a polyp filling the external auditory canal of the right ear were also detected. The patient held his head leaning to the right, and his neck movements were extremely restricted. Extreme tenderness by palpation and mild swelling on SCM were present. Examinations of the remaining body systems were normal.

The patient's complete blood count showed leukocytosis. Other routine tests were normal. Computed tomography showed a smooth contoured round area of destruction over the mastoid, indicative of right chronic mastoiditis with involvement of the right temporal bone (Figure 1).



Şekil 1 CT of temporal bone: Erosion of the mastoid apex and mild bulging of the right neck are visible

The patient was operated on urgently because Bezold's abscess secondary to chronic otitis media was suspected. Retroauricular incision was performed. Suppuration, polyp, and granulation tissue on the middle ear and

mastoid were detected during the operation. Cortical destruction on the adhesion point of SCM with the mastoid bone and suppurative collection throughout the SCM fibers were detected. Therefore, the diagnosis of Bezold's abscess was confirmed during surgery. Pathologic tissues in the middle ear and mastoid were removed. Radical mastoidectomy was performed. In addition, the suppuration was cleared. The debridement and irrigation of the abscess were carried out by way of the retroauricular incision.

No other neck incision was needed for the procedure. Ceftriaxone, a third generation cephalosporin, was applied intravenously for 15 days in the postoperative period. General status improved during this period. The movement disability and the neck pain got better. The tenderness on SCM disappeared. The patient was discharged. At the end of two years, the status of the patient's cavity secondary to mastoidectomy was relatively good. Postoperative controls were performed twice a month in the first year and three times a month in the second year.

Discussion

Abscesses resulting from mastoiditis are classified into three groups according to their extensions: subperiosteal abscesses, zygomatic abscesses, and Bezold's abscesses.

Subperiosteal abscesses are formed by lateral extension of suppuration; these are seen most commonly.^[9,13] Zygomatic abscesses are formed by extension of the suppuration into the zygoma root; these are seen least commonly. Bezold's abscesses are formed by extension of the suppuration from the inferior portion of the mastoid to the neck.^[9]

The digastric incisure is the weakest part of the mastoid.^[12] That's why the suppurative process erodes the mastoid cortex around the digastric ridge area and extends between the digastric and SCM during the process of evolution of Bezold's abscess. The adhesion point of neck muscles on the mastoid bone makes a tight barrier and, therefore, the

suppuration eroding the mastoid cortex cannot reach to the superficial area by means of this barrier. That's why involvement of the skin is not seen in Bezold's abscess except in a very few cases.^[9,11,14]

The suppuration could be deep and might not be recognized at first examination. Therefore, an early diagnosis could be hard to make.^[7,11,12] A swelling can appear under SCM in the course of time by the extension of involvement. This is characteristic of Bezold's abscess.^[9,11] Inflammation can expand to the tunica of great vessels in the neck, larynx, and mediastinum and to the muscles of the vertebral column and, from these areas, to the retropharyngeal region. It can also expand to the posterior triangle of the neck, the axilla, or even the suprasternal space (Burn's space) and finally to the opposite neck by following the subclavian artery.^[5,7-9,12]

In a trial in Japan, chronic suppurative otitis media with or without cholesteatoma was the most common cause. The risk is higher in cases with cholesteatoma.^[1] Also, cases secondary to acute otitis media and coalescent mastoiditis are seen but are very rare. The symptoms of patients with otitis media can regress with antibiotic therapy, but the disease may not be eradicated from the mastoid because of the blockage of drainage, depending on the mucosal thickening and formation of granulation tissue on the mastoid. Consequently, coalescent silent mastoiditis develops. This inflammatory process can expand to distant areas from a weak point and cause an abscess. In Bezold's abscess, this expansion occurs by means of digastric incisure.^[4,10]

In the literature, Bezold's abscess has been reported in patients between 1 and 73 years of age. The mean age is 31.^[7] It is seen more commonly in adults. In the English literature, 27 cases of Bezold's abscess were reported between 1966 and 2001.^[10] In the Japanese literature, 18 Bezold's abscess cases were reported between 1960 and 2002.^[1] Bezold's abscess is still seen commonly as a complication of chronic otitis media in

Anatolia. In a study performed by Osma et al.^[5], the percentage of Bezold's abscess among the extracranial complications of chronic otitis media was one of the lowest at 10.3%.

The risk of formation of Bezold's abscess is higher in mastoid bones, particularly with superficial mastoid cells with a well-pneumatized, thin bone wall whose cell is single and big. The thinning of bone walls occurs as the pneumatization of the mastoid rises, and this increases the risk.

In adults, abscess formation is eased by good pneumatization of the mastoid, while the risk is lower in children because of the lack of pneumatization of the mastoid. This explains why Bezold's abscess is rarely seen among children.^[4,7,11,14] Cholesteatoma is an important risk factor. In addition, a history of mastoidectomy is an important risk factor. In that situation, Bezold's abscess can be formed by expansion of an infection to eroded bone and mastoid process by the surgeon.^[7,12,14]

Bezold's abscess can cause death if it expands to the vertebral column and head base resulting in central nervous system involvement.^[8,11,12] That's why early diagnosis and therapy are crucial. A careful, detailed history taking and physical examination play a crucial role in early diagnosis even today. The abscess cannot fluctuate, as it is placed deeply and cannot be palpated.^[7,14] Moreover, antibiotic therapies applied initially can mask the inflammatory symptoms and delay the diagnosis.^[11,12] In a patient with chronic otitis media who has neck complaints, Bezold's abscess must be brought to mind.

In a study, the rates of major clinical symptoms were: fever 74%, otalgia 52%, swelling of the neck 48%, otorrhea 41%, movement disability of the neck 41%, neck pain 41%, facial paralysis 15%, and hearing loss 11%. Perforation of the tympanic membrane is not necessarily found in each case on ear examination. The tympanic membrane is usually intact and hyperemic in cases less than 5 years old. The laboratory findings are often non-specific.^[7] Our case was secondary to right chronic suppurative otitis media, and the

obvious signs included fever, otorrhea, general status disorder, movement disability of the neck, hearing loss, and tenderness of the right portion of the neck. A mild swelling on the neck was also present.

CT is the best screening test for Bezold's abscess. It is valuable for both diagnosis and treatment. CT of the temporal bone and neck plays a crucial role in diagnosis. CT provides a precise and careful approach plan to the surgeon. It is very helpful for differential diagnosis of Bezold's abscess versus other neck abscesses. One further advantage of CT is that it can help diagnose abscesses that cannot be diagnosed clinically.^[3,6,7,12] Infective abscesses, lymphadenopathies, and cystic hygroma are very important in differential diagnosis of Bezold's abscess.^[4] In addition, dural sinus thrombosis can be seen together with Bezold's abscess.^[11,15] This co-occurrence must be taken into consideration in diagnosis and treatment.

Surgery and wide-spectrum parenteral antibiotics are the most significant methods of treatment.^[1,7,12,16,17] Emergent mastoidectomy is performed. In some cases, neck exploration, abscess debridement, and irrigation are performed for abscess drainage, and drains are placed. This procedure is also significant for a good prognosis.^[11] In the postoperative period, the patient is followed up by applying wide-spectrum intravenous antibiotics.

Abscess cultures can be taken during or before surgery. According to some authors, the most commonly isolated microorganism is *Streptococcus pneumoniae*.^[4,9] Gram + aerobics are the microorganisms most commonly isolated from abscess cultures. They include *S. pneumoniae*, *Staphylococcus*, and *Enterococcus*. Also, gram - aerobics (*Klebsiella*, *Pseudomonas*, *Proteus* spp.) and anaerobics (*Peptostreptococcus* and *Fusobacterium* spp.) may be isolated. Mixed microorganisms are isolated as well.^[12] Abscess culture may be sterile as a result of antibiotic therapies applied previously.^[8,12] The overall conclusion is that multiple bacterial agents cause infection rather than a single factor.

Total cure could be established with surgery and appropriate antibiotic therapy in Bezold's abscess. That's why it must be kept in mind even though it is a rare complication.

Kaynaklar

- 1- Uchida Y, Ueda H, Nakashima T. Bezold's abscess arising with recurrent cholesteatoma 20 years after the first surgery: With a review of the 18 cases published in Japan since 1960. *Auris Nasus Larynx* 2002; (29) : 375-8.
- 2- Zapanta PE, Chi DH, Faust RA. A unique case of Bezold's abscess associated with multiple dural sinus thromboses. *Laryngoscope* 2001; (111) : 1944-8.
- 3- Marioni G, de Filippis C, Tregnaghi A, Marchese-Ragona R, Staffieri A. Bezold's abscess in children: Case report and review of the literature. *Int J Pediatr Otorhinolaryngol* 2001; (61) : 173-7.
- 4- Syms MJ, Foster SL. Bezold's abscess. *Mil Med* 2001; (166) : 354-5.
- 5- Osma U, Cureoglu S, Hosoglu S. The complications of chronic otitis media: Report of 93 cases. *J Laryngol Otol* 2000; (114) : 97-100.
- 6- Castillo M, Albernaz VS, Mukherji SK, Smith MM, Weissman JL. Imaging of Bezold's abscess. *AJR Am J Roentgenol* 1998; (171) : 1491-5.
- 7- Spiegel JH, Lustig LR, Lee KC, Murr AH, Schindler RA. Contemporary presentation and management of a spectrum of mastoid abscesses. *Laryngoscope* 1998; (108) : 822-8.
- 8- Gaffney RJ, O'Dwyer TP, Maguire AJ. Bezold's abscess. *J Laryngol Otol* 1991; (105) : 765-6.
- 9- Smouha EE, Levenson MJ, Anand VK, Parisier SC. Modern presentations of Bezold's abscess. *Arch Otolaryngologistyngol Head Neck Surg* 1989; (115) : 1126-9.
- 10- Doan NM, Levy C, Deeb Z, Lucey DR. Case report Bezold's abscess: A complication of mastoiditis. *Infections in Medicine* 2003; (20) : 502-6.
- 11- Tembe D. Unusual case of Bezold's abscess. *J Laryngol Otol* 1967; (81) : 561-6.
- 12- Moisa II, Danziger EJ, Brauer RJ. Subperiosteal and Bezold's abscesses complicating cholesteatoma: A case report. *Otolaryngol Head Neck Surg* 1987; (97) : 399-402.
- 13- Matanda RN, Muyunga KC, Sabue MJ, Creten W, Van de Heyning P. Chronic suppurative otitis media and related complications at the University Clinic of Kinshasa. *B-ENT* 2005; (1) : 57-62.
- 14- Stokroos R. Radiology quiz case: Bezold's abscess. *Arch Otolaryngol Head Neck Surg* 2003; (129) : 683-4.
- 15- Lahlou M, Lazrak A, Boulaich M, Oujilal A, Kzadri M. Association of Bezold's abscess and sigmoid sinus thrombosis. A case report. *Rev Laryngol Otol Rhinol* 2006; (127) : 157-60.
- 16- I.M. Vlastos, G. Helms, I. Athanasopoulos, M. Houlakis. Acute mastoiditis complicated with bezold abscess, sigmoid sinus thrombosis and occipital osteomyelitis in a child. *European Review for Medical and Pharmacological Sciences* 2010; (14) : 635-8.
- 17- Jing-Fang Wu, Zhe Jin, Jian-Ming Yang, Ye-Hai Liu, Mao-Li Duan. Extracranial and intracranial complications of otitis media: 22-year clinical experience and analysis. *Acta Oto-Laryngologica*, 2012; (132) : 261-5.