

Evaluation of changes in meibomian glands in polycystic ovary syndrome by noncontact infrared meibography

Polikistik over sendromu'nda meibomian bezlerdeki değişikliklerin kontakt olmayan kızılötesi meibografi ile değerlendirilmesi

Yaran Koban¹, Rulin Deniz², Yakup Baykuş², Lokman Balyen¹, Hüseyin Çelik³

¹ Kafkas University, Faculty of Medicine,
Department of Ophthalmology, Kars, Turkey
² Kafkas University, Faculty of Medicine,
Department of Obstetrics and Gynecology, Kars,
Turkey
³ Gaziantep Dr. Ersin Arslan State Hospital,
Department of Ophthalmology, Gaziantep, Turkey

ORCID ID of the author(s)

YK: 0000-0002-4981-8001
RD: 0000-0002-7306-8212
YB: 0000-0001-5730-8477
LB: 0000-0003-4298-7256
HC: 0000-0002-2455-9381

Abstract

Aim: The human meibomian gland contains several overexpressed genes that are related to lipid dynamics and glandular structure. Meibomian gland dysfunction (MGD) was found to be associated with significant changes in these genes. The aim of this study was to compare the changes in meibomian glands in patients with polycystic ovary syndrome (PCOS) and healthy young women by non-contact meibography for the first time.

Methods: A total of 58 right eyes belonging to 28 patients with PCOS and 30 healthy women in the control group were included in this case-control study. The ocular surface and eyelid margins were evaluated with slit lamp examinations. Participants were asked about dry eye symptoms. Schirmer and tear film break time (TBUT) tests were performed consecutively. The morphology of the meibomian glands was observed with non-contact meibography and scored with the meiboscure.

Results: Dry eye symptoms were more prevalent and average TBUT was shorter in PCOS patients ($P=0.001$, $P=0.02$, respectively). However, Schirmer test results did not differ among the PCOS and control groups ($P=0.47$). The meiboscores for upper eyelids and total eyelids were significantly higher in the PCOS group ($P=0.001$ and $P=0.004$, respectively), suggesting that PCOS is accompanied by meibomian gland dropout.

Conclusion: In this study, we found that the morphological status of the meibomian gland and the ocular surface were in worse condition in PCOS patients than in the normal controls, and we successfully observed the loss of meibomian gland in PCOS patients through non-contact meibography.

Keywords: Dry eye, Meibography, Meibomian gland dysfunction, Polycystic ovarian syndrome

Öz

Amaç: İnsan meibomian bezi lipid dinamikleri ve glandüler yapı ile bağlantılı, aşırı eksprese edilmiş birkaç gen içerir; ve meibomian bez disfonksiyonunun (MBD) bu genlerdeki önemli değişikliklerle ilişkili olduğu bulunmuştur. Bu çalışmanın amacı, ilk kez temassız meibografi ile polikistik over sendromlu (PKOS) hastalarda ve sağlıklı genç kadınlarda meibomian bezlerindeki değişiklikleri karşılaştırmaktır.

Yöntemler: Bu olgu-kontrol çalışmasına PKOS'lu 28 hasta ve kontrol grubundaki 30 sağlıklı kadının toplam 58 sağ gözü dahil edildi. Oküler yüzey ve göz kapağı kenarları yarı lamba incelemeleri ile yapıldı. Katılımcılara kuru göz semptomları hakkında sorular soruldu. Schirmer ve gözyaşı kırılma zamanı (GKZ) testleri sırasıyla tamamlanmıştır. Meibomian bezlerinin morfolojisi temassız meibografi ile gözlemlendi ve meiboscure kullanılarak skorlandı.

Bulgular: PKOS'da kuru göz semptomları daha sık görülmüştür ($P=0,001$). PKOS'da ortalama GKZ daha kısaydı ($P=0,02$). Bununla birlikte Schirmer test sonuçları PKOS ve kontrol grubu arasında farklı değildi ($P=0,47$). Ek olarak, PKOS'un meibomian bez kaybı ile birlikte olduğunu düşündürecek şekilde, üst göz kapakları ve toplam göz kapakları için meibomian bez skorları, PKOS'da kontrol grubundan anlamlı olarak daha yüksekti (sırasıyla, $P=0,001$ ve $P=0,004$).

Sonuç: Bu çalışmada, PKOS'lu hastalarda meibomian bezinin morfolojik durumunun ve oküler yüzey durumunun normal kontrollerden daha kötü olduğunu ve PKOS'lu hastalarda temassız meibografi ile meibomian bezinin kaybını başarıyla gözlemledik.

Anahtar kelimeler: Kuru göz, Meibografi, Meibomian bezi disfonksiyonu, Polikistik over sendromu

Corresponding author / Sorumlu yazar:

Yakup Baykuş

Address / Adres: Kafkas Üniversitesi Tıp Fakültesi,
Kadın Hastalıkları ve Doğum AD, Merkez, 36100,
Kars, Türkiye

e-Mail: dryakup01@hotmail.com

Ethics Committee Approval: The approval has been obtained from of the ethic committee of Kafkas University faculty of medicine (2015/80576354-050-99/120).

Etik Kurul Onayı: Onay, Kafkas Üniversitesi Tıp Fakültesi Etik Kurulundan alınmıştır (2015/80576354-050-99/120).

Conflict of Interest: No conflict of interest was declared by the authors.

Çıkar Çatışması: Yazarlar çıkar çatışması bildirmemişlerdir.

Financial Disclosure: The authors declared that this study has received no financial support.

Finansal Destek: Yazarlar bu çalışma için finansal destek almadıklarını beyan etmişlerdir.

Published: 9/29/2019

Yayın Tarihi: 29.09.2019

Copyright © 2019 The Author(s)

Published by JOSAM

This is an open access article distributed under the terms of the Creative Commons Attribution-NonCommercial-NoDerivatives License 4.0 (CC BY-NC-ND 4.0) where it is permissible to download, share, remix, transform, and buildup the work provided it is properly cited. The work cannot be used commercially without permission from the journal.



Introduction

Sex hormones have been proven to influence tear production and function [1,2]. Hormone studies have shown that the effect of sex hormones on tear production and goblet cell density and on meibomian gland functions and structures may cause dry eyes [3]. Supporting this hypothesis, androgen receptors have been identified on the surface of the meibomian glands [4]. Lipid, produced by the meibomian glands, is an essential component of the tear film and prevents evaporation of the aqueous layer while reducing surface tension of the tear film, and ensuring stability of the lacrimal layer [5].

Although previous studies have shown a correlation between meibomian gland dysfunction (MGD) and polycystic ovarian syndrome (PCOS), little is known regarding the meibomian gland morphology in this syndrome. The recent development of noninvasive meibography and scoring systems for meibomian glands has provided important insight into meibomian gland structure and function. The objective of this study was to evaluate, for the first time, the meibomian glands of PCOS patients with meibography and to compare the results of meibography analysis in normal subjects and patients with PCOS.

Materials and methods

Ethics committee approval (Kafkas university faculty of medicine, 2015/80576354-050-99/120) was obtained prior to the study. We included all patients over 18 years of age who were treated for PCOS between November 2015 and December 2016. All subjects were given informed consent forms to participate in this case-control study.

Participants

Twenty-eight female patients monitored for PCOS at Kafkas University Medical Faculty Obstetrics and Gynecology clinic were selected as the study group, while 30 healthy women volunteers examined by the eye clinic were included as the control group ($n_{\text{Total}}=58$). Patients who were referred to Kafkas University Medical Faculty Obstetrics and Gynecology clinic were diagnosed with PCOS in accordance with the Rotterdam 2003 criteria, in which at least two of the following criteria were needed: oligo-amenorrhea (more than 45 days between menses or eight or fewer menses per year), presence of hyperandrogenism clinical hirsutism (hirsutism, acne, acanthosis nigricans, androgenic alopecia) or elevated androgens in laboratory tests (increased levels of serum total and free testosterone), and ultrasonographic polycystic ovarian appearance (2-9 mm diameter, 12 or more follicles and/or increased ovarian volume (>10 ml) [6].

All patients had their luteinizing hormone (LH)/follicle stimulating hormone (FSH) ratio, prolactin levels, thyroid functions, dehydroepiandrosterone sulfate, 17 hydroxyprogesterone and total testosterone levels analyzed and patients with hyperprolactinemia, congenital adrenal hyperplasia, thyroid disease, Cushing syndrome, and those who used hormonal medications, glucocorticoids, ovulation inducing agents, and antiandrogens in the past six months were excluded from the study. Additionally, patients who used contact lenses, diuretics, steroids or antidepressants for systemic or ocular

treatment, those with systemic diseases such as diabetes mellitus or thyroid disease, history of ocular or refractive surgery, blockage of the nasolacrimal channel or ocular surface problems were excluded from the study.

Study protocol

In addition to the study group, a detailed ophthalmologic examination was meticulously performed to the control group subjects by a masked observer (HC) between the third and fifth day of the menstrual cycle, which included the following: Assessment of lid margin abnormalities, the Schirmer 1 test, tear film break-up time (TBUT), and grading of meibomian gland status. Each participant completed an ocular surface disease index (OSDI) questionnaire with 12 questions to evaluate ocular surface symptoms. An interval of at least 10 minutes was assured between TBUT and the Schirmer test. The MGD was characterized based on the existence of anterior or posterior displacement relative to the mucocutaneous junction, irregular lid margin, vascular engorgement and obstruction of the meibomian gland orifices [7]. Meibomian glands were evaluated by a noncontact meibography system (Sirius Scheimpflug Camera, Schwind, Germany), and images were captured by noncontact meibography system after inverting both upper and lower of eyelids. Partial or complete loss of the meibomian glands for each eyelid were graded with meiboscores as previously reported: Grade 0 (no loss of meibomian glands), grade 1 (loss of 1/3 of the total area of meibomian glands), grade 2 (meibomian glands loss between 1/3 and 2/3), and grade 3 (meibomian glands loss $\geq 2/3$). Meiboscores for the upper and lower eyelids were summed up to make up a total of 0 to 6 scores [8].

Statistical analysis

The statistical analysis was performed with the Statistical Package for Social Sciences (SPSS) program version 10.0 (SPSS Inc., Chicago, IL, USA). Independent samples t-test and Chi-square tests were used for statistical analysis. Pearson's correlation test was used for correlation between parameters. P -value <0.05 was considered statistically significant.

Results

A total of 58 right eyes belonging to 28 PCOS patients and 30 control group subjects were included in this study. The average age of patients in the PCOS group was 25.0 years (minimum 19, maximum 41), while the average age of individuals in the control group was 26.4 years (minimum 19, maximum 31). There was no statistically significant difference between PCOS group and control group in terms of age ($P=0.32$). The demographic and metabolic parameters in the groups are given in Table 1.

The OSDI scores between PCOS patients and normal individuals was found significantly different ($P=0.001$). The incidence of MGD was 22.6% in the PCOS group and 10% in the control group ($P=0.04$). The Schirmer test was measured as 20.1 mm in the study group and 17.7 mm in the control group. The average Schirmer measurements were similar in both groups ($P=0.47$). TBUT was 12.1s in the PCOS group and 14.6 in the control group, the difference was statistically significant ($P=0.02$). The average meiboscore of the upper lids, the lower lids and total (upper eyelid plus lower eyelid) lids in PCOS were

1.3 (range, 0–3), 0.6 (range, 0–2), and 1.1 (range, 0–2.5), respectively. The average meiboscore of the upper lids, the lower lids and total (upper eyelid plus lower eyelid) lids in healthy subjects were 0.5 (range, 0–1), 0.4 (range, 0–2), and 0.4 (range, 0–1.5), respectively. The meiboscores for upper eyelids and total eyelids were significantly higher in patients with PCOS ($P=0.001$ and $P=0.004$, respectively) (Table 2). The degree of each image is noted at the upper left. Representative images of meibomian glands in the upper and lower eyelids are seen in patients obtained by non-contact meibography from PCOS (Figure 1A, 1B) and control group (Figure 1C, 1D). Dropout, distortion, and shortening of meibomian gland ducts are apparent in the upper and lower eyelids in patients from with PCOS.

Table 1: Demographic and metabolic parameters

Variable	PCOS Group (n=28)	Control Group (n=30)	P-value
Age, years	26.4 (5.8)	25.0 (4.2)	0.32
BMI, kg/m ²	25.4 (7.3)	23.5 (2.6)	0.21
VA (Snellen)	1,0	1,0	0.49
SE (diopter)	0.9 (1.1)	1.1 (0.9)	0.46
Plasma glucose (mg/dl)	89.7 (11.6)	87.1 (5.7)	0.56
FSH (IU/L)	6.0 (1.4)	6.4 (1.8)	0.33
LH (IU/L)	10.9 (8.0)	4.9 (2.1)	0.001*
E2 (pmol/L)	58.8 (47.2)	58.5 (20.1)	0.17
DHEAS (μmol/L)	218 (113)	209 (104)	0.65
Total testosterone (ng/mL)	55.6 (2.4)	28.1 (1.2)	0.001*

PCOS: Polycystic Ovary Syndrome, BMI: Body Mass Index, VA: Visual Acuity, SE: Spherical Equivalent, DHEAS: Dehydroepiandrosterone sulfate, E2: Estradiol, FSH: Follicle-Stimulating Hormone, LH: Luteinizing Hormone, * $P<0.05$ was considered statistically significant

Table 2: Ocular surface and meibomian gland clinical test results

Variable	Control Group (n=30)	PCOS Group (n=28)	P-value
OSDI	10.5 (9.4)	28.1 (18.5)	0.001*
Schirmer test score (mm)	17.7 (3.4)	20.1 (7.4)	0.47
TBUT (s)	14.6 (3.2)	12.1 (3.5)	0.02*
The incidence of MGD (%)	10.0	22.6	0.04*
Meiboscore (Upper eyelid)	0.5 (0.5)	1.3 (1.1)	0.001*
Meiboscore (Lower eyelid)	0.4 (0.6)	0.6 (0.6)	0.33
Meiboscore (Total)	0.4 (0.5)	1.1 (0.6)	0.004*

PCOS: Polycystic Ovary Syndrome, MGD: Meibomian Gland Dysfunction, OSDI: Ocular Surface Disease Index, TBUT: Tear Break-up Time, * $P<0.05$ was considered statistically significant

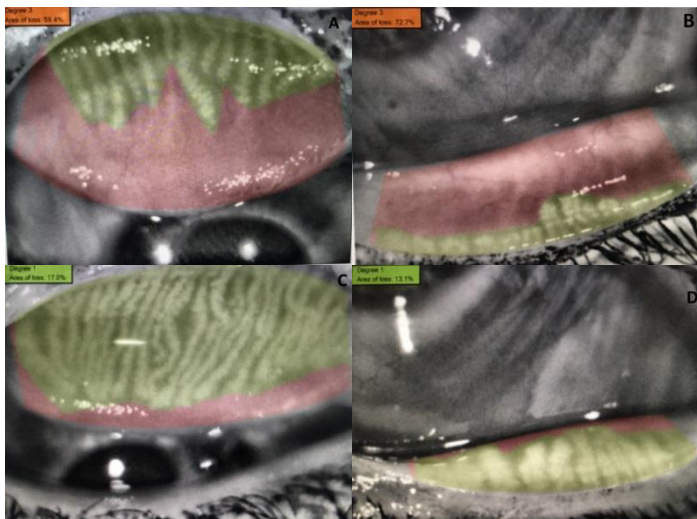


Figure 1: Representative images of meibomian glands in the upper and lower eyelids in patients from PCOS (A, B) and control group (C, D) obtained by non-contact meibography.

Discussion

Dry eye disease, a multifactorial disease with the potential to cause injury to the ocular surface, is characterized by visual impairment, feeling of discomfort and variability of the tear film according to the DEWS classification reported in 2007 [9]. The meibomian glands are vertically placed large sebaceous glands within the rim of the upper and lower lids and dysfunction of these glands is present in nearly 2/3 of all dry eye cases. Increased viscosity of meibum secretions and increased

keratinization of ductal epithelium causes MGD [10]. Meibography allows observation of meibomian gland morphology in silhouette through illumination of the eyelids from the skin side, thereby identifying morphological abnormalities. This procedure shows narrowing or blockage of the gland orifice, distention of the glands, dilatation of the channels or loss of the gland structures in MGD [11]. Previous studies have shown correlations between contact lens use, phlyctenular keratitis, rosacea, diabetes and chronic smoking with variations in meibomian gland morphology [11-14]. To the best of our knowledge, this is the first study to appraise the lid margin and meibomian glands, particularly through the use of a noncontact meibography technique in PCOS patients.

It is well-known that hormonal regulation has a significant effect on meibomian gland biology [10]. Previous studies identified expression of androgen receptors, estrogen receptors, and progesterone receptors in human meibomian gland epithelial cells [15]. Androgens primarily act on acinar epithelial cells in sebaceous glands, which contain both androgen receptor mRNA and protein in their nuclei. Acinar cells respond to androgens by increasing the transcription of multiple genes and synthesizing proteins that enhance the secretion of lipids [16]. Additionally, insulin, essential for the desired sebaceous gland activity, is known to induce glandular cell proliferation and lipid secretion [12]. Although changes in the meibomian glands have been shown with dry eye tests in PCOS patients, to the best of our knowledge, the meibomian gland morphology in PCOS has not been investigated with meibography [17,18]. However, a recent study has showed that the human meibomian gland comprises many highly expressed genes associated with lipid dynamics and glandular structure, and MGD was found to be associated with significant alterations in these genes [19].

PCOS, characterized by hyperandrogenic chronic anovulation, is a complex metabolic and endocrine disorder. The U.S. Department of Health and Human Services anticipated that between 1 in 10 and 1 in 20 women of childbearing age suffer from PCOS [20]. Laboratory investigation of patients yielded hyperandrogenemia characterized by increases in ovarian and adrenal sourced androgenic hormones in addition to increased LH levels and LH/FSH ratio. Nearly 25-60% of cases have hyperinsulinemia and insulin resistance, and 15-20% of PCOS patients may have mildly elevated prolactin levels without functional prolactinoma [21,22]. Clinically, PCOS is generally diagnosed after cosmetic complaints such as hirsutism, or menstrual dysfunction and infertility. Dry eye symptoms are triggered by hormonal imbalance encountered at considerable rates [23]. Although meibomian gland function is shown to be significantly disrupted in PCOS patients, the full underlying mechanism is still unknown [17,18].

Previous studies reported controversial results. Bonini et al. [23] showed that TBUT was significantly reduced in PCOS patients, with a contrary increase in the density of conjunctival goblet cells. They proposed that the itchy-dry eye symptoms encountered in PCOS were a separate clinical entity sharing many characteristics of dry eye and ocular allergy diseases. A series by Yavaş et al. [17] found TBUT significantly reduced, with no significant difference in terms of Shirmer test results, goblet cell count and rose Bengal score between the control and

PCOS patient groups. Baser et al. [18] showed that TBUT was significantly low in PCOS, while the incidence of pathologic TBUT values (<10s) was similar among PCOS and control groups. The differences in these results may be related to personal differences between patients like age and insulin resistance, and/or differences in androgen and estradiol levels. In this study, by using noncontact meibography, the morphology of the meibomian glands were compared in eyelids between patients with PCOS and healthy young adults. We found that PCOS is accompanied by significant loss of meibomian gland tissue, defined by reduced meibomian gland area and increased meibomian gland distortion.

Postmortem studies have shown differentiation of meibocytes and reduced cell cycles in aging meibomian glands, with a clear correlation between meibomian gland atrophy and age [24,25]. However, when males and females with similar advanced age are assessed, the incidence of abnormal eyelid and gland dropout is found higher in males compared to females. The proposed cause is hormonal differences [26]. A study by Mizoguchi et al. [27] assessed the morphology and function of meibomian glands in 15-year old middle school students and found that significant sex differences were apparent in the meiboscore (males:3.3, females:2.4). Machalińska et al. [25] proved that postmenopausal hormone treatment was among the independent predictors of meibomian gland loss in the healthy population.

In this study, MGD and OSDI scores were significantly higher and TBUT was significantly lower in PCOS patients than in the control women. When the morphology of meibomian glands was examined with the noncontact meibography system, it was found that changes to the meibomian gland morphology were significantly higher in patients with PCOS. These results indicate that MGD and tear lipid layer deficiency associated with structural changes may be one of the mechanisms underlying the chronic itchy-dry eye associated with PCOS.

Limitations

We believe that there are some limitations in our study. The most important of these is the limited number of cases and another one is the lack of long-term follow-up. It would be useful to extend and follow-up the study with more patients.

Conclusion

This study showed that ocular surface condition in PCOS patients was worse than those in normal controls and remarkable loss of meibomian gland was objectively indicated with meibography. In light of these results, we conclude that MGD and the loss of meibomian gland evaluation is important in female patients with advanced and persistent dry eyes and PCOS should be considered. The severity and mechanisms of chronic tear film dysfunction can vary between different diseases and conditions such as diabetes, rosacea, age or smoking. These differences should be kept in mind during patient management. Further prospective research is needed to prove the provocative impact of PCOS on the meibomian gland morphology.

References

1. Pelit A, Aydın P. Oküler yaşlanma. *Geriatrici*. 2001;4:28-32.
2. Puderbach S, Stolze HH. Tear ferning and other lacrimal tests in normal persons of different ages. *Int Ophthalmol*. 1991;15:391-5.
3. Truong S, Cole N, Stapleton F, Golebiowski B. Sex hormones and the dry eye. *Clin Exp Optom*. 2014;97:324-36.

4. Rocha EM, Wickham LA, da Silveira LA, Krenzer KL, Yu FS, Toda I, et al. Identification of androgen receptor protein and Salfa reductase mRNA in human ocular tissues. *BJ Ophthalmol*. 2000;84:76-84.
5. Nelson JD, Shimazaki J, Benitez-del-Castillo JM, Craig JP, McCulley JP, Den S, et al. The international workshop on meibomian gland dysfunction: report of the definition and classification subcommittee. *Invest Ophthalmol Vis Sci*. 2011;52(4):1930-7.
6. Rotterdam ESHRE/ASRM Sponsored PCOS Consensus Workshop Group. Revised 2003 consensus on diagnostic criteria and long-term health risks related to polycystic ovary syndrome (PCOS). *Hum Reprod*. 2004;19:41-7.
7. Arita R, Itoh K, Maeda S, Maeda K, Furuta A, Fukuoka S, et al. Proposed diagnostic criteria for obstructive meibomian gland dysfunction. *Ophthalmology*. 2009;116:2058-63.
8. Arita R, Itoh K, Inoue K, Amano S. Noncontact infrared meibography to document age-related changes of the meibomian glands in a normal population. *Ophthalmology*. 2008;115:911-5.
9. The definition and classification of dry eye disease: report of the Definition and Classification Subcommittee of the International Dry Eye WorkShop. *Ocul Surf*. 2007;5:75-92.
10. Ding J, Sullivan DA. Aging and dry eye disease. *Exp Gerontol*. 2012;47:483-90.
11. Arita R, Fukuoka S, Morishige N. Meibomian gland dysfunction and contact lens discomfort. *Eye Contact Lens*. 2017;43:17-22.
12. Ding J, Liu Y, Sullivan DA. Effects of insulin and high glucose on human meibomian gland epithelial cells. *Invest Ophthalmol Vis Sci*. 2015;56:7814-20.
13. Machalińska A, Zakrzewska A, Markowska A, Safranow K, Wiszniewska B, Parafiniuk M, et al. Morphological and functional evaluation of meibomian gland dysfunction in rosacea patients. *Curr Eye Res*. 2016;41:1029-34.
14. Suzuki T, Morishige N, Arita R, Koh S, Sakimoto T, Shirakawa R, et al. Morphological changes in the meibomian glands of patients with phlyctenular keratitis: a multicenter cross-sectional study. *BMC Ophthalmol*. 2016;16:178.
15. Schröder A, Abarar DB, Hampel U, Schicht M, Paulsen F, Garreis F. In vitro effects of sex hormones in human meibomian gland epithelial cells. *Exp Eye Res*. 2016;151:190-202.
16. Sullivan DA, Yamagami H, Liu M, Stegall RJ, Schirra F, Suzuki T, et al. Sex steroids, the meibomian gland and evaporative dry eye. In: David A, Sullivan, Michael E, Stern, Kazuo Tsubota, Darlene A. Dartt, Rose M. Sullivan, B. Britt Bromberg, editors. *Lacrimal Gland, Tear Film, and Dry Eye Syndromes*; 3. New York: Springer Science; 2002. p.389-400.
17. Yavas GF, Ozturk F, Kusbeci T, Ermis SS, Yilmazer M, Cevrioglu S, et al. Meibomian gland alterations in polycystic ovary syndrome. *Curr Eye Res*. 2008;33:133-8.
18. Baser G, Yildiz N, Calan M. Evaluation of meibomian gland dysfunction in polycystic ovary syndrome and obesity. *Curr Eye Res*. 2017;42:661-5.
19. Liu S, Richards SM, Lo K, Hatton M, Fay A, Sullivan DA. Changes in gene expression in human meibomian gland dysfunction. *Invest Ophthalmol Vis Sci*. 2011;52:2727-40.
20. Sheehan MT. Polycystic Ovarian Syndrome: Diagnosis and Management. *Clin Med Res*. 2014;2:13-27.
21. Amiri M, Ramezani Tehrani F, Nahidi F, Kabir A, Azizi F, Carmina E. Effects of oral contraceptives on metabolic profile in women with polycystic ovary syndrome: A meta-analysis comparing products containing cyproterone acetate with third generation progestins. *Metabolism*. 2017;73:22-35.
22. Azziz R. PCOS: a diagnostic challenge. *Reprod Biomed Online*. 2004;8:644-8.
23. Bonini S, Mantelli F, Moretti C, Lambiase A, Bonini S, Micera A. Itchy-dry eye associated with polycystic ovary syndrome. *Am J Ophthalmol*. 2007;143:763-71.
24. Nien CJ, Massei S, Lin G, Nabavi C, Tao J, Brown DJ, et al. Effects of age and dysfunction on human meibomian glands. *Arch Ophthalmol*. 2011;129:462-9.
25. Machalińska A, Zakrzewska A, Safranow K, Wiszniewska B, Machaliński B. Risk factors and symptoms of meibomian gland loss in a healthy population. *J Ophthalmol*. 2016;2016:7526120.
26. Den S, Shimizu K, Ikeda T, Tsubota K, Shimmura S, Shimazaki J. Association between meibomian gland changes and aging, sex, or tear function. *Cornea*. 2006;25:651-5.
27. Mizoguchi T, Arita R, Fukuoka S, Morishige N. Morphology and function of meibomian glands and other tear film parameters in junior high school students. *Cornea*. 2017;36:922-6.

This paper has been checked for language accuracy by JOSAM editors.

The National Library of Medicine (NLM) citation style guide has been used in this paper.

Suggested citation: Patrias K. Citing medicine: the NLM style guide for authors, editors, and publishers [Internet]. 2nd ed. Wendling DL, technical editor. Bethesda (MD): National Library of Medicine (US); 2007 [updated 2015 Oct 2; cited Year Month Day]. Available from: <http://www.nlm.nih.gov/citingmedicine>