

Multiple enterogluteal fistulas, Crohn's disease: A case report

Multipl enterogluteal fistüller, Crohn hastalığı: Bir olgu sunumu

Karam Aziz¹, Abdelouhab El Marouni¹, Houssam Belghali¹, Tarik Souiki¹, Karim Ibn Majdoub¹, Imane Toughrai¹, Khalid Mazaz¹, Ahmed Zerhouni¹

¹ Visceral surgery service, Hassan II University hospital, Faculty of Medicine and Pharmacy of Fez, Sidi Mohammed Ben Abdallah University, Fez, Morocco

ORCID ID of the author(s)

KA: 0000-0002-3330-7311
AEM: 0000-0003-2035-7982
HB: 0000-0002-6734-2094
TS: 0000-0001-5657-7253
KIM: 0000-0002-0421-7296
IT: 0000-0003-0401-3012
KM: 0000-0001-7779-7802
AZ: 0000-0001-8441-016X

Abstract

Crohn's disease is a type of chronic inflammatory bowel disease (IBD) of unknown etiology that may affect any part of the gastrointestinal tract from mouth to anus and shows extra-intestinal involvement. It characteristically shows skip lesions. This case report reported in 2018 describes a 40 years old Moroccan female not known to have documented evidence of significant Crohn's disease. She was diagnosed with multiple fistulas that are a rare entity of patients with Crohn's disease, which is itself a rare disease in African countries.

Keywords: Crohn's disease, Fistulas, Ileocecal resection

Öz

Crohn hastalığı, gastrointestinal sistemin ağızdan anusa kadar herhangi bir bölümünü etkileyebilen ve ekstra bağırsak tutulumu gösteren, etiyojisi bilinmeyen bir tür kronik enflamatuvar barsak hastalığıdır (IBD). Karakteristik olarak atlama lezyonlarını gösterir. 2018'de bildirilen bu vaka raporunda, 40 yaşındaki Faslı kadın, önemli Crohn hastalığı olduğuna dair kanıtları belgelemediği biliniyor. Kendisi Afrika ülkelerinde nadir görülen bir hastalık olan Crohn hastalığı olan hastaların nadir bir varlığı olan çoklu fistül tanısı aldı.

Anahtar kelimeler: Crohn hastalığı, Fistüller, İleocekal rezeksiyon

Introduction

Crohn's disease is a type of chronic inflammatory bowel disease (IBD) of unknown etiology that may affect any part of the gastrointestinal tract from mouth to anus [1,2]. It typically presents as a recurrent course of patchy transmural inflammation with normal intestinal mucosa in between the diseased part followed by relapses [3,4]. It also manifests with extra intestinal complications most common being arthralgia/arthritis, and cutaneous, ophthalmologic and hepatobiliary manifestations. Smoking is considered as an important risk factor [5]. The treatment of this incurable disease aims at reducing the disease process, decreasing the number of relapses and improving the quality of life [6].

This case report describes a 40 years old Moroccan female known to have documented evidence of significant Crohn's disease since past 10 years. She is diagnosed with multiple fistulas that are a rare entity of patients with Crohn's disease, which is itself a rare disease in African countries.

Corresponding author / Sorumlu yazar:

Karam Aziz

Address / Adres: Visceral surgery service, Hassan II University hospital, Faculty of Medicine and Pharmacy of Fez, Sidi Mohammed Ben Abdallah University, Fez, Morocco
e-Mail: karamaziz87@gmail.com

Informed Consent: The authors stated that the written consent was obtained from the patient presented with images in the study.

Hasta Onamı: Yazar çalışmada görüntüleri sunulan hastadan yazılı onam alındığını ifade etmiştir.

Conflict of Interest: No conflict of interest was declared by the authors.

Çıkar Çatışması: Yazarlar çıkar çatışması bildirmemişlerdir.

Financial Disclosure: The authors declared that this study has received no financial support.

Finansal Destek: Yazarlar bu çalışma için finansal destek almadıklarını beyan etmişlerdir.

Published: 10/4/2019

Yayın Tarihi: 04.10.2019

Copyright © 2019 The Author(s)

Published by JOSAM

This is an open access article distributed under the terms of the Creative Commons Attribution-Non Commercial-NoDerivatives License 4.0 (CC BY-NC-ND 4.0) where it is permissible to download, share, remix, transform, and buildup the work provided it is properly cited. The work cannot be used commercially without permission from the journal.



Case presentation

A 40 years old Moroccan female with a past history of significant Crohn's disease since last 10 years presented to emergency room with severe gluteal and abdominal pain as well as a febrile condition (Figure 1). She denied the presence of chills, nausea and vomiting in her presenting complains and stated that she had normal bowel movements over the past one week.

The patient stated that she had occasional nausea and vomiting, crampy abdominal pain with bloating associated with meal intake and occasional diarrhea in the last 10 years leading to significant weight loss of 15 pounds over the previous 1–2 months. She denied any extra intestinal manifestations of her disease.

She was medically managed on infliximab for approximately 5 years but switched later to cetolizumab due to episodes of exaggerations between the doses. The next drug also failed after 1–2 months as she started having acute exaggerative episodes in the last few months. She had pre-operative colonoscopy, a year ago, after which she was recommended exploratory laparotomy with possible resection of diseased bowel but she denied it due to financial reasons.

Of all her past record of IV with oral contrast CT scans, the latest one that was performed approximately a year ago stated that the patient had moderately distended small bowel, compatible with small bowel obstruction, due to significant inflammatory edematous thickening of the terminal ileum. There was also evidence of multiple enteroenteric fistulas. In addition, there was an inflamed small bowel loop inseparable from the superior wall of bladder with presence of gas in the urinary bladder demonstrating evidence of enterovesicular fistula.

She also had colonoscopy a year ago that showed classical features of chronic inflammatory disease with tubulization in the sigmoid and the cecum except that there were no ulcerations present. The distal transverse colon and the entire descending colon appeared to be free of obvious disease. Overall pattern suggested of skip lesions with anal involvement classical for Crohn's disease.

The patient was operated with exploratory laparotomy discovering a fistula between sigmoid and cecum as well as a fistula between cecum and the right wall. We first did a fistulectomy of the fistula between the sigmoid and the cecum, then we proceeded to an ileocecal resection with ileocolic anastomosis then we tried a resection of 4 apparent fistulas tracks in the gluteal region (Figure 2, 3). Informed consent was taken from patient.

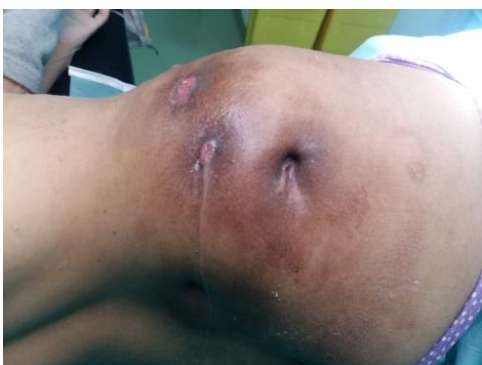

Figure 1: The patient gluteal fistulas at the emergency room

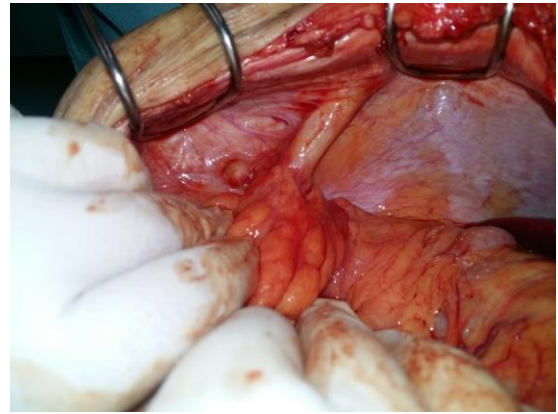


Figure 2: Peroperative fistula between cecum and the wall

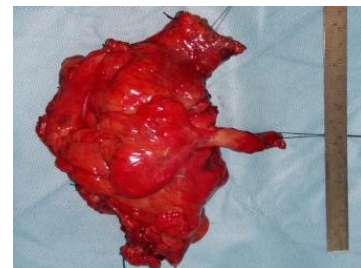


Figure 3: Ileocecal resection specimen

Discussion

The gluteal fistula and abscesses have been reported as complications of Crohn's disease, diverticulitis, colon carcinoma, and tuberculosis of lumbar vertebrae [7,8]. In our patient, recurrent abscesses history in gluteus suggested the possibility that there had been a fistula. In the case presented, initial diagnosis of a fistula could not be made till the visualization of fistulas. Computed tomography is helpful if exact spatial delineation of the tract is necessary or a suspect of associated abscess exists. Because CT results in high radiation, it should be used carefully in young children in selected indications. Ultrasound examination is generally not useful since it is limited by bowel gas and surgical incisions [9,10]. Magnetic resonance imaging (MRI) is reported as the golden standard in preoperative assessing and classifying of fistula, because MRI allows direct visualization of the tracts and abscesses through to high soft tissue resolution [11,12].

Surgery has been the main therapy for any sinus and fistula tracts. Open surgical exploration and repair provide definitive management, avoid recurrence, and prevent infection. Although surgical excision has been considered as a mode of treatment by most of the surgeons, the patient may be faced with some conditions such as nerve injuries, prolonged lymphatic drainage from the wound, recurrent lesions, wound infections, and unacceptable scar formations. Sclerotherapy using bleomycin is an established technique for the treatment of developmental vascular anomalies, also those which are at risk of developing intraoperative damage to vital organs and nerves, and lymphangiomas. Now sclerotherapy has been successfully used in the treatment of congenital sinus tracts [13,14].

Bleomycin is an antitumor agent and, besides its antineoplastic effect, bleomycin causes nonspecific inflammatory reaction leading to fibrosis in the surrounding tissues [15].

Conclusion

The present case is a description of a novel fistula tractus. To the best of our knowledge, this is the first case with

fistula deeply located and extending from the gluteus in the literature. Clinicians should consider underlying congenital malformation in the differential diagnosis of recurrent perineal and/or gluteal abscess. Catheter-based bleomycin injection could be applied as a safe, minimally invasive, and effective option for complex gluteal fistula, which makes it a suitable and durable alternative to open surgery. Treatment of this entity is individualized according to the site of fistula and associated anomalies.

References

1. Klein S, Kinney J, Jeejeebhoy K, Alpers D, Hellerstein M, Murray M, Twomey P, et al. Nutrition support in clinical practice: review of published data and recommendations for future research directions. *Am J Clin Nutr*. 1997;66(3):683–706.
2. Lee Kang M, Ji ML. Crohn's disease in Korea: past, present, and future. *Korean J Intern Med*. 2014;29(5):558–70.
3. James Samuel D, Wise Paul E, Zuluaga-Toro Tania. Identification of pathologic features associated with "ulcerative colitis-like" Crohn's disease. *World J Gastroenterol*. 2014;20(36):13139–45.
4. Sica GS, Di Carlo S, Tema G, Montagnese F, Del Vecchio Blanco G, Fiaschetti V, Maggi G, Biancone L. Treatment of peri-anal fistula in Crohn's disease. *World J Gastroenterol*. 2014 Oct 7;20(37):13205-10.
5. Ott C, Takses A, Obermeier F. Smoking increases the risk of extraintestinal manifestations in Crohn's disease. *World J Gastroenterol*. 2014;20(34):12269–76.
6. Magalhães J, Castro FD, Carvalho PB, Moreira MJ, Cotter J. Quality of life in patients with inflammatory bowel disease: importance of clinical, demographic and psychosocial factors. *Arq Gastroenterol*. 2014;51(3):192–7.
7. Singh G, Kaur B, Gupta S. Gluteal fistula—an unusual manifestation of carcinoma colon. *Indian Journal of Gastroenterology*. 2001;11(4):171.
8. Hussien M, Mudd DG. Crohn's disease presenting as left gluteal abscess," *International Journal of Clinical Practice*. 2001;55(3):217–8.
9. Alexander ES, Weinberg S, Clark RA, Belkin RD. Fistulas and sinus tracts: radiographic evaluation, management, and outcome. *Gastrointest Radiol*. 1982;7(2):135-40.
10. Nicholson T, Born MW, Garber E. Spontaneous cholecystocutaneous fistula presenting in the gluteal region. *J Clin Gastroenterol*. 1999 Apr;28(3):276-7.
11. Buchanan GN, Halligan S, Bartram CI, Williams AB, Tarroni D, Cohen CR. Clinical examination, endosonography, and MR imaging in preoperative assessment of fistula in ano: comparison with outcome-based reference standard. *Radiology*. 2004 Dec;233(3):674-81.
12. Baskan O, Koplay M, Sivri M, Erol C. Our Experience with MR Imaging of Perianal Fistulas. *Pol J Radiol*. 2014 Dec 24;79:490-7. doi: 10.12659/PJR.892098
13. Nixon PP, Healey AE. Treatment of a branchial sinus tract by sclerotherapy. *Dentomaxillofac Radiol*. 2011 Feb;40(2):130-2.
14. Duman L, Karnak I, Akinci D, Tanyel FC. Extensive cervical-mediastinal cystic lymphatic malformation treated with sclerotherapy in a child with Klippel-Trenaunay syndrome. *J Pediatr Surg*. 2006 Jan;41(1):e21-4.
15. Erişçi V, Hoşgör M, Yıldız M, Örnek Y, Aksoy N, Okur Ö, Demircan Y, Genişol İ. Intralesional bleomycin sclerotherapy in childhood lymphangioma. *Turk J Pediatr*. 2013 Jul-Aug;55(4):396-400.

This paper has been checked for language accuracy by JOSAM editors.

The National Library of Medicine (NLM) citation style guide has been used in this paper.

Suggested citation: Patrias K. Citing medicine: the NLM style guide for authors, editors, and publishers [Internet]. 2nd ed. Wendling DL, technical editor. Bethesda (MD): National Library of Medicine (US); 2007-[updated 2015 Oct 2; cited Year Month Day]. Available from: <http://www.nlm.nih.gov/citingmedicine>