

A comparative evaluation of bilateral hippocampus and amygdala volumes with ADC values in pediatric primary idiopathic partial epilepsy patients

Pedriatrik yaş grubu primer idiyopatik parsiyel epilepsi hastalarında bilateral hipokampus ve amigdala volümlerinin ADC değerleri ile karşılaştırmalı değerlendirilmesi

İsmail Taşkent¹, Gürkan Danişan¹, Hanefi Yıldırım²

¹ Mus State Hospital, Radiology Unit, Mus, Turkey
² Department of Radiology, Faculty of Medicine,
Firat University, Elazığ, Turkey

ORCID ID of the author(s)

İT: 0000-0001-6278-7863
GD: 0000-0003-2052-0006
HY: 0000-0002-6204-6392

Abstract

Aim: Approximately 70% of temporal seizures are hippocampal seizures, which are often concomitant with amygdala seizures. Seizures occurring in this region are usually complex partial. The aim of this study was to determine whether there was a significant change in hippocampus and amygdala volumes in idiopathic partial epilepsy patients without pathology on routine cranial MRI and to compare the hippocampus and amygdala ADC values with the control group.

Methods: In this case-control study, 27 patients aged between 1-18 years, who were admitted to our hospital between the years of 2014 and 2017 and diagnosed with idiopathic partial epilepsy based on EEG and clinical findings were compared with 20 children in the control group, which consisted of twenty children of similar ages who were referred to our hospital with nonspecific complaints such as headache and dizziness and who underwent cranial MRI. Children with histories of any congenital diseases, acquired neurodegenerative diseases, intracranial infections, intracranial masses, and those who were perinatally affected were not included in the study. Drawings, volumetric measurements, and ADC calculations were performed by two separate evaluators (one neuroradiology and one radiology research assistant).

Results: Hippocampus and amygdala volumes of the study group were decreased compared to the control group, but the results were significant only for the left hippocampus. Although ADC values of the study group were increased, the findings were statistically significant only for the left amygdala.

Conclusion: In our study, we found that the hippocampus and amygdala volumes of patients diagnosed with idiopathic partial epilepsy were decreased ipsilateral to the seizure focus, and the ADC values of the ipsilateral amygdala were increased.

Keywords: Idiopathic partial epilepsy, Hippocampus, Amygdala, Pediatric, ADC

Öz

Amaç: Temporal nöbetlerin yaklaşık %70'i hipokampal nöbetlerdir ve genellikle amigdala nöbetleri ile birliktedir. Bu bölgede meydana gelen nöbetler genellikle kompleks parsiyel nöbetlerdir. Çalışmamızın amacı, rutin kraniyal MRG'de patolojisi olmayan 0-18 yaş arasındaki idiyopatik parsiyel epilepsi hastalarında hipokampus ve amigdala hacminde anlamlı bir değişiklik olup olmadığını belirlemek ve hastaların hipokampus ile amigdala ADC değerlerini kontrol grubu ile karşılaştırmalı olarak değerlendirmektir.

Yöntemler: Yapılan olgu-kontrol çalışmasında 2014 ve 2017 yılları arasında hastanemize başvuran, 1-18 yaş arasında olup, EEG ve klinik bulgularıyla idiyopatik parsiyel epilepsi tanısı alan 27 hasta ile 20 kontrol grubu karşılaştırıldı. Kontrol grubu olarak, benzer yaşlarda olup hastanemize baş ağrısı ve baş dönmesi gibi nonspesifik şikâyetlerle başvuran ve kraniyal MRG çekilen 20 çocuk değerlendirildi. Çalışma ve kontrol grubunda bilinen konjenital hastalık öyküsü olan, edinsel nörodegeneratif hastalık geçiren, intrakraniyal enfeksiyon ya da perinatal etkilenme öyküsü bulunan ve intrakraniyal kitlesi olan çocuklar çalışmaya dâhil edilmemiştir. Çizimler, volümetrik ölçümler ve ADC ölçümleri iki ayrı değerlendirici tarafından yapıldılar (Biri nöroradyolog, diğeri radyoloji araştırma görevlisi).

Bulgular: Kontrol grubu ile karşılaştırıldığında, çalışma grubunda hipokampus ve amigdala volümlerinde azalma izlenmekle beraber sonuçlar sadece sol hipokampus için anlamlıydı. ADC değerlerinin karşılaştırılmasında çalışma grubunun ADC değerleri kontrol grubuna kıyasla artmış olmakla birlikte bulgular sadece sol amigdala için istatistiksel olarak anlamlıydı.

Sonuç: Çalışmamızda, idiyopatik parsiyel epilepsi tanısı alanlarda, hipokampus ve amigdala volümlerinin, nöbet odağına bağlı olarak ipsilateral azalmış olduğunu bulduk. Aynı zamanda, ipsilateral amigdala ADC değerlerinde artış olduğunu bulduk.

Anahtar kelimeler: İdiyopatik parsiyel epilepsi, Hipokampus, Amigdala, Pediyatrik, ADC

Corresponding author / Sorumlu yazar:

İsmail Taşkent

Address / Adres: Muş Devlet Hastanesi, Radyoloji

Birimi, Muş, Türkiye

e-Mail: dr.taskent@gmail.com

□

Ethics Committee Approval: Approval was obtained from Firat University Non-Interventional Research Ethics Committee (22.02.2016/132621).

Etik Kurul Onayı: Firat Üniversitesi Girişimsel Olmayan Araştırmalar Etik Kurulundan onay alınmıştır (22.02.2016/132621).

□

Conflict of Interest: No conflict of interest was declared by the authors.

Çıkar Çatışması: Yazarlar çıkar çatışması bildirmemişlerdir.

□

Financial Disclosure: The authors declared that this study has received no financial support.

Finansal Destek: Yazarlar bu çalışma için finansal destek almadıklarını beyan etmişlerdir.

□

Published: 10/21/2019

Yayın Tarihi: 21.10.2019

Copyright © 2019 The Author(s)

Published by JOSAM

This is an open access article distributed under the terms of the Creative Commons Attribution-NonCommercial-NoDerivatives License 4.0 (CC BY-NC-ND 4.0) where it is permissible to download, share, remix, transform, and build up the work provided it is properly cited. The work cannot be used commercially without permission from the journal.



Introduction

Idiopathic partial epilepsies (IPE) are thought to be hereditary, childhood epilepsy syndromes characterized by focal epilepsy seizures. IPEs are common and account for approximately %20 of epilepsies which begin between 2-13 years of age and %50 of all partial epilepsies. Electroencephalogram (EEG) shows epileptiform activities with special morphology that become evident with sleep. Cranial imaging and other ancillary studies do not reveal any anatomic lesions and seizures tend to end spontaneously after a certain age [1].

Limbic system is the border area where psychiatry and neurology intersect. Temporolimbic system is considered to consist of two main parts, namely, medial limbic and lateral limbic circuits. Medial circuits include the hypothalamus, anterior thalamic nucleus, cingulate gyrus, hippocampus, and related pathways; are associated with reticular formation, and manage learning, memory, and attention control functions. Lateral (or basolateral) circuits include the amygdala, dorsomedial thalamic nucleus, orbitofrontal cortex and the insula [2].

Approximately %70 of temporal seizures are hippocampal seizures and are often concomitant with amygdala seizures. Seizures occurring in this region are usually complex partial. Oral and alimentary automatisms such as chewing, licking, swallowing may follow the seizures. The spread of discharge may induce seizures to turn into generalized tonic-clonic convulsions. Focal lateralized or bilateral 4-6 Hz. sharp waves may be seen in ictal EEG [3].

It is pointed out that amygdala may be an important structure in triggering fear response. Ictal fear in temporal lobe epilepsy (TLE) is reportedly associated with volume reduction in the amygdala [4]. In some TLE patients, fear attacks disappear after temporal lobectomy with amygdala removal [5]. TLE patients who underwent right temporal lobectomy have been shown to exhibit less emotional signs than right TLE patients [6].

The aim of our study was to determine whether there was a significant change in the hippocampus and amygdala volumes in idiopathic partial epilepsy patients between 0-18 years of age who had no pathology in routine cranial magnetic resonance imaging (MRI), and to comparatively evaluate the patients' hippocampus and amygdala apparent diffusion coefficient (ADC) values.

Materials and methods

Three dimensional MRIs, obtained according to predetermined epilepsy protocols in our department, belonging to patients aged 0-18 years who had preliminary diagnoses of epilepsy were retrospectively evaluated. Twenty-seven patients who had partial seizures but had no pathology on cranial MRI were included in the study. Children with a history of congenital disease, neurodegenerative disease, intracranial infection or perinatal involvement, and an intracranial mass were not excluded.

The control group consisted of twenty children within the same gender and age group as the study group patients, who had nonspecific complaints such as headache or dizziness, whose

MRIs were obtained with suspicion of intracranial pathology and reported normal. Just as in the study group, children with intracranial masses, acquired or congenital diseases, and a history of intracranial infections were excluded. There were no findings suggestive of epilepsy in the history and examination of the children.

Age, gender, and EEG findings of all participants were determined from the medical records. Patients were classified as having temporal and non-temporal localizations according to EEG findings. All occipital, frontal, and parietal discharges were considered non-temporal. Right or left hemispheric localizations of all epileptic discharges were also determined.

Brain MRI examinations of the patients were performed using a 1.5 Tesla (Philips, Ingenia, Netherlands) MRI device using a standard head coil. In our clinic, 3-dimensional T1-sagittal turbo field echo (TFE), 3-dimensional turbo spin echo (TSE), fluid attenuated inversion recovery (FLAIR), T2-axial fast field echo (FFE) and turbo spin echo were performed routinely to pediatric epilepsy patients to obtain T2-sagittal, axial and coronal diffusion echo planar image (EPI) sequences. The following parameters are used to obtain 3D T1 sagittal images:

Volumetric measurements

Volumetric examinations of the amygdala and hippocampus regions of each patient were performed via 3D T1-sagittal TFE reformat images. The boundaries were drawn with the help of the workstation (General Electric Medical System, Advantage Windows, v4.6). Measurements defined by Watson et al. [7] were taken into consideration in drawing the hippocampus borders. The distinction between the anterior border of the hippocampus and the amygdala was made by alveus and uncus recesses. The borders were distinguished by the visualization of the choroid plexus superiorly, temporal horn in externally, perimesencephalic cisterna medially, fornix crus posteriorly and subiculum inferiorly. The study of Atmaca et al. [8] was referred to in determining the amygdala boundaries. The trace for drawing the boundaries began from where the mammillary bodies first appeared. The upper and lateral margins were formed by the white matter of the temporal lobe. The white matter of the parahippocampal gyrus formed the lower boundary. The anterior border was drawn from where the gray matter of the amygdala was no longer distinguishable from the rest of the temporal lobe. Drawings were made by two separate evaluators (one neuroradiology and one radiology research assistant).

After the hippocampus and amygdala boundaries were determined, volume was calculated with the help of the workstation and data were recorded in cubic centimeters. The measurements were made primarily by hand on the coronal plane and checked on the axial and sagittal planes (Figure 1-5).

ADC measurements

Diffusion-weighted images were obtained via single shot echo planar imaging vertical to the hippocampus in the coronal plane. Technical parameters used to obtain these images are as follows: Time of repetition (TR)=4284 ms, time of echo (TE)=91 ms, section thickness: 5mm, matrix size=152-102, number of signal averaging (NSA)=1, field of view (FOV)=23cm-23cm, sectional gap=1 mm, B value=1000 s/mm².

Images were evaluated with the Stejskal Tanner method using a workstation (Philips IntelliSpace Portal, R5.1.7 software)

[9]. Bilateral hippocampus and amygdala were determined in coronal plane and ADC measurements were performed. The hippocampus was measured from the head, corpus and tail, after which arithmetic mean was obtained. The mean region of interest (ROI) was 15 mm². The neighboring structures and cerebrospinal fluid were avoided during the measurements, and the hippocampus and amygdala were kept within ROI as much as possible. Thus, false values that may occur due to partial volume were prevented (Figure 6, 7).

Figures and Legends

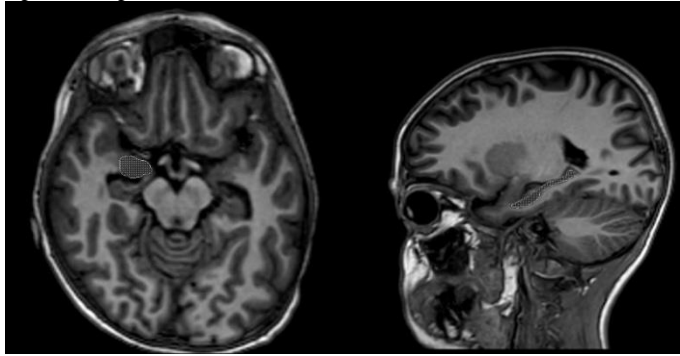


Figure 1: Determination of right amygdala border in axial plane Figure 2: Determination of hippocampal border in sagittal plane

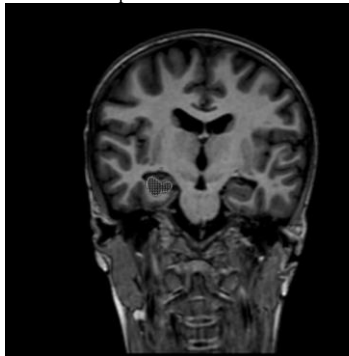


Figure 3: Determination of the right amygdala border in the coronal plane




Figure 4: Calculation of left hippocampal volume Figure 5: Calculation of left amygdala volume

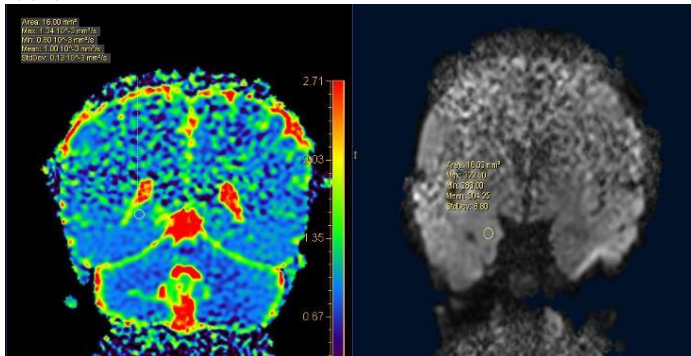


Figure 6: ADC image of posterior section of right hippocampus Figure 7: Diffusion MR image of right amygdala

Statistical analysis

Data were expressed as mean (standard deviation). Independent sample t test was used to analyze the differences

between the control and study groups. Spearman correlation test was used to determine the correlation between right and left values within each group. Statistical analysis was performed using SPSS (SPSS 20.0 for Windows) 20.0 package program. *P*<0.05 was considered statistically significant.

Amygdala and hippocampus volumes are known to vary in relation to intracranial volume. Therefore, to eliminate the effect of intracranial volume difference, the previously reported correction method was applied to amygdala and hippocampus volumes obtained with volumetric MRI [10]. Correction is reportedly more sensitive in demonstrating bilateral hippocampal sclerosis [11]. Likewise, bilateral changes in amygdala volumes may be evaluated more accurately after correction. According to this correction method, brain limits were determined visually in each section in brain volume calculation. The volume data, obtained from the manual drawing from the serial sections with determined boundaries, was recorded in cubic centimeters. The following formula was used to calculate the corrected volume:

$$\text{Adjusted volume} = \frac{\text{Mean cerebral volume of control subjects} \times \text{hippocampus volume}}{\text{Cerebral volume of the patient}}$$

Results

Among 27 patients with idiopathic partial epilepsy, 18 (66%) were male and 9 (33%) were female, with a male / female ratio of 2. The control group comprised 12 (60%) males and 8 (40%) females. The ages of the patients in both groups ranged from 1 to 18 years. There was no statistically significant difference between the study and control groups in terms of mean age and gender distribution. EEG showed right, left, and non-temporal discharge in right and left hemispheres in 7 (25.9%), 10 (37%), 4 (14.8%) and 6 (22.2%) patients, respectively. The cerebral volumes of the control and study groups were similar. The male and female patients were alike in terms of amygdala, hippocampus and cerebral volumes, as well as age.

The hippocampus and amygdala ADC values of the study group patients were higher, but a significant difference was found between the left amygdala values only (*P*=0.024, Table 1). While bilateral hippocampus and left amygdala volumes of the study group were lower than that of the control group, the right amygdala volume was higher. These results were not statistically significant. The same results were obtained with corrected volumes as well (Table 2).

In the comparison of left hemisphere-induced epilepsy group, left hippocampus volume was significantly (*P*=0.015) and the left amygdala volume was non-significantly decreased in the study group (*P*=0.374, Table 3). The hippocampus and amygdala ADC values on the left side were higher than the control group and the difference was significant for the amygdala (*P*=0.018) and not for the hippocampus (Table 4).

The left hippocampus volume of patients with left temporal lobe-induced epilepsy was significantly (*P*=0.037) and the left amygdala volume was non-significantly (*P*=0.522) decreased in the study group (Table 5). The hippocampus and amygdala ADC values on the left side were higher than the control group and the difference was significant for the amygdala (*P*=0.027) and not for the hippocampus (Table 6).

Table 1: Comparison of hippocampus and amygdala ADC values between the study and control groups

	Right hippocampus mean (SD)	Left hippocampus mean (SD)	Right amygdala mean (SD)	Left amygdala mean (SD)
Study group (n=27)	0.882 (0.485)	0.898 (0.430)	0.852 (0.598)	0.853 (0.436)
Control group (n=20)	0.864 (0.482)	0.883 (0.627)	0.828 (0.549)	0.823 (0.441)
P-value	0.226	0.344	0.163	0.024

Table 2: Comparison of study and control groups in terms of adjusted hippocampus and amygdala volumes

	Right hippocampus mean (SD)	Left hippocampus mean (SD)	Right amygdala mean (SD)	Left amygdala mean (SD)
Study group (n=27)	2.408 (0.229)	2.356 (0.348)	1.174 (0.210)	1.078 (0.273)
Control group (n=20)	2.471 (0.300)	2.482 (0.281)	1.145 (0.179)	1.109 (0.158)
P-value	0.417	0.191	0.618	0.644

Table 3: Comparison of left hippocampus and left amygdala volumes in patients with left hemisphere-induced epilepsy

	Left hippocampus mean (SD)	Left amygdala mean (SD)
Study group (n=16)	2.173 (0.393)	1.034 (0.303)
Control group (n=20)	2.471 (0.302)	1.106 (0.169)
P-value	0.015	0.374

Table 4: Comparison of left hippocampus and left amygdala ADC values in patients with left hemisphere-induced epilepsy

	Left hippocampus mean (SD)	Left amygdala mean (SD)
Study group (n=16)	0.898 (0.457)	0.860 (0.429)
Control group (n=20)	0.884 (0.628)	0.823 (0.441)
P-value	0.450	0.018

Table 5: Comparison of left hippocampus and left amygdala volumes in patients with left hemisphere-induced and left temporal epilepsy with the control group

	A (n=16) mean (SD)	B (n=20) mean (SD)	P-value	C (n=10) mean (SD)	D (n=20) mean (SD)	P-value
Left hippocampus	2.173 (0.393)	2.471 (0.302)	0.015	2.196 (0.366)	2.471 (0.302)	0.037
Left amygdala	1.034 (0.303)	1.106 (0.169)	0.374	1.056 (0.249)	1.106 (0.169)	0.522

A: Left hemisphere-induced study group, B: Left hemisphere-induced control group, C: Left temporal epilepsy study group, D: Left temporal epilepsy control group

Table 6: Comparison of ADC values of left hippocampus and left amygdala in patients with left hemisphere-induced and left temporal epilepsy

	A (n=16) mean (SD)	B (n=20) mean (SD)	P-value	C (n=10) mean (SD)	D (n=20) mean (SD)	P-value
Left hippocampus	0.898 (0.457)	0.884 (0.628)	0.450	0.903 (0.488)	0.884 (0.628)	0.394
Left amygdala	0.860 (0.429)	0.823 (0.441)	0.018	0.865 (0.492)	0.823 (0.441)	0.027

A: Left hemisphere-induced study group, B: Left hemisphere-induced control group, C: Left temporal epilepsy study group, D: Left temporal epilepsy control group

Discussion

The limbic lobe is formed by the combination of various structures in different anatomical lobes of the brain, namely, the frontal, temporal, and parietal lobes, and is not a real anatomical brain lobe. The concept of the limbic system refers to a larger area than the limbic lobe anatomically and is much more complex than the limbic lobe itself. The limbic lobe and all associated cortical and subcortical structures with intense synaptic connections which perform certain functions form the limbic system [12].

The limbic system contains important neuroanatomic formations such as thalamus, hypothalamus, hippocampus, pineal gland, pituitary gland and amygdala within the subcortical structures of the brain and is responsible for memory and mood changes [13].

Rosso et al. [14] reported a decrease in amygdala volumes of patients with major depression and no statistically significant difference between the hippocampus volumes compared to the control group. Szeszko et al. [15] found a decrease in the amygdala volumes of 11 patients with obsessive-compulsive disorder compared to the control group.

In Chang et al.'s study [16] in 20 pediatric patients diagnosed with bipolar disorder, no significant difference was detected in the hippocampus, thalamus, and caudate nucleus

volumes of the patients, but bilateral amygdala volumes were reportedly decreased. Keller et al. [17] found decreased hippocampus volumes in right and left hemisphere induced TLE patients compared to the control group, but no significant difference was found in amygdala volumes.

Partial onset seizures are often caused by the temporal lobe. These seizures are called complicated partial seizures when consciousness changes are added. A considerable proportion of these patients are resistant to drug therapy [18]. The seizures of TLE patients who do not have drug-resistant non-hippocampal epileptogenic focus and whose hippocampal atrophies were documented by MRI can be controlled by surgical treatment. Surgical success rate is low in patients with TLE in whom hippocampal atrophy is not detected by MRI. With regards to preoperative strategizing, it is very important for the radiology to fully lateralize the focus of epilepsy in drug resistant TLE cases. The diagnosis and precise lateralization in patients with bilateral symmetrical involvement of both hippocampi before surgery requires significant experience [19].

Hakyemez et al. [20] found a significant decrease in right and left hippocampi volumes in 27 patients with complex temporal lobe epilepsy, but no significant difference in amygdala volumes compared to the control group.

Similarly, in our study, although the mean volumes of bilateral hippocampi were decreased in the study group, a statistically significant difference was found only on the left. Amygdala volumes were not significantly different.

Amygdala volume ranged from 1.1 to 1.6 cm³ in postmortem studies. However, in different volumetric MRI analyses, values are measured in a wide range of 1 to 4 cm³ [11,21-23]. The reason for this may be the preference of low-resolution or thick-sectioned MRI techniques. Therefore, in many volumetric studies, it is thought that the amygdala volume is measured more than its real value [24]. Volume values obtained by MRI with a section thickness of one mm and three-dimensional analysis should be preferred. Such results are similar to those of post-mortem studies [25].

In an experimental study on mice, spontaneous recurrent seizures were observed in 50% of the mice after amygdala stimulation, but none of them lost volume in the amygdala or parahippocampal region. Significant neuron loss was observed in the hippocampal dentate gyrus hilum, but there was no significant difference in neuron loss between mice with and without spontaneous recurrent seizures [26]. Kalviainen et al. [27] compared 29 new patients, 54 patients with chronic temporal lobe epilepsy, and 25 control subjects. Although there was no significant difference in amygdala volumes, approximately 20% of patients with chronic diagnosis had at least 20% reduction in amygdala volumes compared to the control group.

In our study, preference of patients without visible hippocampal atrophy in study groups may explain the absence of significant differences in amygdala volumes. A slight decrease in the amygdala volumes in the patient may herald the loss of amygdala volume in the future.

Mu et al. [28] found that amygdala and hippocampus volumes differed significantly among some age groups in healthy

adult subjects, but that gender and right-left sides did not differ significantly.

Although no statistical study was performed, the mean right hippocampus volume was higher and left hippocampus volume, lower in male patients. The mean amygdala volume of females was slightly higher than males bilaterally. Females were found to have outvalued males in all measurements in the control group.

Geuze et al. [29] emphasized in their study how MRI technical parameters may affect the consistency of volumetric results and reported that particularly image acquisition parameters such as image resolution may have caused heterogeneity. They reported that differences between patient and control groups occurred in studies with high resolution. Numerous anatomical protocols for demonstrating the hippocampus are an important source of variability between studies.

When evaluating the performance of different MR techniques in TLE lateralization, hippocampal volume measurement seems prominent. However, the long duration of measurements for a single patient and the conflicts and difficulties in determining the hippocampus limits to be included in the measurement are the two most important limitations in the application of this method. On the other hand, studies have shown no significant difference between volume measurement and visual assessment in detecting hippocampal atrophy for an experienced neuroradiology [30]. In light of this information, it may be recommended to use hippocampal volume measurement primarily in bilateral atrophy cases where contralateral hippocampus cannot be used as reference, in cases where hippocampal volume changes are diminished and in centers with insufficient experience in diagnosing epilepsy [31,32].

Hippocampal sclerosis is a disease characterized by hippocampal neuronal loss causing mesial temporal lobe epilepsy (MTLE). Many studies on patients with hippocampal sclerosis [33-36] have shown that magnetic resonance imaging (MRI) is a reliable method for identifying epileptogenic focus. Hippocampal sclerosis is best demonstrated using T2-weighted or fluid attenuated inversion-recovery (FLAIR) sequences and thin coronal sections perpendicular to the hippocampus, and the most reliable MR imaging findings of hippocampal sclerosis are atrophy and/or signal enhancement of the hippocampus on T2-weighted and FLAIR images [37]. According to the results of autopsy studies, 50% of MTLE cases have bilateral hippocampal sclerosis [38-41]. Although high sensitivity and specificity have been reported with MRI for the diagnosis of hippocampal sclerosis [42-44], bilateral hippocampal sclerosis is difficult to detect because interpretation of MR images depends on comparing signal changes and volumes of hippocampal formations in the same subject [45].

In their study on 13 patients diagnosed with complex temporal lobe epilepsy, Hakyemez et al. [10] showed that patients with hippocampal sclerosis had significantly higher ADC values on the pathological side compared to the contralateral side and control group, but no significant increase in amygdala ADC values was reported.

In our study, no significant difference was found between bilateral hippocampus and right amygdala ADC values,

but left amygdala ADC values were higher in patients with temporal lobe epilepsy. This may be attributed to the fact that the left amygdala ADC values were high in the whole study group. The mean hippocampus ADC values were slightly and non-significantly higher in the study group, which may be due to the fact that patients with visible sclerosis were not included in our study group.

Limitations

As the number of patients was insufficient, temporal, and non-temporal epilepsy patients could not be compared in terms of amygdala and hippocampus volumes and ADC values. Although the average hippocampus volumes were not statistically analyzed, there was a decrease in the hippocampus and amygdala volumes of right-sided temporal epilepsy patients compared to non-temporal epilepsy patients.

The high male / female ratio in the gender distribution could be considered a limitation. Therefore, similar age and gender ratios were preferred in the control group. The fact that visible hippocampal sclerosis patients were not included in the study group may account for the fact that our findings do not resemble those of other studies. However, like other studies, non-significant decreases in hippocampus and amygdala volumes were found. There was no significant difference in ADC values due to the absence of apparent sclerosis.

Conclusion

The hippocampus and amygdala volumes of our pediatric patients diagnosed with idiopathic partial epilepsy were decreased ipsilateral to the seizure focus compared to the control group. There was an increase in ADC values in bilateral amygdala. Although our study showed that neuron loss and subsequent decrease in hippocampus and amygdala volumes may occur in idiopathic partial epilepsy patients, our findings were not as significant as chronic partial epilepsy cases.

References

1. Beaumanoir A, Nahory A. Benign partial epilepsies: 11 cases of frontal partial epilepsy with favorable prognosis. *Rev Electroencephalogr Neurophysiol Clin.* 1983;13:207-11.
2. Mega MS, Cummings JL. Frontal-subcortical circuits and neuropsychiatric disorders. *J Neuropsychiatry Clin Neurosci.* 1994;6:358-70.
3. Wieser HG. ILAE Commission Report. Mesial temporal lobe epilepsy with hippocampal sclerosis. *Epilepsia.* 2004;45:695-14.
4. Cendes F, Andermann F, Gloor P. Relationship between atrophy of the amygdala and ictal fear in temporal lobe epilepsy. *Brain.* 1994;4:739-46.
5. McLachlan RS, Blume WT. Isolated fear in complex partial status epilepticus. *Ann Neurol.* 1980;8:639-41.
6. Fedio P, Martin A. Ideative-emotive behavioral characteristics of patients following left or right temporal lobectomy. *Epilepsia.* 1983;24:117-30.
7. Watson C, Andermann F, Gloor P, Gotman M. Anatomic basis of amygdaloid and hippocampal volume measurement by magnetic resonance imaging. *Neurology.* 1992;42:1743-50.
8. Atmaca M, Yildirim H, Ozdemir H, Ozler S, Kara B, Ozler Z, et al. Hippocampus and amygdala volumes in patients with refractory obsessive-compulsive disorder. *Prog Neuropsychopharmacol Biol Psychiatry.* 2008;32:1283-6.
9. Stejskal EO, Tanner JE. Spin diffusion measurements: spin echo in presence of a time dependent field gradient. *J Chem Phys.* 1965;42:288-92.
10. Hakyemez B, Erdoğan C, Yıldız H, Ercan I, Parlak M. Apparent diffusion coefficient measurements in the hippocampus and amygdala of patients with temporal lobe seizures and in healthy volunteers. *Epilepsy Behav.* 2005;6:250-6.
11. Herzog AG, Kemper TL. Amygdaloid changes in aging and dementia. *Archives of Neurology.* 1980;37:625-9.
12. Atlas SW, Zimmerman RA, Bilaniuk LT, Rorke L, Hackney DB, Goldberg HI, et al. Corpus callosum and limbic system: Neuroanatomic MR evaluation of developmental anomalies. *Radiology.* 1986;160:355-62.
13. Brick J, Erickson CK (eds). *Drugs, the brain, and behavior. The Pharmacology of Abuse and Dependence.* New York: The Haworth Medical Pres. 1998;119-31.
14. Rosso IM. Amygdala and hippocampus volumes in pediatric major depression. *Biol Psychiatry.* 2005;57:21-6.
15. Szeszko PR. Amygdala volume reductions in pediatric patients with obsessive compulsive disorder treated with paroxetine: preliminary findings. *Neuropsychopharmacology.* 2004;29:826-32.
16. Chang K, Karchemskiy A, Barnea-Goraly N. Reduced amygdalar gray matter volume in familial pediatric bipolar disorder. *J Am Acad Child Adolesc Psychiatry.* 2005;44:565-73.
17. Keller SS, Wiesmann UC, Mackay CE, Denby CE, Webb J, Roberts N. Voxel based orphometry of grey matter abnormalities in patients with medically intractable temporal lobe epilepsy: effects of side of seizure onset and epilepsy duration. *J Neurol Neurosurg Psychiatry.* 2002;73:648-56.

18. Achten E, Boon P, De Kerckhove TV. Value of single-voxel proton MR spectroscopy in temporal lobe epilepsy. *Am J Neuroradiol*. 1997;18:1131-9.
19. Cendes F, Leproux F, Melanson D, Ethier R, Evans A, Peters T. MRI of amygdala and hippocampus in temporal lobe epilepsy. *J Comput Assist Tomog*. 1993;17:206-10.
20. Hakyemez B, Yücel K, Yıldırım N, Erdoğan C, Bora I, Parlak M. Morphologic and volumetric analysis of amygdala, hippocampus, fornix and mamillary body with MRI in patients with temporal lobe epilepsy. *Neuroradiol J*. 2006;19:289-96.
21. Scott SK, Young AW, Calder AJ, Hellawell DJ, Aggleton JP, Johnson M. Impaired auditory recognition of fear and anger following bilateral amygdala lesions. *Nature*. 1997;385:254-7.
22. Glaser G. Historical perspectives and future directions. Wylie E (eds). *The treatment of epilepsy: Principles and practise*. Philadelphia: Febiger Press. 1993;3-9.
23. Sander JW, Hart YM. *Epilepsy*. In: Jack MA (eds). Florida: Merit Publishing International. 1998;12-29.
24. Berkovich SF, Andermann F, Oliver AA. Hippocampal sclerosis in temporal lobe epilepsy demonstrated by magnetic resonance imaging. *Ann Neurol*. 1991;29:175-82.
25. Bonilha L, Kobayashi E, Cendes F, Li LM. The importance of accurate anatomic assessment for the volumetric analysis of the amygdala. *Braz J Med Biol Res*. 2005;38:409-18.
26. Brandt C, Glien M, Potsckha H, Volk H, Loscher W. Epileptogenesis and neuropathology after different types of status epilepticus induced by prolonged electrical stimulation of the basolateral amygdala in rats. *Epilepsy Res*. 2010;55:83-103.
27. Kalviainen R, Salmenpera T, Partanen K, Vainio P, Riekkinen P, Pitkanen A. MRI volumetry and T2 relaxometry of the amygdala in newly diagnosed and chronic temporal lobe epilepsy. *Epilepsy Res*. 1997;28:39-50.
28. Qiwen M, Jingxia X, Zongyao W, Yaqin W, Zhang S. A Quantitative MR Study of the Hippocampal Formation, the Amygdala, and the Temporal Horn of the Lateral Ventricle in Healthy Subjects 40 to 90 Years of Age. *AJNR Am J Neuroradiol*. 1999;20:207-11.
29. Geuze E, Vermetten E, Bremner JD. MR-based in vivo hippocampal volumetrics: 1. Review of methodologies currently employed. *Mol Psychiatry*. 2005;10:147-59.
30. Jackson GD, Berkovic SF, Duncan JS, Connelly A. Optimizing the diagnosis of hippocampal sclerosis with MR imaging. *AJNR*. 1993;14:753-62.
31. Cendes F, Leproux F, Melanson D, Ethier R, Evans A, Peters T. MRI of amygdala and hippocampus in temporal lobe epilepsy. *J Comput Assist Tomog*. 1993;17:206-10.
32. Reutens D, Cook M, Kingsley D. Volumetric MRI is essential for reliable detection of hippocampal asymmetry. *Epilepsia*. 1993;34:138-40.
33. Jackson GD, Berkovic SF, Tress BM, Kalnins RM, Fabinyi GC, Bladin PF. Hippocampal sclerosis can be reliably detected by magnetic resonance imaging. *Neurology*. 1990;40:1869-75.
34. Jack CR, Sharbrough FW, Twomey CK. Temporal lobe seizures: lateralization with MR volume measurements of the hippocampal formation. *Radiology*. 1990;175:423-9.
35. Berkovic SF, Andermann F, Olivier A. Hippocampal sclerosis in temporal lobe epilepsy demonstrated by magnetic resonance imaging. *Ann Neurol*. 1991;29:175-82.
36. Bronen RA, Fulbright RK, Kim JH, Spencer SS, Spencer DD, Al-Rodhan NR. Regional distribution of MR findings in hippocampal sclerosis. *AJNR Am J Neuroradiol*. 1995;16:1193-200.
37. Jack CR, Rydberg CH, Krecke KN. Mesial temporal sclerosis: diagnosis with fluid-attenuated inversion-recovery versus spin-echo MR imaging. *Radiology*. 1996;199:367-73.
38. Margerison JH, Corsellis JA. Epilepsy and the temporal lobes: a clinical, electroencephalographic and neuropathological study of the brain in epilepsy, with particular reference to the temporal lobes. *Brain*. 1966;89:499-530.
39. Dam AM. Epilepsy and neuron loss in the hippocampus. *Epilepsia*. 1980;21:617-29.
40. Babb T, Brown W. Pathological findings in epilepsy. Engel J (ed). *Surgical Treatment of the Epilepsies*. New York: Raven. 1987;511-40.
41. Jackson GD, Connelly A, Duncan JS, Grunewald RA, Gadian DG. Detection of hippocampal pathology in intractable partial epilepsy: increased sensitivity with quantitative magnetic resonance T2 relaxometry. *Neurology*. 1993;43:1793-9.
42. Tien RD, Felsberg GJ, Campi de Castro C. Complex partial seizures and mesial temporal sclerosis: evaluation with fast spin-echo MR imaging. *Radiology*. 1993;189:835-42.
43. Cendes F, Andermann F, Gloor P. MRI volumetric measurement of amygdala and hippocampus in temporal lobe epilepsy. *Neurology*. 1993;43:719-25.
44. Kim JH, Tien RD, Felsberg GJ, Osumi AK, Lee N, Friedman AH. Fast spin-echo MR in hippocampal sclerosis: correlation with pathology and surgery. *AJNR Am J Neuroradiol*. 1995;16:627-36.
45. Cheon JE, Chang KH, Kim HD. MR of hippocampal sclerosis: comparison of qualitative and quantitative assessments. *AJNR Am J Neuroradiol*. 1998;19:465-8.

This paper has been checked for language accuracy by JOSAM editors.

The National Library of Medicine (NLM) citation style guide has been used in this paper.

Suggested citation: Patrias K. Citing medicine: the NLM style guide for authors, editors, and publishers [Internet]. 2nd ed. Wendling DL, technical editor. Bethesda (MD): National Library of Medicine (US); 2007-[updated 2015 Oct 2; cited Year Month Day]. Available from: <http://www.nlm.nih.gov/citingmedicine>