

Concurrent intracranial and intramedullary spinal cord tuberculomas: a case who did not require surgical intervention

Beyin ve medüller spinal kord tüberkülozu birlikteliği: cerrahi tedaviye ihtiyaç duyulmayan bir olgu

Suda Tekin Koruk¹, Celal Calisir¹, Hasan Cece², Mehmet Refik Bayraktar¹

¹Harran University Faculty of Medicine, Department of Infectious Diseases and Clinical Microbiology, Sanliurfa, Turkey

²Harran University Faculty of Medicine, Department of Radiology, Sanliurfa, Turkey
Microbiology Sanliurfa, Turkey

Corresponding author: Suda Tekin KORUK, Harran University Faculty of Medicine, Department of Infectious Diseases and Clinical Microbiology, 63200, Sanliurfa, Tel: +90 (414) 318 30 00, Facsimile: +90 (414) 318 31 92, E-mail: suda_tekinkoruk@yahoo.com

Abstract

Central nervous system (CNS) tuberculosis is an unusual entity of tuberculosis. It usually results from rupture of superficial infective focus. Here, we report a rare case of concurrent intracranial and intramedullary spinal cord tuberculomas in an 18-year-old woman. The patient was presented with headache, diplopia, malaise, weight loss and intermittent fever. She improved well on antituberculous drugs without neurosurgical excision of the lesions. We emphasize that, in endemic areas of tuberculosis, such as Turkey, in the presence of fever, night sweats, diplopia and focal neurological deficits, one should not rule out the existence of CNS tuberculosis. Also not all cases of CNS require surgical intervention.

Keywords: Brain, extrapulmonary tuberculosis, spinal tuberculoma

Özet

Merkezi sinir sistem (MSS) tüberkülozu, tüberkülozun daha nadir rastlanan bir formudur. Genellikle yüzeysel infekte bir alanın rüptürü sonrasında yayılır. Bu yazıda 18 yaşında bir kadın hastada, çok ender görülen beyin ve medüller spinal kord tutulumunun birlikte görüldüğü MSS tüberkülozu olgusu sunulmaktadır. Hasta, cerrahi herhangi bir müdahaleye ihtiyaç duymadan antitüberküloz tedavi ile iyileşti. Türkiye gibi tüberküloz açısından endemik bölgelerde, ateş, gece terlemeleri, diplopi ve fokal nörolojik hasar varlığında MSS tüberkülozu akla getirilmelidir. Ayrıca MSS tüberkülozu olan hastaların hepsinde de cerrahi müdahaleye ihtiyaç duyulmayabilir.

Anahtar kelimeler: Beyin, ekstrapulmoner tüberküloz, spinal tüberküloz

Introduction

Tuberculosis (TB) is highly prevalent both in developing countries and across the world. In 2008, there were an estimated 8.9-9.9 million incident cases of TB (1). Central Nervous System (CNS) tuberculosis results from rupture of superficial infective focus that contains tubercule bacilli into the subarachnoid space (2). Co-occurrence of intracranial and intramedullary tuberculomas is rare; the incidence is about 2 per 1000 cases of tuberculosis afflicting the CNS (3). Here, we report a case of a concurrent intracranial and intramedullary spinal cord tuberculomas in an 18-year-old patient, whom we treated with antituberculous drugs without neurosurgical excision.

Case Report

An 18-year-old woman presented to our clinic with the complaints of intermittent fever, night sweats, headache, diplopia and a history of progressive lower extremity weakness with normal sensation in the last two months. She lives with her family in Sanliurfa, in Southern Anatolia. Southern Anatolia is the least developed region of Turkey in so far as the economic, social and health indices are considered. The patient did not cough and had sputum. She had lost 12 kilogram over several months. On admission, the patient was clear and alert. A

neurological examination revealed diplopia and bilateral leg paresis with grade 2/5 power in both lower extremities. Patellar and Achilles reflexes were increased; Babinski signs were positive, and she had stiffness in the neck. She displayed no chest radiograph abnormality. She had no sputum, so acid-fast bacilli could not be demonstrated in the sputum. Serological tests for HIV were negative. There was no significant previous medical history. No household contact with a tuberculosis patient was reported. After a two-day period, the patient began to have episodic urinary incontinence with further progression of lower extremity weakness and impaired sensations. A lumbar puncture (LP) was performed; the opening pressure was 240 mmH₂O. Examination of the cerebrospinal fluid (CSF) revealed 980 cells/mm³ (86% lymphocytes), with a protein level of 599 mg/dl (reference range 15–45 mg/dL) and glucose level of 24 mg/dL (serum glucose 114 mg/L). No microorganisms were seen on Gram, methylene blue and acid-fast stains in CSF smears. The level of adenosine deaminase (ADA) was elevated in CSF (46 IU/L, with reference range 0-6 IU/L). The tuberculin skin test was negative. She had no Bacille Calmette-Guérin (BCG) vaccine scar on her left shoulder. Laboratory studies revealed a normal complete blood count. Contrast-enhanced axial T1-weighted MRI of the lumbar spine showed extensive shaggy enhancement of the

arachnoid, nerve roots, and conus medullaris (Figure 1). Figure 2 shows marked enhancement in the basal subarachnoid cisterns. The patient was assessed by a neurosurgeon and no surgical intervention was considered.

The patient was diagnosed with CNS TB on the 10th day after admission based on her history, clinical presentation, CSF parameters and radiological findings and the elevated ADA levels. We started treatment as the patient's condition worsened and she lost consciousness. On the 22nd day after admission, CSF culture yielded *M. tuberculosis*, confirming our initial diagnosis. The patient received daily antituberculous therapy consisting of isoniazid 300 mg (H), rifampicin 600 mg (R), pyrazinamid 1500 mg (Z), ethambutol 1200 mg and pyridoxine 25 mg for 18 months (2HRZE+16HR). At the beginning of the antituberculous therapy, prednisone at 60 mg daily was given. In order to reduce cerebral edema and diminish the symptoms, the dose of prednisone was reduced after 2 weeks and discontinued by 4 weeks. Eighteen months later, the patient had recovered completely without surgery and has gained weight; her MRI showed a reduction in the lesions.

Discussion

Central nervous system involvement of TB is rare in comparison to the involvement of other systems. It is associated with high morbidity and mortality rates (4). Co-occurrence of brain and spine tuberculomas are very rare. Our case of the intracranial and intramedullary spinal cord tuberculomas was another case of CNS involvement of TB.

Hemiparesis, papilledema and seizures occur in 10-15% of patients with CNS tuberculosis (5). Similarly, on admission our patient revealed diplopia and bilateral leg paresis. TB is endemic in Turkey. Every newborn in Turkey receives one dose of Bacille Calmette-Guérin (BCG), following the recommendations of the World Health Organization's Expanded Program on Immunization, but our patient had not received BCG at birth (6). We believe that the lack of immunization,

aggravated by her poor living conditions, led to her exposure to the TB bacilli and to her illness.

Diagnosis of cerebral TB is based on clinical features, cerebrospinal fluid assays and radiological images (7). The diagnosis rests on the outcome of CSF cultures because it is often difficult to distinguish the clinical symptoms of TB meningitis from other chronic meningitis. We reached a diagnosis based on clinical features, CSF assay and contrast-enhanced MR imaging of CNS. The final diagnosis was made based on CSF culture.

Adenosine deaminase is increased in CSF in cases of TB meningitis and was elevated in the CSF of our patient (8). We suggest that the ADA level may be an early clue in the diagnosis of CNS tuberculosis.

There is no convincing evidence from clinical trials for any treatment regimen that will lead to full recovery from CNS TB (7, 9). The recommended duration of therapy in the literature is 12 months in uncomplicated cases of cerebral TB. Surgical intervention for intracranial tuberculoma is indicated if medical therapy is ineffective (4). INH and pyrazinamide are frequently used as chemotherapeutic agents against CNS tuberculosis because of their high barrier permeability (4). Most cases in the literature with intracranial and intramedullary spinal cord tuberculomas are treated with both surgical and medical therapy (3, 4). Our patient was not subjected to any surgical intervention, but was treated for 18 months with effective drug-based antituberculous therapy. In the 8th week of the therapy, she started to walk with assistance, and her vision has improved. This case points to two important conclusions. First, in areas endemic for tuberculosis, such as Turkey, in the presence of fever, night sweats, diplopia and focal neurological deficits, CNS tuberculosis should be considered. Second, not all cases of CNS require surgical intervention. Effective antituberculosis therapy for 18 months may be sufficient to improve the patient's condition and lead to recovery. Thus, although tuberculosis meningitis has a generally poor prognosis, early diagnosis and effective treatment ameliorate the course of the disease.

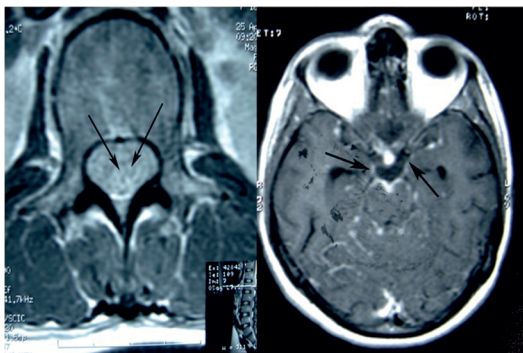


Figure 1: Contrast-enhanced axial T1 weighted lumbar spine MRI shows extensive shaggy enhancement of the arachnoid, nerve roots, and conus medullaris.

Figure 2: Contrast-enhanced axial T1 weighted MRI shows marked enhancement in the basal subarachnoid cisterns

Yazarlarla ilgili bildirilmesi gereken konular (Conflict of interest statement) : Yok (None)

References

1. Global tuberculosis control epidemiology, strategy, financing WHO Report 2009 http://www.who.int/tb/publications/global_report/2009/en/index.html
2. Bennett JE. Chronic meningitidis. In: Mandell GL, Bennett JE, Dolin R (eds). Principles and Practice of Infectious Diseases. 7th ed. Philadelphia, Churchill Livingstone. 2010. pp. 1237-42.
3. Shenoy SN, Raja A. Concurrent intramedullary and

- intracranial tuberculomas. *Neurol India* 2004; 52: 514-6.
4. Li H, You C, Yang Y, He M, Cai B, Wang X, Ju Y. Intramedullary spinal tuberculoma: report of three cases. *Surg Neurol* 2006; 65: 185-9.
5. Garcia-Monco JC. Central nervous system tuberculosis. In: Marra CM, editors. *Neurologic clinics – central nervous system infections*. Philadelphia: WB Saunders Company, 1999; 17: 737-58.
6. TC Ministry of Health. Expanded Program on Immunization, 2008. (In Turkish).

7. Kati MK. Pathogenesis, diagnosis, treatment, and outcome aspects of cerebral tuberculosis. *Med Sci Monit* 2004; 10: 215-9.
8. Thomson RB Jr, Bertram H. Laboratory diagnosis of central nervous system infections. *Infect Dis Clin North Am* 2001; 15: 1047-71.
9. World Health Organization Tuberculosis unit, Division of Communicable Diseases: Guidelines for tuberculosis treatment in adults and children in national treatment programmes. WHO Geneva, 1991: WHO/Tb/91: 1-61.