

Retrospective analysis of the incidence of intracranial physiological calcifications with cone beam computed tomography

Melis Mısırlı Gülbeş(0000-0001-8968-5955)^α, Berfu Çerci Ongun(0000-0003-2706-1914)^β,
Nimet İlke Akçay(0000-0003-3125-1358)^γ, Kaan Orhan(0000-0003-3125-1358)^λ

Selcuk Dent J, ODMFR 2019 Kongre Kitapçığı Özel Sayısı

Başvuru Tarihi: 11 Ocak 2019
Yayına Kabul Tarihi: 06 Şubat 2019

ABSTRACT

Retrospective analysis of the incidence of intracranial physiological calcifications with cone beam computed tomography

Background: The purpose of the present study was to evaluate the incidence of physiologic intracranial calcifications detected in cone beam computed tomography (CBCT) images of in a group Turkish Cypriot population.

Methods: The CBCT scans of the full head of 100 patients that met our ascertainment criteria were evaluated retrospectively for the presence of physiological intracranial calcifications.

Results: Intracranial calcification was found in 71 cases of 100 patients. The most common site of calcification was habenula with 48% followed by %14 caroticoclinoid ligament, 13% interclinoid ligament and 8% choroid plexus. In our study, petroclinoid ligament calcification was not observed at all.

Conclusion: CBCT is widely used in many scientific investigations and anatomical studies. Intracranial physiological calcification are frequent incidental findings of CBCT scans.

KEYWORDS

CBCT, intracranial calcifications, petroclinoid ligament, habenula

ÖZ

İntrakraniyal fizyolojik kalsifikasyonların görülme oranlarının konik ışınli bilgisayarlı tomografi ile retrospektif olarak incelenmesi

Amaç: Bu çalışmanın amacı, bir grup Kıbrıslı Türk popülasyonunda konik ışınli bilgisayarlı tomografi (KIBT) görüntülerinde tespit edilen fizyolojik intrakraniyal kalsifikasyon insidansını değerlendirmektir.

Gereç ve Yöntemler: Tarama kriterlerimizi karşılayan 100 hastanın KIBT görüntüleri, fizyolojik intrakraniyal kalsifikasyonların değerlendirilmesi için retrospektif olarak incelenmiştir.

Bulgular: 100 hastanın 71'inde intrakraniyal kalsifikasyonlar gözlemlenmiştir. En sık kalsifikasyon sahası % 48 ile habenula ve onu takiben % 13 interklinoid ligament, % 14 karotikoklinoid ligament, % 8 ile de koroid pleksus bulunmuştur. Çalışmamızda petroclinoid ligament kalsifikasyonu hiç gözlemlenmemiştir.

Sonuç: KIBT bilimsel araştırmalarda ve anatomi çalışmalarında sıklıkla kullanılmaya başlanmıştır. KIBT ile rastlantısal fizyolojik intrakraniyal kalsifikasyonların görüntülenmesi yaygındır.

ANAHTAR KELİMELER

KIBT, intrakraniyal kalsifikasyonlar, petroclinoid ligament, habenula

INTRODUCTION

Intracranial calcification can be either physiological or pathological. Physiological intracranial calcifications are not accompanied by diseases and do not have any pathological causes.¹The most common sites for intracranial physiological calcifications are the pineal gland, habenula, choroid plexus, falx and the basal ganglia as well as the vessel walls.² Various imaging techniques can be used to diagnose intracranial calcifications but over the last decade cone beam computed tomography (CBCT) has become one of the most preferable imaging system for assessing anatomical patterns of the head and neck area. CBCT offers high diagnostic value images with short scanning time and reduced radiation dose.^{3,4}

^α Near East University Faculty Of Dentistry, Department Of Dentomaxillofacial Radiology

^β Eastern Mediterranean University, Faculty Of Medicine, Department Of Anatomy

^γ Eastern Mediterranean University, Faculty Of Medicine, Department Of Statistics

^λ Ankara University Faculty Of Dentistry, Department Of Dentomaxillofacial Radiology; Omfs Impath Researchgroup, Department Of Imaging&pathology, Faculty Of Medicine, University Of Leuvenand Oral &maxillofacialsurgery, University Hospitals Leuven

The habenula is a pair of small nuclei which is anatomically related with epithalamus and pineal gland.⁵ Physiological habenular calcifications was in the third place after the pineal gland and the choroid plexus calcifications by 20.1%.⁶

The areas where the dura is thicker tend to calcify frequently like the falx and the petroclinoid ligaments.¹ The petroclinoid ligaments are folds of the dura mater that extends between the anterior and the posterior clinoid processes and the petrosal part of the temporal bone.⁷ The clinoid processes, which are attachment sites for the dura mater, are located on the sphenoid bone. Anterior and the posterior clinoid processes are connected to each other with interclinoid ligament (ICL). The medial and the anterior clinoid processes are connected to each other with caroticoclinoid ligament. These ligaments can sometimes get ossified. Although ossification of ICL is underestimated, it has been shown in the cadaveric studies that the presence of ossified ICL makes the removal of the anterior clinoid process more difficult and increases the risks especially in the presence of an aneurysm.^{8,9} Ossification of CCL can also be linked to clinical problems such as internal carotid artery compressions.¹⁰

The aim of this study is to evaluate the incidence of the habenula, choroid plexus and PCL calcification, ICL, and CCL ligament ossification in a group of Turkish Cypriot population by CBCT data.

MATERIAL AND METHODS

The study protocol was carried out in accordance with the principles outlined in the Declaration of Helsinki and the ethical approval was given by the Local Ethics Committee of the Scientific Researches Evaluation of Near East University (YDU/2018/64-701). In our study, cone beam computed tomography data of patients who applied to Oral, Dental and Maxillofacial Radiology clinic for various reasons were used retrospectively and full head CBCT images were included in the study. Data of 100 patients (51 female and 49 male) were analyzed by NewTom 3G (Quantitative Radiology s.r.l., Verona, Italy). The overall mean age for female patient was 36.96 (17-73 years), and for male it was 42.24 (15-74 years).

In our clinic, all CBCT scans were performed according to a standardized scanning protocol, while the patient is in a horizontal position and stationery. The investigations were performed on axial, sagittal and coronal sections according to the intracranial physiological calcification sites. Choroid plexus, habenular commissure calcifications and interclinoid, caroticoclinoid and petroclinoid ligament calcifications were evaluated.

All evaluations were performed independently by 2 observers, 1 dentomaxillofacial radiologists with 6 years and 1 research assistant in the Department of Anatomy with 4 years' experience respectively.

RESULTS

As a result of the evaluation of 100 CBCT images, 71 (71%) of the patients were identified with intracranial physiological calcification and ossification with no pathological calcification. Among these patients, 42 (59.2%) of them were male and 29 (40.8%) were female. The percentage of calcification and ossification was 85.7% in males, and 56.9% in females. The relationship between observation of calcifications and gender was found to be significant with $p=0.001$.

The most commonly observed type of calcification and ossification was found to be habenular calcification with 48% within all evaluations (Figure 1). Table 1 represents the distribution of habenular calcifications based on gender, which was found significant based on the conducted Chi-square test of independence with $p=0.028$. We found choroid plexus calcification in 8 patients and mostly recorded bilaterally. Habenular and choroid plexus calcification seen together in 6 patients.

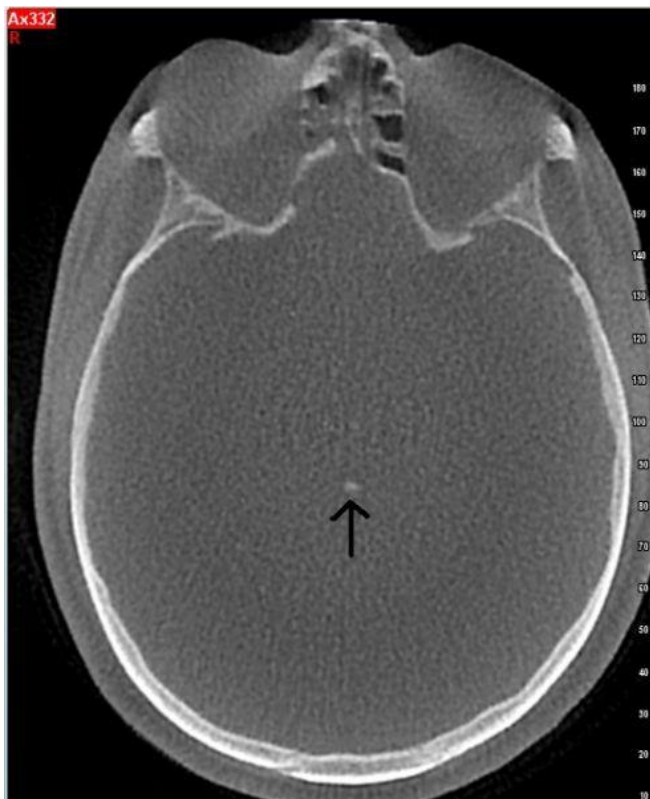

Figure 1. Axial cone beam computed tomography images of habenular calcification (black arrow)

Table 1. Distribution of habenular calcifications based on gender

| | Frequency | Percentage | p-value |
|---------------|-----------|------------|---------|
| Female | 19 | 40% | 0.028 |
| Male | 29 | 60% | 0.028 |
| Total | 48 | | |

In Table 2; distributions of right, left, bilateral, and unilateral calcifications of other regions are shown. PCL calcifications was not observed in our study. We found CCL calcifications in 14 patients (9 of them in the male and 5 of them in the female) and more frequently on the right side. ICL calcification was found in 13 patients (8 of them in the female and 5 of them in the male) of which 7 were bilateral and 6 were unilateral (Figure 2).

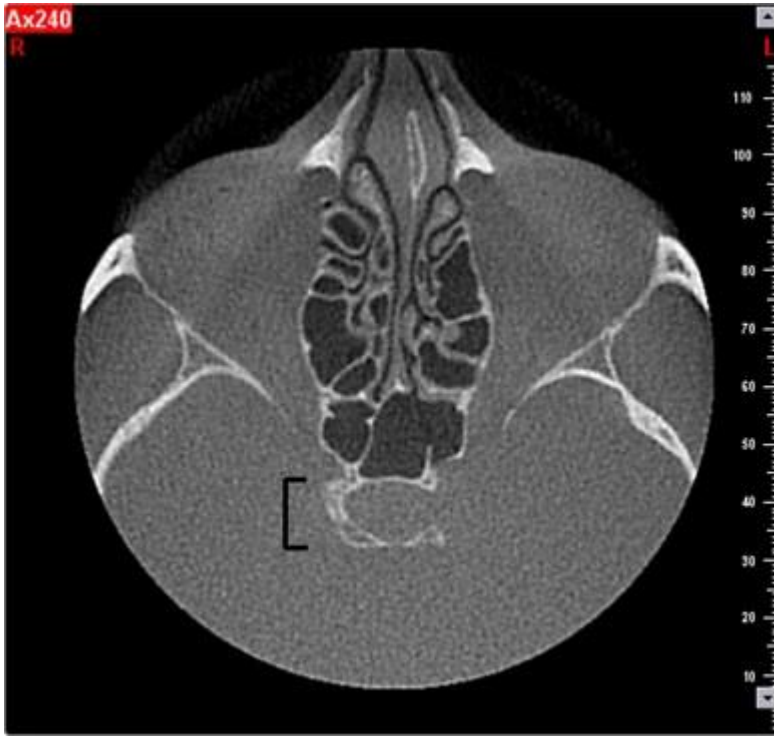


Figure 2. Axial cone beam computed tomography images of interclinoid ligament calcification (black symbol)

Table 2. Distribution of intracranial calcifications

| | Choroid Plexus | PCL | ICL | CCL |
|-------------------|----------------|-----|-----|-----|
| Right | 8 | 0 | 10 | 14 |
| Left | 7 | 0 | 10 | 8 |
| Bilateral | 7 | 0 | 7 | 8 |
| Unilateral | 1 | 0 | 6 | 6 |
| Total | 8 | 0 | 13 | 14 |

DISCUSSION

The existence of intracranial physiological calcifications and ossifications may cause clinical problems depending on the location of the calcification/ossification and the neighboring structures.¹¹ A study conducted by Kwak et al.⁴ assessed the physiological intracranial calcifications with CT found 67.7% prevalence of intracranial physiological calcifications which is similar to the prevalence we found in our study, 71%. In our study male frequency of physiological intracranial calcifications was higher like many of the previous studies^{6,12,13} and it was found to be significant ($p=0.001$).

In literature, differences have been observed in researches on the regions where physiological intracranial calcifications are most frequently located. In a recent study with the largest sample (12000) size found the choroid plexus and the pineal gland calcifications to be the most commonly observed with the frequency of %70 and 71%.¹³ Those results were similar to Kwak et al.⁴ and Daghighi et al.⁶ studies. In our study we observed the habenular calcifications to be the most common intracranial calcifications with the frequency of 48%. There are few studies

that used CBCT as a source of data^{12,14} and both studies habenular region was observed to the most common site for intracranial calcifications. Among the CBCT scans with calcifications, Sedghizadeh et al¹² found habenular calcifications at a rate of 80% likewise the rate was 67.6% in our study. Although Bayrak et al.¹⁴ found the habenular calcification to be most common site, the rate was 19.2% which lower than Sedghizadeh et al.¹² and our study. Male dominance was observed in the physiological intracranial calcifications in the previous studies.^{6,12} The same finding was observed in our research as well. Especially physiological intracranial calcifications were significantly higher in males than in females in habenular region ($p=0,028$)

As age increased the habenular calcifications increased significantly, but our research findings showed no correlation with the frequency of calcifications and increasing age. This can be due to our limited number of data.

CONCLUSION

CBCT is widely used in many scientific investigations and anatomical studies. Intracranial physiological calcification are frequent incidental findings of CBCT scans. Intracranial calcifications are frequently observed in our population. The most common type of calcification in our study was habenular calcification followed by caroticoclinoid ligament and interclinoid ligament. More studies are needed on larger patient groups to determine the relationship between calcification frequency with age and environmental factors.

REFERENCES

1. Kieffer SA, Gold LHA. Intracranial physiologic calcifications. *Semin Roentgenol* 1974;9(2):151-162.
2. Dahnert WF. *Radiology Review Manual* (Dahnert, *Radiology Review Manual*), Seventh edn. North American Edition; 2017.
3. Scarfe WC, Farman AG, Sukovic P. Clinical Applications of Cone-Beam Computed Tomography in Dental Practice. *J Can Dent Assoc* 2006;72(1):75-80.
4. Kwak R, Takeuchi F, Ito S, Kadoya S. [Intracranial physiological calcification on computed tomography (Part 1): Calcification of the pineal region]. *No To Shinkei* 1988;40(6):569-574.
5. Hikosaka O, Sesack SR, Lecourtier L, Shepard PD. Habenula: crossroad between the basal ganglia and the limbic system. *J Neurosci* 2008;28(46):11825-11829.
6. Daghighi MH, Rezaei V, Zarrintan S, Pourfathi H. Intracranial physiological calcifications in adults on computed tomography in Tabriz, Iran. *Folia Morphol (Warsz)* 2007;66(2):115-119.
7. Skrzat J, Walocha J, Jaworek JK, Mróz I. The clinical significance of the petroclinoid ligament. *Folia Morphol* 2007;66(1):39-43.
8. Ozdogmus O, Tulay CM, Saka E, Uzün I, Gurdal E, Cavdar S. Ossification of interclinoid ligament and its clinical significance. *Neuroanatomy* 2003;2:25-27.
9. Inoue T, Rhoton AL, Theele D, Barry ME. Surgical approaches to the cavernous sinus: a microsurgical study. *Neurosurgery* 1990;26(6):903-932.

10. Sanobar IS, Rahul KU, Deepak NK, Chhaya VD. Study of carotico-clinoid foramen in dry human skulls of aurangabad district. *Int J Basic Med Sci* 2012;3(5):148-154.
11. Ozdogmus O, Saka E, Tulay C, Gurdal E, Uzun I, Cavdar S. The anatomy of the carotico-clinoid foramen and its relation with the internal carotid artery. *Surg Radiol Anat* 2003;25(3-4):241-246.
12. Sedghizadeh PP, Nguyen M, Enciso R. Intracranial physiological calcifications evaluated with cone beam CT. *Dentomaxillofacial Radiol* 2012;41(8):675-678.
13. Yalcin A, Ceylan M, Bayraktutan OF, Sonkaya AR, Yuce I. Age and gender related prevalence of intracranial calcifications in CT imaging; data from 12,000 healthy subjects. *J Chem Neuroanat* 2016;78:20-24.
14. Bayrak S, Göller Bulut D, Kurşun Çakmak EŞ, Orhan K. Cone Beam Computed Tomographic Evaluation of Intracranial Physiologic Calcifications. *J Craniofac Surg* 2018;doi:10.1097/SCS.0000000000004918.