

An Exceptional Survival Term in Primary Neuroendocrine Carcinoma of the Vagina

Bouhani Malek¹, Zemni Ines¹, Ayari Yasmine¹, Boujelbene Nadia,²
Boudida Mohamed Amine¹, Chargui Riadh¹, Rahal Khaled¹

ABSTRACT

Introduction: Primary vaginal malignant tumors are rare, especially neuroendocrine tumors. The primary small cell carcinoma of the vagina is an aggressive tumor with poor prognosis because of early recurrence and metastasis.

Aim: to report the complexity of treatment of primary neuroendocrine carcinoma of vagina, and its metastasis.

Material & methods: we report a retrospective case of primary neuroendocrine carcinoma of vagina treated in our institution.

Keywords: We report a case of a 37-year-old woman who was diagnosed with a small cell carcinoma of the vagina without distant metastasis. The primary vaginal tumor was treated by surgery, brachytherapy, and chemotherapy. The first recurrence appeared seven years after initial diagnosis, which was a pulmonary metastasis, treated surgically. Seven years after this recurrence, she was treated with chemotherapy and surgery for another pulmonary metastasis. Fifteen years after the initial diagnosis, the patient underwent surgery for brain metastasis. She died eighteen months after the third recurrence.

Conclusions: This case splendidly illustrates a long survival term of a tumor known with poor prognosis.

Keywords: Carcinoma, Neuroendocrine, survival, vagina.

Geliş Tarihi: 07/04/2019

Kabul Tarihi: 31/07/2019

¹Department of oncologic surgery, Salah Azaiz Institute, Tunis, Tunisia,

²Department of anatomopathology, Salah Azaiz Institute, Tunis Tunisia.

Corresponding Author: Dr. Bouhani Malek

Adres: Department of oncologic surgery, Salah Azaiz Institute, 9th April Boulevard 1009, Tunis, Tunisia.

Tel: 0021623604048

E-posta: bouhani_malek@hotmail.fr

Introduction:

Primary vaginal malignant tumors are rare, accounting for less than 2% of all the gynecological malignant tumors (1). Primary neuroendocrine tumors of the female genital tract are also rare and particularly primary vaginal small cell carcinomas. Since Scully et al. reported the first case in 1984, the primary small cell carcinoma of the vagina is known for being a highly aggressive malignancy as all neuroendocrine tumors. They have a propensity for early widespread dissemination and the mean survival is 12 months (2, 3). Due to its rarity, there's no consensus regarding the treatment of these tumors. We report a case of primary small cell neuroendocrine carcinoma of the vagina that survived 16 years after initial diagnosis.

Case report

A 37-year-old woman, gravida 3, para 3, without significant medical history, presented to an outside institution for a vaginal cyst, which was excised. The histopathology examination demonstrated diffuse infiltration of small cells with scanty stroma. The cells show fine granular powdery chromatin, inconspicuous nucleoli, very scanty cytoplasm and high mitotic activity (Figure 1). Immunohistochemistry confirmed neuroendocrine origin by positivity for Chromogranin A (Figure 2) and Synaptophysin (Figure 3). The diagnosis of small cell neuroendocrine carcinoma was retained.

We have no clue about the margins. The patient underwent brachytherapy administered by a vaginal cylinder two weeks after surgery and was referred to our hospital for chemotherapy. At first examination at our institution, a 2 cm scar of the inferior part of the right wall of the vagina was found with no evidence of recurrence. The rest of the vagina was normal and

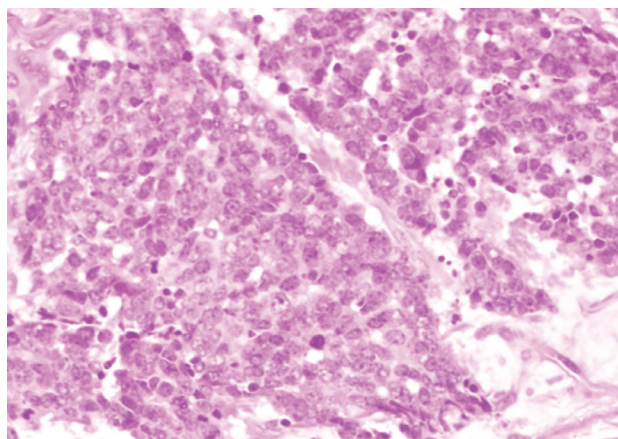


Figure 1. Neuroendocrine carcinoma showing solid sheets composed of cells with larger vesicular nuclei and mitotic activity (magnification in Hematoxylin-eosin staining x40).

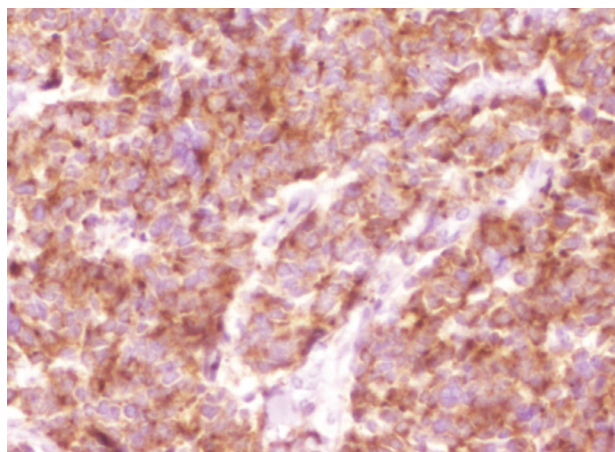


Figure 2. Tumor shows positivity for Chromogranin A (Magnification x 400).

obviously, the cervix was not involved. There was no palpable lymphadenopathy in the inguinal folds. Imaging studies were performed to evaluate the extent of disease: chest x-ray and pelvic ultrasonography were normal, abdominal computed tomography scan showed no abnormalities suggestive of metastases. Then, the patient received chemotherapy with vincristine, actinomycin, and cyclophosphamide. She was followed up with regular medical consultations. Seven years after initial presentation, she had a recurrence with pulmonary metastasis in the left lower lobe. The patient underwent wide excision of the lump and histological examination was typical of small cell neuroendocrine carcinoma. Post operatively, the patient received four courses of chemotherapy with cisplatin and etoposide. She was regularly followed up with clinical check-up, chest x-ray, and abdominal ultrasonography. Seven years after the first recurrence, another pulmonary metastasis was discovered in the right upper lobe. It was

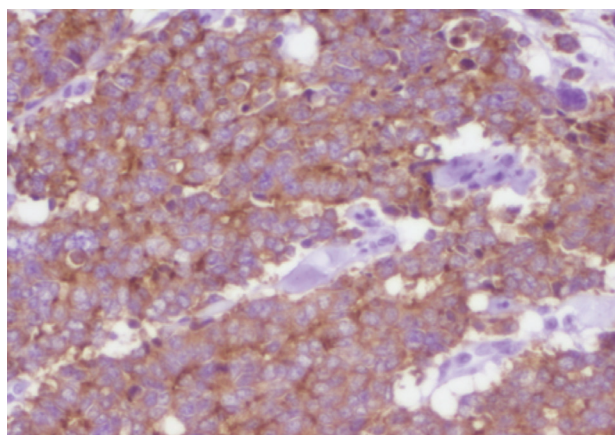


Figure 3. Tumor shows positivity for Synaptophysin (Magnification x 400).

10 cm mass invading pulmonary vessels and a trans- parietal biopsy was performed concluding to a small cell neuroendocrine carcinoma. Thus, the patient was given chemotherapy to reduce the tumor's size and a right upper lobectomy with pleurectomy was performed with adequate margins. Seven months after the last surgery, she developed signs of intracranial hypertension and left homonymous hemianopia: a brain tumor located in her occipital right lobe was diagnosed. Complete resection of the brain tumor was done and it was diagnosed as metastatic small cell neuroendocrine carcinoma at the histopathology examination. After that, the patient underwent cerebral radiation therapy. She died eighteen months after the third recurrence, sixteen years after initial diagnosis.

Discussion

Primary malignant tumors of the vagina are rare and particularly the small cell neuroendocrine carcinomas (1). Scully and al. first reported a case in 1984 and less than 27 cases have been described so far in the literature (4-6). Vaginal metastasis of carcinomas arising in another part of the body must be excluded to confirm the diagnosis, especially in sites as cervix and lung. Indeed, the primary site of neuroendocrine tumors is the lung in 95% of cases (7). Our patient only had a vaginal lesion without cervical lesion and no evidence of distant metastasis at diagnosis. Therapies used are generally inspired by the experience of patients treated for small cell carcinoma of the lung. There's no consensus for an optimal treatment as it's a rare neoplasm. Since these tumors are aggressive and have a propensity for widespread dissemination, a combination of therapies is required and recommended (2).

Different modalities were reported: chemotherapy, radiation therapy, surgery or combination of these ones. Combination chemotherapy followed by brachytherapy was used by Joseph and al (8). Mirhashemi's patient received combination chemotherapy followed by whole pelvic radiation (9). For local control, surgery and radiation therapy should be used. Surgery is only considered for small resectable lesions and radiation is associated with a high frequency of side effects in the pelvic region, which limits its delivery (10, 11). Our patient was treated with multimodality therapies: surgery followed by brachytherapy and then she had combination chemotherapy with vincristine, actinomycin, and cyclophosphamide. She had an excellent initial response. The first recurrence occurred after seven years. Recurrence and distant metastasis are common, being the main cause of mortality (12).

Neuroendocrine tumors can seldom be discovered with paraneoplastic manifestations as hypercalcemia, hypoglycemia, carcinoid syndrome or Cushing's syndrome due to the production of ectopic hormone (13). Our patient did not have these symptoms at diagnosis or with distant metastasis. The metastases were surgically treated and histopathological examination concluded to small cell neuroendocrine carcinoma three times. Our case is original for the successful treatment challenges of metastasis. Moreover, our patient is the first case who survived sixteen years after the initial diagnosis of small cell neuroendocrine carcinoma of the vagina. Survival times ranged from 5 months to 38 months and 85% of patients die within a year (3).

Discussion

Small cell carcinoma of the vagina is a low incidence disease. It's clinically aggressive with poor prognosis because of early recurrences and distant metastases. Multimodality treatment is recommended for better survival, however, more studies need to be done to establish a standardized therapy.

References

1. Scully Robert E.; Aguirre, Pascasio; DeLellis, Ronald A. Argyrophilia, serotonin, and peptide hormones in the female genital tract and its tumors. *Int J Gynecol Pathol* 1984;3(1):51-70.
2. Prasad CJ, Ray JA, and Kessler S. Primary small cell carcinoma of the vagina arising in a background of atypical adenosis. *Cancer* 1992;70(10):2484-7.
3. Miliauskas JR, Leong AS. Small cell (neuroendocrine) carcinoma of the vagina. *Histopathology* 1992;21:371-4.
4. Howitt BE, Kelly P, Mc Cluggage WG. Pathology of Neuroendocrine Tumours of the Female Genital Tract. *Curr Oncol Rep* 2017;19(9):59.
5. Bhalodia JN, Kapapura DV, and Parekh MN, Primary small cell neuroendocrine carcinoma of vagina: a rare case report. *Patholog Res Int* 2011;2011: 306921.
6. Kostamo K, Peart M, McKenzie N, Holloman C, Carlan SJ, Ge L, et al. Novel Treatment of Small-Cell Neuroendocrine of the Vagina. *Case Rep Oncol Med* 2018;2018:9157036.
7. Cohen JG, Chan JK, Kapp DS. The management of small-cell carcinomas of the gynecologic tract. *Curr Opin Oncol* 2012;24(5):572-9.
8. Joseph RE, Enghardt MH, Doering DL, Brown BF, Shaffer DW, Raval HB. Small cell neuroendocrine carcinoma of the vagina. *Cancer* 1992;70:784-9.

9. Mirhashemi R, Kratz A, Weir MM, Molpus KL, Goodman AK. Vaginal small cell carcinoma mimicking a Bartholin's gland abscess: A case report. *Gynecol Oncol* 1998;68(3):297–300.
10. Gardner GJ, Reidy-Lagunes D, Gehrig PA. Neuroendocrine tumors of the gynecologic tract: a society of gynecologic oncology (sgo) clinical document. *Gynecol Oncol* 2011;122(1):190–8.
11. Elsaleh H, Bydder S, Cassidy B, Thompson J. Small cell carcinoma of the vagina. *Australas Radiol* 2000;44(3):336–7.
12. Kaminski JM, Anderson PR, Han AC, Mitra RK, Rosenblum NG, Edelson MI. Primary small cell carcinoma of the vagina,” *Gynecol Oncol* 2003;88(3): 451–5.
13. Colleran KM, Burge MR, Crooks LA, Dorin RI: Small cell carcinoma of the vagina causing Cushing's syndrome by ectopic production and secretion of ACTH: A case report *Gynecol Oncol*. 1997;65:526–9.

