

## The Efficiency of Bioapifit® Wound Care Ointment in the Treatment of Diabetic Foot Ulcers

Višnja OREŠČANIN<sup>1\*</sup>, Zrinka MIHALIĆ<sup>2</sup>, Josipa RODIĆ<sup>3</sup>, Štefica FINDRI GUŠTEK<sup>2</sup>

<sup>1</sup> OREŠČANIN Ltd., Laboratory for Herbal Drugs Development, A. Jakšića 30, 10000 Zagreb, Croatia

<sup>2</sup> Findri-Guštek Centre Healthcare Institution, Ninska 5, Sesvete, Croatia

<sup>3</sup> Family Medicine Clinic, Vilima Korajca 19, 10000 Zagreb, Croatia

\*Corresponding author : [vorescan@gmail.com](mailto:vorescan@gmail.com)

Received : 08/08/2019  
Accepted : 11/12/2019

### Abstract

**Objective/Purpose:** The objective of this study was efficacy and safety assessment of Bioapifit® wound care ointment consisted of honey, *Cera flava*, glycerin, the oil macerates of astringent and soothing herbs combined with essential oils for the treatment of diabetic neuropathic foot ulcers of grade II. **Materials and methods:** 50 patients with Wagner grade II diabetic foot ulcers were randomized into experimental and control group (25 patients each). The experimental group was treated 28 days with Bioapifit® wound care ointment applied on the wound after cleaning with povidone iodine once a day and covered with sterile gauze and bandage during the whole course of the study. The control group wounds were cleaned with povidone iodine once a day and covered with sterile gauze and bandage during the whole course of the study without further treatment. The ulcers surface area was measured at baseline and after 14 and 28 days of the treatment. **Results:** In the end of the treatment the mean values and standard deviation of the surface area in the experimental group dropped from  $8.27 \pm 6.1$  cm<sup>2</sup> to  $0.74 \pm 0.21$  cm<sup>2</sup> for males and from  $9.01 \pm 5.9$  cm<sup>2</sup> to  $0.81 \pm 0.11$  cm<sup>2</sup> for females. Slight, insignificant decrease was also observed in the control population (up to 25%). No side-effects were observed during the course of the study. **Conclusion/Discussion:** Four weeks treatment with Bioapifit® wound care ointment resulted in complete wound closure in 84% of the patients and 91% reduction in the wound surface area in the rest of them.

**Key Words:** Diabetic Foot Ulcers, Honey, Beeswax, Herbal Macerate, Essential Oils

© CUPMAP. All rights reserved.

### 1. Introduction

Diabetic foot is defined as a foot affected by ulceration associated with neuropathy and/or peripheral arterial disease of the lower limb in a patient with diabetes. It is common complication of diabetes with prevalence between 4 and 10% of diabetic patients (Alexiadou and Doupis, 2012). Based on etiology they are divided into neuropathic and neuroischemic. The prevalence of both

types of ulcers increase with age and duration of diabetes. Although, up to 80% of ulcers will heal following the standard topical treatment up to 15% will showed no closure and between 5 and 24% of ulcers will lead to limb amputation (Alexiadou and Doupis, 2012). Neuropathic ulcers were more likely to heal compared to neuroischemic ulcers.

The treatment of diabetic foot ulcers involves debridement of the wound (surgical,

enzymatic, biological and autolytic), treatment of the infection with oral antibiotics, revascularization procedures if needed, and surgical methods. Hyperbaric oxygen therapy and negative pressure wound therapy are also used (Doupis and Veves, 2008; Alexiadou and Doupis, 2012).

Recently, topical treatment with honey or honey based dressings showed very promising results in the treatment of neuropathic foot ulcers for the management of infection, autolytic debridement, exudates removal that all together leading to the wound closure (Eddy et al., 2008; Kamaratos et al., 2014; Alam, 2017, Mohamed et al., 2015; Tsang et al., 2017; Cooper, 2017). Moreover, the product based on honey, macerates of astringent plants, glycerin and beeswax was proven highly effective in the treatment of chronic wounds (Oreščanin, 2016). Consequently, the purpose of this paper was assessment of the performance and safety of multi-component Bioapifit® wound care ointment in the treatment of Wagner grade II diabetic foot ulcers (DFU) during 28 days of topical application.

## 2. Patients and Methods

### 2.1. Study design

The study was conducted at the following locations: FINDRI GUŠTEK HEALTHCARE INSTITUTION, Ninska 5a, Sesvete, Croatia and FAMILY MEDICINE CLINIC, Vilima Korajca 19 Zagreb, Croatia. The investigator recruited the patients based on their medical history, following the predefined inclusion and exclusion criteria. The study protocol was approved by the Ethics Committee of Findri Gustek Health Care Center with EudraCT number 2019- 001379-35.

The study was designed as single blind, randomized control trial. 50 patients that met inclusion/exclusion criteria with Wagner II grade neuropathic foot ulcers were randomly selected according to the randomization code into experimental and control group.

Exclusion criteria were: ulcer grade higher than 2, patients with ankle-brachial index (ABI) lower than 0.9 or higher than 1.3, immunodeficient patients, cancer patients, diabetes mellitus type I, pregnancy or breastfeeding, ongoing oral antibiotic therapy, less than 18 years of age. All the participants signed informed consent and completed the demographic questioner. The experimental group was treated 28 days with Bioapifit wound care ointment applied once a day on the wound previously cleaned with 7.5% solution of povidone iodine solution. The ointment was applied onto cleaned wound in a thick layer, covered with sterile gauze and bandage. The participants of the control group were subjected to wound cleaning with 7.5% solution of povidone iodine and cleaned wound was covered sterile gauze and bandage. Wound cleaning and bandage changing was performed each day (once a day) for 28 consecutive days. The ulcer surface area was assessed at baseline and after 14 and 28 days of the treatment.

### 2.2. Description of Investigational Product

Bioapifit® wound care ointment is homogeneous, greasy, viscous mass of characteristic herbal odor and olive green color with pH of  $4.43 \pm 0.13$ . It consists of the following ingredients: honey (certified organic), beeswax (*Cera flava*), glycerol, the macerates of the plant species: *Plantago major* L., *Achilea millefolium* L., *Quercus robur* L., *Salvia officinalis* L., *Olea europaea* L., *Polygonum aviculare* L., *Symphytum officinale* L., *Calendula officinalis* L., *Matricaria chamomilla* L., essential oils: Australian tea tree (*Melaleuca alternifolia*), thyme (*Thymus vulgaris* ct. thymol), oregano (*Origanum vulgare*).

### 2.3. Statistical analysis

For statistical evaluation Statistica 11.0 software package was employed. The description of the treated population was done by basic statistics and frequency tables. Statistical significance was set to  $p < 0.05$  in all

the tests performed. The differences in the mean values of each parameter prior and after the therapy as well as different treatment periods were assessed by Newman-Keuls test (Oreščanin et al., 2016).

### 3. Results

#### 3.1. Description of the Population

The experimental group (Table 1) consisted of 15 males ranging from 40 to 61 ( $51.2 \pm 9.1$ ) years and 10 females with age range between 39 and 63 years ( $52.4 \pm 8.7$ ). Male population suffers from diabetes mellitus type II from 7 to 15 years ( $11.7 \pm 3.4$ ) and females from 9 to 16 years ( $14.1 \pm 4.2$ ). Presence of foot ulcers ranged between 12 and 20 months in male population ( $16.2 \pm 4.1$ ) and from 16 to 23

months ( $18.3 \pm 7.1$ ) in female participants. T-test showed no significant difference in demographic variables between males and females.

Control population showed very similar values regarding age ( $53.7 \pm 9.4$  and  $51.3 \pm 8.1$  years for males and females, respectively), duration of DM type II ( $12.4 \pm 2.8$  and  $10.1 \pm 3.2$  years for males and females, respectively) or duration of diabetic foot ulcers ( $15.8 \pm 3.7$  and  $16.4 \pm 3.6$  months for males and females, respectively). The results of t-test showed no significant difference between males and females for neither of the mentioned variables. There was no significant difference between experimental and control group for the same gender.

**Table 1.** The mean values and standard deviations for demographic variables separately for males and females for experimental and control group.

Variable	Experimental group		Control group	
	Males (N=15)	Females (N=10)	Males (N=13)	Females (N=12)
Age (yrs)	$51.2 \pm 9.1$	$52.4 \pm 8.7$	$53.7 \pm 9.4$	$51.3 \pm 8.1$
Duration of DM type II (yrs)	$11.7 \pm 3.4$	$14.1 \pm 4.2$	$12.4 \pm 2.8$	$10.1 \pm 3.2$
Duration of DFU (months)	$16.2 \pm 4.1$	$18.3 \pm 7.1$	$15.8 \pm 3.7$	$16.4 \pm 3.6$

DM-diabetes mellitus; DFU-diabetic foot ulcers

#### 3.2. Treatment efficiency

At baseline (Figure 1) both groups showed similar surface area of the ulcers regardless of group and gender with no statistically significant difference between gender and groups. Prior to the therapy the mean values and standard deviation of the surface area in the experimental group was  $8.27 \pm 6.1$  cm<sup>2</sup> and  $9.01 \pm 5.9$  cm<sup>2</sup> for males and females, respectively. After 14 days of the treatment those values dropped significantly both for males ( $5.72 \pm 1.70$  cm<sup>2</sup>,  $p=0.0479$ ) and females ( $5.31 \pm 1.74$  cm<sup>2</sup>,  $p=0.0054$ ). There was no slough present and pink granulation tissue occurred on the edge of the wounds in both genders. Following 28 days of the treatment in 86.7% of the male participants wound were completely closed while in other two participants wound surface area was

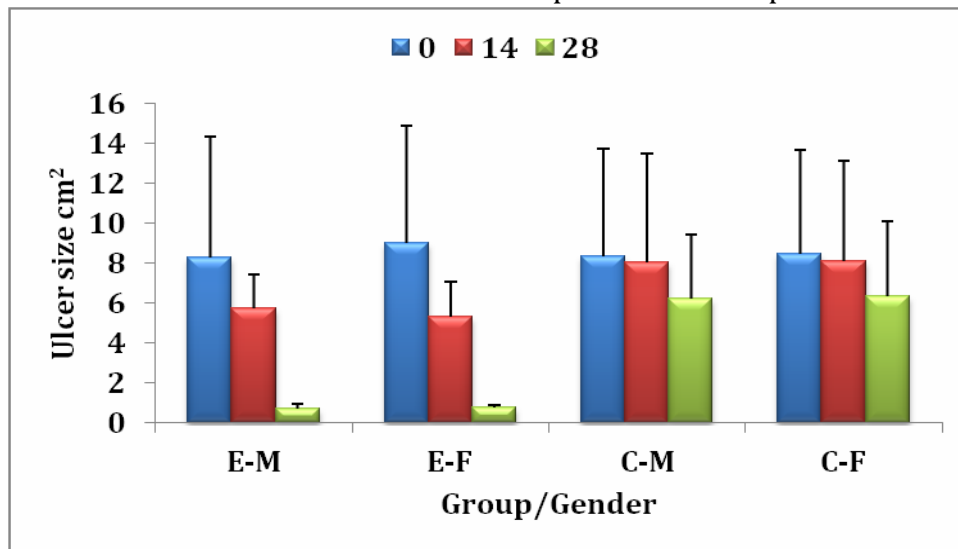
decreased to  $0.74 \pm 0.21$  cm<sup>2</sup>. In the end of the treatment in 80% of the females wound were completely closed and in the rest of them the ulcer area was  $0.81 \pm 0.11$  cm<sup>2</sup>. The percentage of the ulcer size reduction following the treatment was app. 91%.

In the control group at baseline the mean values and standard deviation of the ulcers surface area was  $8.34 \pm 5.40$  cm<sup>2</sup> and  $8.49 \pm 5.20$  cm<sup>2</sup> for males and females, respectively. After 14 days of the treatment there was no significant reduction in the ulcers surface area ( $8.07 \pm 5.43$  cm<sup>2</sup> and  $8.11 \pm 5.02$  cm<sup>2</sup> for males and females, respectively). In the end of the treatment the ulcers surface area were reduced in both genders. However, this reduction was not statistically significant. The surface area dropped for 24.5% and 25% for male and

female population, respectively. None of the ulcers closed completely. However in 9 of 25 ulcers pink granulation tissue occurred in the edge of the wounds.

From the presented results it was obvious that experimental group performed better in the healing of diabetic foot ulcers at both

follow up periods compared to the control group. T-test showed significantly higher reduction in ulcers size in male ( $p=0.0443$ ) and female ( $p=0.0111$ ) population, respectively following 14 days of the treatment as well as in the end of the treatment ( $p<0.0001$  for both genders) in the experimental compared to the control group.



**Figure 1.** Mean values and standard deviations for the mean values and standard deviation of diabetic foot ulcer area (M) and female (F) population in the experimental (E) and control (C) group at baseline (0) and 14 and 28 days of follow up period

#### 4. Discussion and Conclusion

Bioapifit® wound care ointment showed very promising results in the treatment of chronic wounds like diabetic foot ulcers. Obtained results showed complete wound closure in 84% of the patients and app. 91% reduction in the wound surface area in the rest of the patients. Slough and unpleasant odor disappeared at first follow up period (after 14 days of the treatment) while in the same time pink granulation tissue occurred on the edge of all wounds. Moreover, at first follow up there were no signs of inflammation in any of the participants.

Such beneficial effect of the ointment could be linked with the presence of 30% of honey in the product which was well known ingredient since ancient time both in folk and CAM for the treatment of chronic, hard to heal wounds. Honey, due to its low pH value (4.16)

forms an acidic wound micro-environment necessary for healing process. Absorption of wound exudates due to high osmotic effect/high sugar content and debridement of slough and necrotic tissue through autolytic debridement could be also linked with high content of honey in the product (Gethin et al., 2008; Alam et al., 2014) which was confirmed in numerous studies.

Mohamed et al. (2015) reported complete wound closure of foot ulcers no contractures or scars treated three weeks (once a day) with natural honey. The treatment of the patients with neuropathic diabetic foot ulcers with manuka honey impregnated dressings (Kamaratos et al., 2014) resulted in complete healing after  $31\pm 4$  days. Tsang et al. (2017) reported complete closure of 50% of diabetic foot ulcers and 86% and reduction in ulcers size following 12 weeks of application of Manuka honey based dressing. Application of

beri honey impregnated dressing on 179 Wagner grade I DFU resulted in 76% of closure with median wound healing time of 18 days (Imran et al., 2015).

Researchers confirmed beneficial effect of the astringent plants rich in soluble tannins in the treatment of open wounds (Odukoya et al., 2007; Abascal and Yarnell, 2005) which could be explained by surface coagulation of the proteins resulting in the shrinking of the wound as well as by forming the protective coating over damaged tissue. For that purpose oil macerates of the plants with strong astringent properties *Plantago major* L., *Achillea millefolium* L., *Quercus robur* L., *Salvia officinalis* L., *Olea europaea* L., *Polygonum aviculare* L., *Symphytum officinale* L., were included in the product formulation. Moreover, the macerates of marigold flowers (*Calendula officinalis* L.) and chamomile flowers (*Matricaria chamomilla* L.) were used due to its soothing and calming effect to the wounded skin (Oreščanin et al., 2016).

Additionally, herbal macerate was used in the formulation due to its low pH and coating effect. Moreover, the macerate created the environment with no water activity which was unsupportive for pathogens growth and replication. Glycerol was used in the formulation in order to provide enough moisture content of the wound necessary for the healing process. Beeswax was used in the formulation not only because of its emulsifying and thickening effect but also for wound isolation and protection from the microbial infection due to its excellent coating effect (Oreščanin et al., 2016). Essential oils served as natural preservatives and wound malodor correctors.

In conclusion, Bioapifit® wound care ointment with its low pH, high osmolarity, zero water activity, high astringency, excellent coating and moisturizing effect was promising alternative for the topical treatment of chronic wounds including neuropathic diabetic foot ulcers.

## Conflict of Interest

The authors have declared that they have no conflict of interest.

## References

1. Abascal, K., Yarnell, E., 2005. Botanical Treatments for Hemorrhoids. *Alternative and Complementary Therapies*, 11(6), 285-289.
2. Alam, F., Islam, M.A., Gan, S.H., Khalil, M.I., 2014. Honey: a potential therapeutic agent for managing diabetic wounds. *Evidence-Based Complementary Alternative Medicine*, Article ID 169130. doi:10.1155/2014/169130.
3. Cooper, R., 2017. The use of honey in diabetic foot ulcers. *The Diabetic Foot Journal* 20 (3), 154 - 159.
4. Doupis, J., Veves, A., 2008, Classification, diagnosis, and treatment of diabetic foot ulcers. *Wounds*, 20, 117-126.
5. Eddy, J.J., Gideonsen, M.D., Mack, G.P., 2008. Practical considerations of using topical honey for neuropathic diabetic foot ulcers: a review. *Wisconsin medical journal*, 107(4),187-190.
6. Gethin, G.T., Cowman, S., Conroy, R.M., 2008. The impact of Manuka honey dressings on the surface pH of chronic wounds. *International Wound Journal*, 5(2), 185-194.
7. Imran, M., Hussain, M.B., Baig, M., 2015. A randomized, controlled clinical trial of honey-impregnated dressing for treating diabetic foot ulcer. *Journal of College of Physicians and Surgeons Pakistan*, 25(10), 721-725.
8. Kamaratos, A.V., Tzirogiannis, K.N., Iraklianos, S.A., Panoutsopoulos, G.I., Kanellos, I.E., Melidonis, A.I., 2014. Manuka honey-impregnated dressings in the treatment of neuropathic diabetic foot ulcers. *International Wound Journal*, 11(3), 259-263.
9. Mohamed, H., Abu Salma, M., Al Lenjawi, B., Abdi, S., Gouda, Z., Barakat, N., Elmahdi, H., Abraham, S., Hamza, A.H., Al Khozaei, D., Al Majid, S., Al Majid, H., Abdini, J., Al Jaber, M., Al Masseh, F., Al Ali, A.A., 2015. The Efficacy and Safety of Natural Honey on the Healing of Foot Ulcers: A Case Series. *Wounds*, 27(4), 103-114.
10. Odukoya, O.A., Ilori, O.O., Sofidiya, M.O., 2007. Astringent herbs as vasoconstrictors in haemorrhoid therapy. *Planta Medica*, 73, 231-231.
11. Oreščanin, V., 2016. Treatment of pressure ulcers with Bioapifit® wound healing herbal ointment - a preliminary study. *IJRDO-Journal of biological science*, 2(10), 1- 15.
12. Tsang, K-K., Wai-Yung Kwong, E., Shing-Shun To, T., Wai-Yee Chung, J., Kwok-Shing Wong, T., 2017. A Pilot Randomized, Controlled Study of Nanocrystalline Silver, Manuka Honey, and Conventional Dressing in Healing Diabetic Foot Ulcer. *Evidence- Based Complementary and Alternative Medicine*, Article ID 5294890