

# LOCKING PLATE VERSUS INTRAMEDULLARY DEVICE FIXATION FOR THE DISTAL METATARSAL CHEVRON OSTEOTOMY IN HALLUX VALGUS: A RETROSPECTIVE STUDY

*Halluks Valgus Cerrahisinde Distal Metatars Chevron Osteotomisinin Kilitli Plak ve İntramedüller Cihaz ile Tespitinin Karşılaştırılması: Retrospektif Bir Çalışma*

Ahmet Sinan SARI<sup>1</sup>, Ubeydullah SEVGİLİ<sup>2</sup>, Özgün KARAKUŞ<sup>3</sup>

<sup>1,2,3</sup>Ömer Halisdemir University Teaching Hospital, Department of Orthopedic Surgery, NİĞDE, TÜRKİYE

## ABSTRACT

## ÖZ

**Objective:** Recently, an innovative intramedullary device was introduced for the fixation of the capital fragment in the distal metatarsal chevron osteotomy. The aim of the present study was to compare the outcomes of locking plate and intramedullary device fixation in the distal metatarsal chevron osteotomy in the surgical treatment of hallux valgus.

**Material and Methods:** We reviewed 29 patients (29 feet) treated with distal metatarsal chevron osteotomies fixated by locking plate or intramedullary device for hallux valgus. Locking plate fixation were used for 14 patients (14 feet) and intramedullary device fixation were used for 15 patients (15 feet).

**Results:** The mean follow-up period was 31 (6–56) months. The locking plate and intramedullary device groups did not differ significantly with respect to age, affected side, surgical time, duration of hospital stay, follow – up period or postoperative American Orthopedic Foot and Ankle Society scores ( $p>0.05$ ). The hallux valgus angle and the intermetatarsal angle decreased significantly in both the locking plate and the intramedullary device groups ( $p<0.01$ ). Two patients (14.3%) in the locking plate group and 5 patients (33.3%) in the intramedullary device group had implant removal surgery because of implant irritation but the difference in implant removal rates were not statistically significant.

**Conclusion:** We found both locking plate and intramedullary device fixation methods were effective in the fixation of distal metatarsal chevron osteotomy for correction of moderate hallux valgus. However, both locking plate and intramedullary device fixation methods were associated with a relatively high implant removal rate.

**Keywords:** Chevron osteotomy, implant removal, intramedullary device, locking plate, osteotomy plate

**Amaç:** Yakın zamanda, distal metatars chevron osteotomisinin tespitinde kullanılmak üzere yeni bir intramedüller cihaz geliştirilmiştir. Çalışmamızın amacı halluks valgus cerrahisinde yapılan distal metatars chevron osteotomisinde, kilitli plak tespiti sonuçlarını intramedüller cihaz tespiti sonuçları ile karşılaştırmaktır.

**Gereç ve Yöntemler:** Geriye dönük olarak, halluks valgus tedavisi için distal metatarsal chevron osteotomisi yapılmış ve kilitli plak veya intramedüller cihaz ile tespit edilmiş 29 hastanın 29 ayağı incelenmiştir. Kilitli plak ile tespit 14 hastada (14 ayakta) ve intramedüller cihaz tespit 15 hastada (15 ayakta) kullanılmıştır.

**Bulgular:** Ortalama takip süresi 31 aydır (6–56). Kilitli plak ve intramedüller cihaz grupları arasında hastanın yaşı, ameliyat edilen taraf, ameliyat süresi, hastanede kalış süresi, takip süresi veya postop Amerikan Ortopedik Ayak ve Ayak Bileği Skoru (AOFAS) açısından anlamlı bir fark saptanmamıştır ( $p>0.05$ ). Ameliyat sonrası dönemde halluks valgus açısı ve intermetatarsal açı ameliyat öncesi döneme göre her iki grupta da anlamlı bir şekilde azalmıştır ( $p<0.01$ ). Kilitli plak grubunda 2 (%14.3) hastada ve intramedüller cihaz grubunda 5 (%33.3) hastada implant irritasyonu sebebi ile implant çıkarma ameliyatı gerçekleştirilmiştir. Ancak implant çıkarma oranları açısından gruplar arasında anlamlı fark bulunmamıştır ( $p>0.05$ ).

**Sonuç:** Distal metatars chevron osteotomisinde hem kilitli plak hem de intramedüller cihaz tespitinin orta dereceli halluks valgusun cerrahi tedavisinde etkili olduğu bulunmuştur. Ancak hem kilitli plak hem de intramedüller cihaz tespitinin nispeten yüksek implant çıkarma oranları ile karakterize olduğu saptanmıştır.

**Anahtar Kelimeler:** Chevron osteotomisi, implant çıkarma, intramedüller cihaz, kilitli plak, osteotomi plağı



**Correspondence / Yazışma Adresi:**

Nigde Omer Halisdemir University Teaching Hospital, Department of Orthopedic Surgery, Nigde, TURKEY

**Phone / Tel:** +90 538 988 77 72

**Received / Geliş Tarihi:** 03.06.2019

**ORCID NO:** <sup>1</sup>0000-0002-5429-1929 <sup>2</sup>0000-0003-2201-2080

**Dr. Ahmet Sinan SARI**

**E-mail / E-posta:** drasinansari@gmail.com

**Accepted / Kabul Tarihi:** 15.12.2019

<sup>3</sup>0000-0002-7430-1768

## INTRODUCTION

Hallux valgus is the most common deformity of the forefoot in adults (1). Progressive subluxation of the first metatarsophalangeal (MTP) joint occurs and the first toe gradually shifts toward the second toe with medial deviation of the first metatarsal in the course of the adult hallux valgus (2). Numerous surgeries including various osteotomies have been described to correct the hallux valgus deformity (3). Among these osteotomies, the distal metatarsal chevron osteotomy has become widely utilized because of its good clinical results, technical simplicity and inherent stability (4,5). Austin and Leventen originally described the technique of the distal metatarsal chevron osteotomy with no fixation (6). However in some cases, displacement of the osteotomy fragments have been reported and since then some types of fixation including Kirschner wires, screws, plates, bio absorbable pins and monofilament wires have all been used in order to decrease the complication rates and secure the osteotomy site (7-14).

Recently, an innovative intramedullary device was introduced for the fixation of the capital fragment in the distal metatarsal chevron osteotomy (4,5,15). Bennett and Sabetta found perfect healing of the osteotomy site with this intramedullary device. They also reported a high percentage of patient satisfaction and a low complication rate in the treatment of hallux valgus with distal metatarsal chevron osteotomy (15). Matsumoto, Gross and Parekh concluded that distal metatarsal chevron osteotomy using the intramedullary device had better fixation stability and had greater shift of the capital fragment without increased risk of complications (4). However, to our knowledge no study compared the intramedullary devices used in the distal metatarsal chevron osteotomy with screw or plate fixation up to now.

The aim of the present study is to compare the outcomes of locking plate and intramedullary device

fixation methods in the distal metatarsal chevron osteotomy for the surgical treatment of hallux valgus.

## MATERIALS AND METHODS

Local ethics committee approved (Date: 09.05.2018; Decision number: 2018/262) the present study. Patients were contacted in order to obtain oral and written consents before enrollment into the study. We retrospectively evaluated 29 feet in 29 patients who underwent distal metatarsal chevron osteotomy fixated with a locking plate or an intramedullary device for symptomatic hallux valgus. Power analysis was not performed because of the retrospective nature of the study. The procedures were performed by two authors (A.S.S. and U.S.) between January 2013 and August 2017. 14 feet (14 patients) were stabilized with locking plates by one surgeon (A.S.S.) and 15 feet (15 patients) were stabilized with intramedullary devices performed by one surgeon (U.S.). This method was chosen to minimize surgical bias. Patients who had osteoarthritis of the first metatarsophalangeal joint, rheumatoid arthritis, hallux rigidus or who had revision hallux valgus surgery were excluded from the study. Age, sex, the affected side, the follow-up period, the surgical time, the duration of hospital stay data's were obtained from the patients' official records. The complications caused by the distal metatarsal chevron osteotomy were questioned by face to face interview with patients and by reviewing the patients' official records. Radiographically, hallux valgus angle (HVA) and intermetatarsal angle (IMA) were measured. The HVA was the angle between the longitudinal axis of the first metatarsus and the longitudinal axis of the first proximal phalanx and the IMA was the angle between the longitudinal axis of the first metatarsus and the longitudinal axis of the second metatarsus (Figure 1). Clinical results were calculated using the American Orthopedic Foot and Ankle Society (AOFAS) ankle-hind foot score using the radiographic measurements and the physical examination of the patients by the

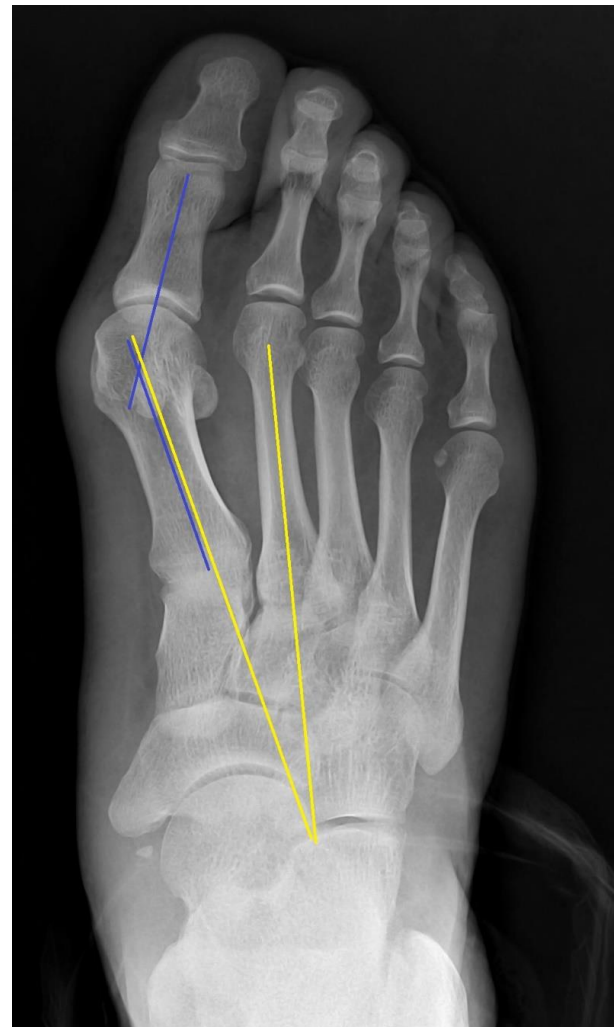
same investigator (A.S.S.) at the last follow-up of the patient. All of the radiographic measurements were performed by the same investigator (A.S.S.). The mean patient age was 45.6 (31–63) in the locking plate group and 40.0 (29–56) in the intramedullary device group. All patients were female both in locking plate and intramedullary device groups. The mean follow-up period was 31 (6–56) months.

#### *Surgical Technique*

A 5 cm slightly curved longitudinal incision was made from the midpoint of the medial side of the first metatarsal bone to the slightly distally to the medial side of the first MTP joint line. After sharp dissection of the subcutaneous tissue, L shaped capsulotomy was made and the capsule was reflected off the metatarsal head. The phalanx was adducted and bunion was resected from the metatarsal head by using an oscillating saw. Chevron osteotomy was performed with two bone cuts intersecting  $70^{\circ} - 90^{\circ}$  at the center of the metatarsal head (Figure 2). The lengths of the bone cuts were similar with each other.

In the locking plate group, the capital fragment was translated laterally approximately 50% of the width of the osteotomy line in the first metatarsal bone and a temporary K-wire fixation was achieved from dorsal to palmar direction. Fluoroscopic image was obtained to ensure the lateral shift of the metatarsal head. Next, the medial shelf of bone was partially removed using an oscillating bone saw. A six hole T shaped 2.0 mm titanium locking plate (Double Medical Technology Inc., Haicang District, Xiamen, China) was applied to the medial side of the metatarsal bone and temporarily fixed with a K-wire. First, 1.5 mm drill bit was used and the most distal hole in the proximal side of the osteotomy was drilled in an oblique fashion in order to achieve a stronger fixation. 2.0 mm cortical screw was applied to the most distal hole in the proximal side of the osteotomy in appropriate length. Then, 1.5 mm drill bit was used and the two holes in the distal side of the osteotomy were drilled. 2.0 mm locking screws were

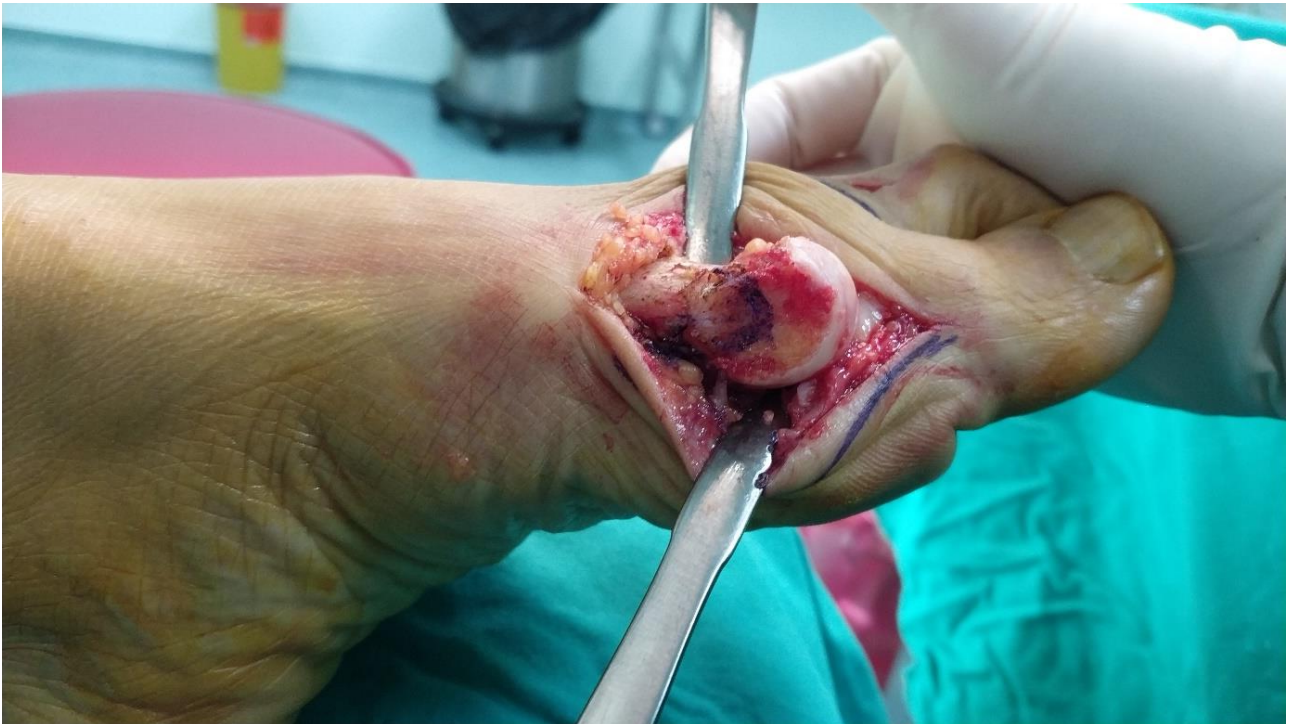applied to the holes in the distal side of the osteotomy in appropriate length. Then, the most proximal two holes were drilled by using 1.5 mm drill bit and 2.0 mm locking screws were applied to these holes. Totally, the distal side of the chevron osteotomy was fixed with two locking screws and the proximal side of the chevron osteotomy was fixed with one cortical and two locking screws (Figure 3 and 4). Fluoroscopic image was obtained again to ensure the fixation of the osteotomy site. The redundant capsule was removed and capsulorrhaphy was performed. The tissue layers were then closed in anatomic manner.



**Figure 1:** Plain radiograph of the hallux valgus angle (HVA) and intermetatarsal angle (IMA). The angle between the blue lines, the line of the longitudinal axis of the first proximal phalanx and the line of the longitudinal axis of the first metatarsal bone of the foot represents the hallux valgus angle. The angle between the yellow lines, the line of the longitudinal axis of the first metatarsal bone and the line of the longitudinal

axis of the second metatarsal bone of the foot

represents the intermetatarsal angle.



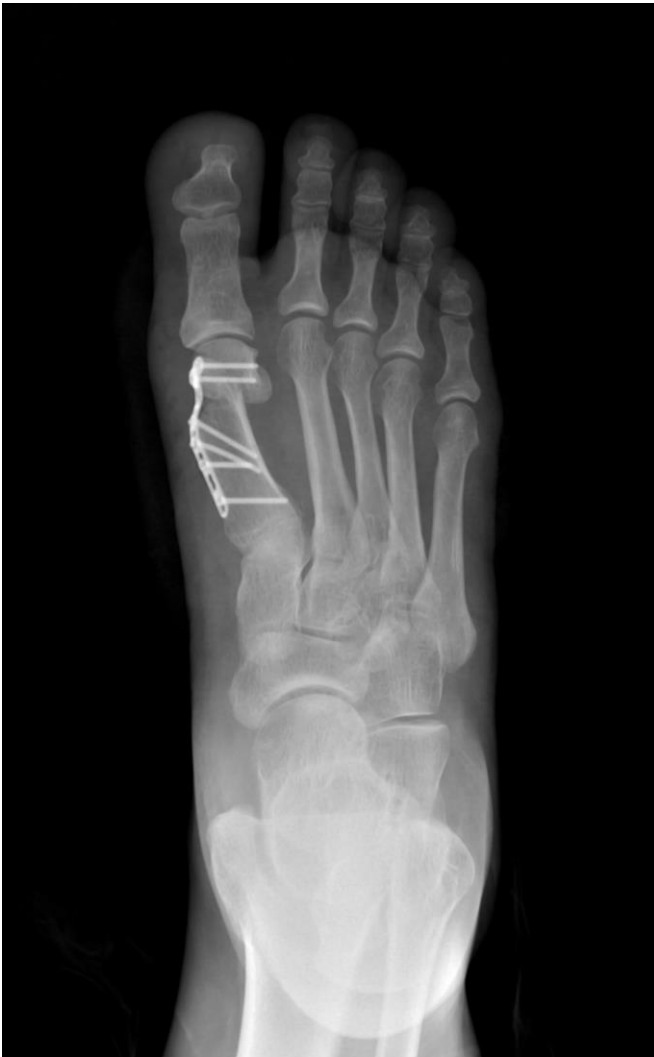**Figure 2:** Intraoperative photograph of the chevron osteotomy. Blue lines represent the chevron osteotomy line in the metatarsal head.

In the intramedullary device group, Hallux Osteotomy Locking Plate (HOL)<sup>™</sup> (ITS GmbH, Graz, Austria) was used (16). After the osteotomy, the capital fragment was translated laterally approximately 50% of the width of the osteotomy line in the first metatarsal bone and a temporary K-wire fixation was achieved from dorsal to palmar direction. Fluoroscopic image was obtained to ensure the lateral shift of the metatarsal head. Next, the stem of the intramedullary device was inserted into the intramedullary canal of the first metatarsal bone in the appropriate size. The sleeve of the locking screw bolt was attached to the stem and the

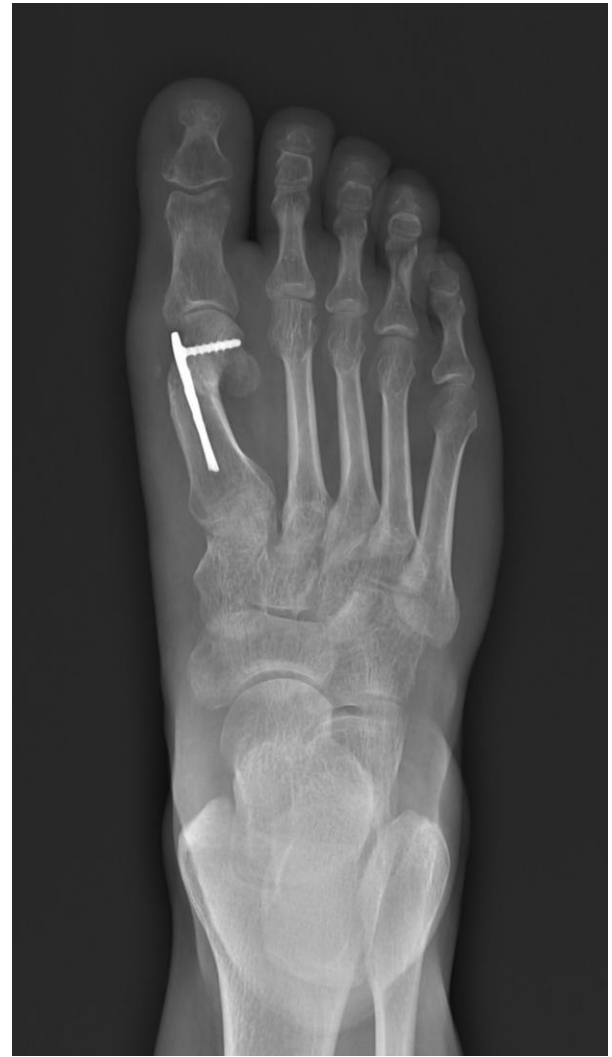metatarsal head was drilled by using 1.8 mm drill bit. The hole was measured and 3.0 mm locking screw was applied to the metatarsal head and locked to the HOL (Figure 5 and 6). Fluoroscopic image was obtained again to ensure the fixation of the osteotomy site. The redundant capsule was removed and capsulorrhaphy was performed. The tissues layers were then closed in anatomic manner.

Postoperatively all patients were worn a non weight bearing cast for three weeks. After three weeks weight bearing was allowed as tolerated.





**Figure 3:** Anteroposterior radiograph of the foot after distal metatarsal chevron osteotomy fixedated with a locking plate.

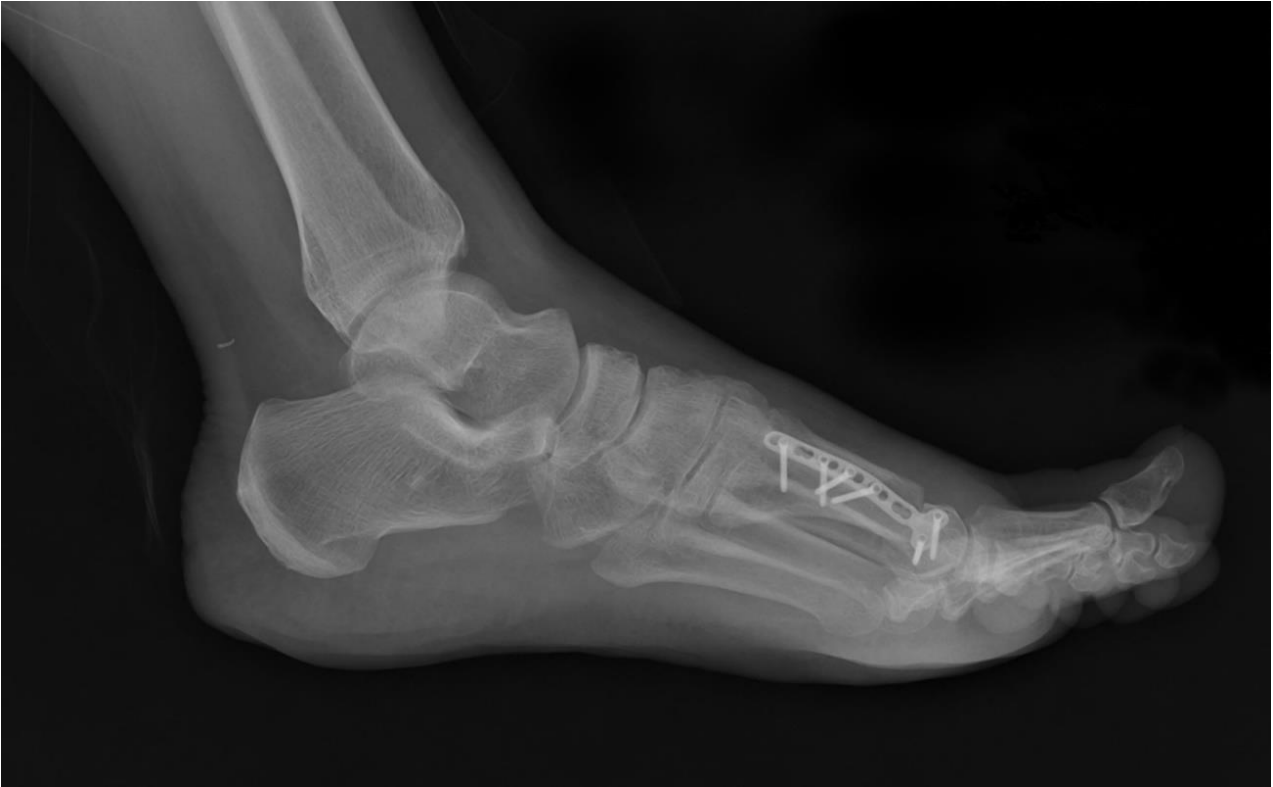

**Figure 5:** Anteroposterior radiograph of the foot after distal metatarsal chevron osteotomy fixed with an intramedullary device.

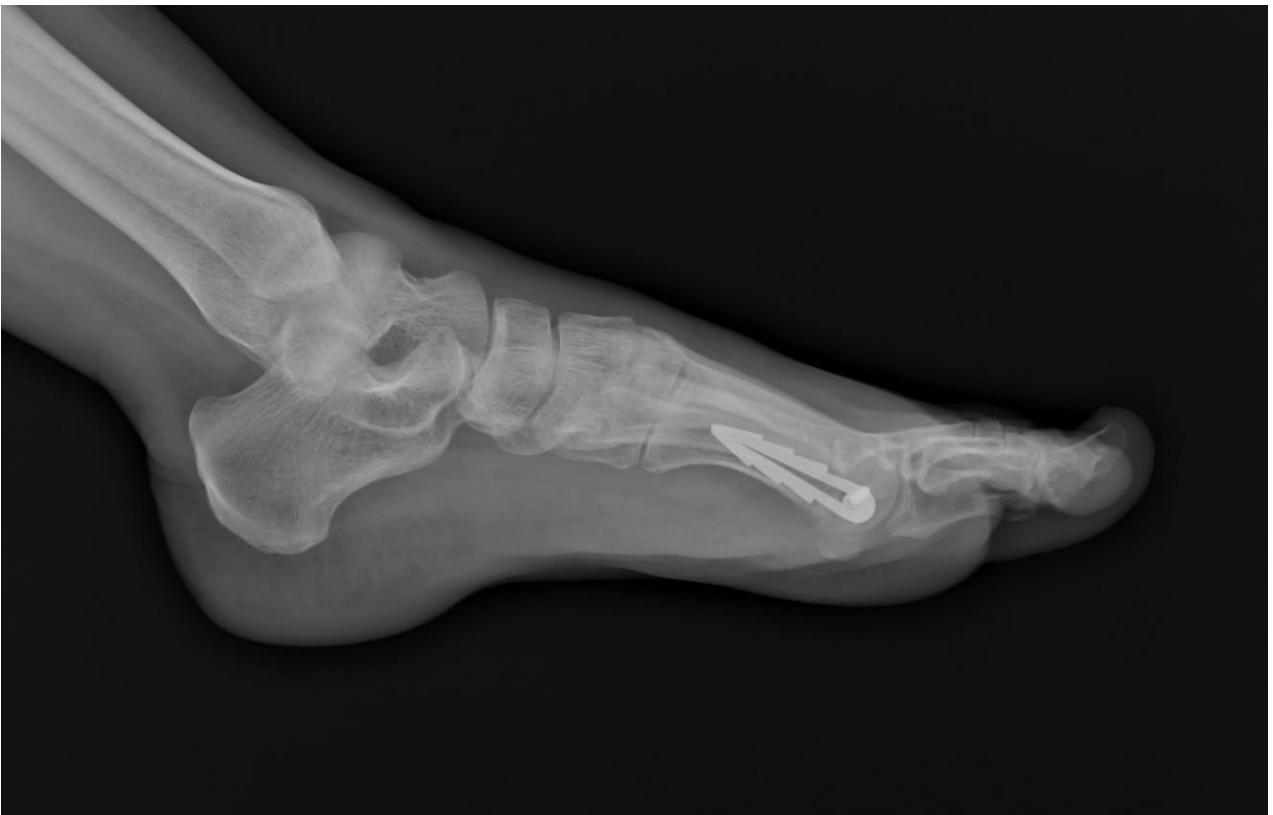#### *Statistical Analysis*

Compliance with the normal distribution of continuous variables was checked with Shapiro-Wilk test. Homogeneity of groups' variances was checked by Levene's test. Two independent group means were compared by Student's t test if parametric test assumptions were available. If assumptions are not available, Mann Whitney U test was used for comparisons of groups' medians. Two dependent groups' medians were compared by Wilcoxon test. In

order to determine relationships between categorical variables Fisher's Exact test was applied. Data analyses were performed using the Statistical Package for the Social Sciences, version 19.0 (SPSS 19, Armonk, NY: IBM Corp). A p value of  $\leq 0.05$  was considered statistically significant. The results of statistical analysis were expressed as number of observations (n), mean  $\pm$  standard deviation ( $\bar{x} \pm S_x$ ), median and minimum–maximum values [M (min–max)], percentages (%).



**Figure 4:** Anteroposterior radiograph of the foot after distal metatarsal chevron osteotomy fixedated with a locking plate.



**Figure 6:** Anteroposterior radiograph of the foot after distal metatarsal chevron osteotomy fixedated with an intramedullary device.

## RESULTS

A total of 29 feet in 29 patients included to the study. All participants were female. Fourteen feet were in the locking plate group and 15 feet were in the intramedullary device group. All the osteotomies in the present study healed with bony union within 12 weeks

after the surgery. Nonunion or delayed union were not observed. The locking plate and the intramedullary device groups did not differ significantly with respect to age ( $p=0.120$ ), affected side ( $p=0.999$ ), surgical time ( $p=0.183$ ), duration of hospital stay ( $p=0.622$ ) or the follow – up period ( $p=0.363$ ) (Table 1).

**Table 1:** Variables Between the Study Groups (Locking plate group n=14 feet in 14 patients and intramedullary device group n=15 feet in 15 patients).

		Locking Plate	Intramedullary Device	Total	p
Age (years)	mean±sd	45.57±9.93	40.0±8.78	42.69±9.61	.120
	median	43.5	40	42	
	min - max	31 – 63	29 – 56	29 – 63	
Surgical Time (Minutes)	mean±sd	39.29±8.96	33.0±12.93	36.04±11.45	.183
	median	40	30	40	
	min - max	25 – 50	20 – 50	20 – 50	
Time Spent in the Hospital (days)	mean±sd	1.93±1.0	1.80±1.08	1.86±1.03	.622
	median	2	1	2	
	min - max	1 – 4	1 – 4	1 – 4	
Follow – up Period (months)	mean±sd	33.57±16.28	28.73±11.66	31.07±14.04	.363
	median	35.5	30	34	
	min - max	8 – 56	6 – 44	6 – 56	
Affected Side		8 left	9 left	17 left	.999
		6 right	6 right	12 right	

\* T test and Mann-Whitney tests were used.

Preoperative and postoperative HVA and IMA angles are presented in Table 2. The locking plate and the intramedullary device groups did not differ significantly with respect to preoperative HVA and IMA ( $p=0.286$ ;  $0.318$  respectively) and postoperative HVA and IMA ( $p=0.598$ ;  $0.894$  respectively) (Table 2). Postoperatively, a significant decrease in the HVA and the IMA was observed both in the locking plate ( $p<0.01$ ) and the intramedullary device ( $p<0.001$ ) groups (Table 3). The locking plate and the intramedullary device groups did not differ significantly with respect to the flexion and extension

degree of the first MTP joint ( $p=0.892$ ;  $0.792$  respectively) and the AOFAS ankle-hind foot scale score ( $p=0.428$ ) (Table 4).

Avascular necrosis, infection, loss of correction or implant failure was not observed in any patients. Two patients (14.3%) in the locking plate group and 5 patients (33.3%) in the intramedullary device group had implant removal surgery because of implant irritation (Table 5). Implant removal rate among the two groups were not statistically different ( $p=0.390$ ). The patients reported significant decrease in their pain after removal of their implants.

**Table 2:** Preoperative and Postoperative HVA and IMA between the Treatment Groups (Locking plate group n=14 feet in 14 patients and intramedullary device group n=15 feet in 15 patients).

		Locking Plate	Intramedullary Device	Total	p
Pre – HVA (°)	mean±sd	27.14±5.22	29.0±3.07	28.10±4.27	.286
	median	26	30	30	
	min - max	20 – 35	25 – 32	20 – 35	
Pre – IMA (°)	mean±sd	13.71±2.27	13.0±1.6	13.35±1.95	.318
	median	13	12	12	
	min - max	12 – 18	12 – 16	12 – 18	
Post – HVA (°)	mean±sd	13.0±10.47	15.6±7.82	14.35±9.12	.598
	median	11	15	15	
	min - max	-6 – 30	6 – 29	-6 – 30	
Post – IMA (°)	mean±sd	6.29±3.22	6.6±2.5	6.45±2.82	.894
	median	7	6	6	
	min - max	2 – 11	4 – 11	2 – 11	

p values represent the comparisons of the valuables between the treatment groups. Abbreviations: (°), degrees; Pre-HVA, the hallux valgus angle measured preoperatively; Post-HVA, the hallux valgus angle measured postoperatively. Pre-IMA, the intermetatarsal angle measured preoperatively; Post-IMA, the intermetatarsal angle measured postoperatively. \* Mann-Whitney test was used.

**Table 3:** Preoperative and Postoperative HVA and IMA between the Treatment Groups (Locking plate group n=14 feet in 14 patients and intramedullary device group n=15 feet in 15 patients).

	Groups			
	Locking Plate		Intramedullary Device	
	Pre – HVA(°)	Post – HVA(°)	Pre – HVA(°)	Post – HVA(°)
Number	14	14	15	15
Mean	27.14	13.0	29.0	15.6
Median	26	11	30	15
Standard Deviation	5.22	10.47	3.07	7.82
Minimum	20	-6	25	6
Maximum	35	30	32	29
P value	<.01		<.001	
	Pre – IMA(°)	Post – IMA(°)	Pre – IMA(°)	Post – IMA(°)
Number	14	14	15	15
Mean	13.71	6.29	13.0	6.6
Median	13	7	12	6
Standard Deviation	2.27	3.22	1.6	2.5
Minimum	12	2	12	4
Maximum	18	11	16	11
P value	<.01		<.001	

p values represent the comparisons of the preoperative and postoperative values of HVA and IMA between the treatment groups. Abbreviations: (°), degrees; Pre-HVA, the hallux valgus angle measured preoperatively; Post-HVA, the hallux valgus angle measured postoperatively. Pre-IMA, the intermetatarsal angle measured preoperatively; Post-IMA, the intermetatarsal angle measured postoperatively. \* Wilcoxon signed rank test was used.



**Table 4:** Postoperative Flexion and Extension of the First MTP joint and the AOFAS Score between the Treatment Groups (Locking plate group n=14 feet in 14 patients and intramedullary device group n=15 feet in 15 patients).

		<b>Locking Plate</b>	<b>Intramedullary Device</b>	<b>Total</b>	<b>p</b>
MTP Joint Flexion (°)	mean±sd	25.71±14.26	26.0±16.17	25.86±15.0	.892
	median	20	15	20	
	min - max	10 – 45	10 – 45	10 – 45	
MTP Joint Extension (°)	mean±sd	25.0±16.64	20.8±11.18	22.83±13.99	.792
	median	25	20	20	
	min - max	10 – 60	5 – 35	5 – 60	
AOFAS	mean±sd	80.22±10.01	84.4±17.79	82.38±14.47	.428
	median	85	95	85	
	min - max	68 – 95	62 – 100	62 – 100	

Abbreviations: (°), degrees; MTP, metatarsophalangeal; AOFAS, the American Orthopedic Foot and Ankle Society (AOFAS) ankle – hind foot score. \* Mann-Whitney test was used.

**Table 5:** Implant Removal Rate between the Treatment Groups (Locking plate group n=14 feet in 14 patients and intramedullary device group n=15 feet in 15 patients).

		<b>Locking Plate</b>	<b>Intramedullary Device</b>	<b>Total</b>	<b>p</b>
Need For Implant Removal	Yes	2 (14.3%)	5 (33.3%)	7 (24.1%)	.390
	No	12 (85.7%)	10 (66.7%)	22 (75.9%)	

\* Mann-Whitney test was used.

## DISCUSSION

The distal metatarsal chevron osteotomy has been widely accepted in the surgical treatment of the mild to moderate and occasionally severe hallux valgus deformity (3-9). There are several techniques for the fixation of the metatarsal head including K wires, screws, plates, bio absorbable pins and monofilament wires (7-14).

Recently, an innovative intramedullary device was introduced for the fixation of the capital fragment in the distal metatarsal chevron osteotomy (4,5,15). Palmanovich and Myerson claimed that relatively high lateral translation of the metatarsal head could be obtained and be fixed by a stable intramedullary device even in some of the severe hallux valgus deformities and necessity of the proximal metatarsal osteotomy could be decreased by the intramedullary device

fixation in these severe deformities (5). In another study, Bennett and Sabetta found perfect healing of the osteotomy site and high patient satisfaction rate with this intramedullary device (15). In a study by Matsumoto, Gross and Parekh it was concluded that distal metatarsal chevron osteotomy using the intramedullary device had greater fixation stability and had higher lateral translation of the metatarsal head without increased risk of complications (4). Although intramedullary device fixation of the distal metatarsal chevron osteotomy yielded good results, to our knowledge no study compared the intramedullary devices used in the distal metatarsal chevron osteotomy with screw or plate fixation up to now. In the present study, we retrospectively evaluated 29 feet in 29 patients who underwent the distal metatarsal chevron osteotomy fixated with a locking plate or an intramedullary device for moderate hallux valgus. In

our study, the intramedullary device called Hallux Osteotomy Locking Plate™ (HOL) used for the fixation of the capital fragment in the distal metatarsal chevron osteotomy had some differences as compared with the intramedullary device called Mini Maxlock Extreme™ ISO Plate System (Wright Medical Group N.V. Memphis, Tennessee, USA) (ISO plate) used in the studies of Bennett et al., Palmanovich et al. and Matsumoto et al (4,5,15). First, in the HOL there is only one 3.0 mm cancellous screw for the capital fragment fixation locked to the medullary stem instead of two 2.4 mm cortical screws for the capital fragment fixation locked to the medullary stem in the ISO plate (16,17). Second, medullary fixation can be achieved by press fit anchorage of the stem to the medullary canal of the first metatarsal bone in the HOL instead of one 2.4 mm locking cortical screw fixation of the stem to the first metatarsal bone in the ISO plate. However, the basic concepts of the HOL and the ISO plate seem similar. Both the HOL and ISO plate resists metatarsal head displacement with screw fixation of the capital fragment and with their broad surfaces by confronting the medially displacing forces of the metatarsal head. We found that both locking plate and intramedullary device fixation techniques were capable of decreasing HVA and IMA angles significantly in the distal metatarsal chevron osteotomy in the treatment of moderate hallux valgus. However, there was no significant difference in the correction amount of HVA and IMA between locking plate and intramedullary device fixation techniques postoperatively. The surgical time, the duration of hospital stay, postoperative flexion and extension degree of the first MTP joint and the postoperative AOFAS ankle-hind foot scale scores also did not differ significantly between the locking plate and intramedullary device fixation groups.

The utilization of the metallic alloy implants could have been complicated with implant irritation and implant removal surgery may be warranted in some

situations. In our study, the locking plate and the intramedullary device both had low profile feature. However, 2 patients (14.3%) in the locking plate group and 5 patients (33.3%) in the intramedullary device group required implant removal surgery because of implant irritation. In medical literature, the need for secondary surgery for implant removal has ranged from 2% to 15%, according to various studies (18). In our study, the implant removal rate both in the locking plate and in the intramedullary device groups were higher than previously reported.

There are some limitations in our study. First the present study is retrospective. Second, the sample size of the present study is small. Prospective studies with larger sample size and with longer follow – up periods are clearly needed to determine the correction ability of the intramedullary devices in HVA and IMA in hallux valgus surgery.

We hypothesized that fixation of the distal metatarsal chevron osteotomy with the intramedullary device might provide better correction of the HVA and IMA postoperatively as compared to locking plate fixation. However, there was no significant difference between locking plate and intramedullary device fixation methods with respect to the correction amount of HVA and IMA. In conclusion, these methods both are effective in the fixation of distal metatarsal chevron osteotomy for correction of moderate hallux valgus. However, the locking plate and the intramedullary device fixation techniques may be associated with a high implant removal rate than expected.

*Conflict of Interests:* None.

*Acknowledgements:* We thank to Emre Demircay, MD for his effort in the manuscript reviewing process.

## REFERENCES

1. Hecht PJ, Lin TJ. Hallux valgus. Med Clin North Am. 2014;98(2):227-32.
2. Smith BW, Coughlin MJ. Treatment of hallux valgus with increased distal metatarsal articular

- angle: Use of double and triple osteotomies. *Foot Ankle Clin.* 2009;14(3):369-82.
3. Komur B, Yilmaz B, Kaan E, Yucel B, Duymus TM, Ozdemir G, Guler O. Mid-term results of two different fixation methods for chevron osteotomy for correction of hallux valgus. *J Foot Ankle Surg.* 2018;57(5):904-9.
  4. Matsumoto T, Gross CE, Parekh SG. Short-term radiographic outcome after distal chevron osteotomy for hallux valgus using intramedullary plates with an amended algorithm for the surgical management of hallux valgus. *Foot Ankle Spec.* 2019;12(1):25-33.
  5. Palmanovich E, Myerson MS. Correction of moderate and severe hallux valgus deformity with a distal metatarsal osteotomy using an intramedullary plate. *Foot Ankle Clin.* 2014;19(2):191-201.
  6. Austin DW, Leventen EO. A new osteotomy for hallux valgus: A horizontally directed “V” displacement osteotomy of the metatarsal head for hallux valgus and primus varus. *Clin Orthop Relat Res.* 1981;(157):25-30.
  7. Andrews BJ, Fallat LM, Kish JP. Screw versus plate fixation for chevron osteotomy: A retrospective study. *J Foot Ankle Surg.* 2016;55(1):81-4.
  8. Knecht JF, Van Pelt WC. Austin bunionectomy with kirschner wire fixation. *J Am Podiatry Med Assoc.* 1981;71(3):139-44.
  9. Kissel CG, Unroe BJ, Parker RM. The offset “V” bunionectomy using cortical screw and buried Kirschner wire fixation. *J Foot Ankle Surg.* 1992;31(6):560-77.
  10. Quinn MR, Di Stazio J, Kruljac SJ. Herbert bone screw fixation of the Austin bunionectomy. *J Foot Surg.* 1987;26(6):516-9.
  11. Barca F, Busa R. Austin/chevron osteotomy fixed with bioabsorbable poly-L-lactic acid single screw. *J Foot Ankle Surg.* 1997;36(1):15-20.
  12. Winemaker MJ, Amendola A. Comparison of bioabsorbable pins and Kirschner wires in the fixation of chevron for hallux valgus. *Foot Ankle Int.* 1996;17(10):623-8.
  13. Buckenberger RK, Goldman FD. Chevron bunionectomy fixation: in vitro stability assessment of plate-and-screw system compared with Kirschner wire. *J Foot Ankle Surg.* 1995;34(3):266-72.
  14. Yearian PR, Brown T, Goldman FD. Chevron bunionectomy with microplate and screw fixation: a retrospective follow-up of 26 feet. *J Foot Ankle Surg.* 1996;35(6):532-6.
  15. Bennett GL, Sabetta JA. Evaluation of an innovative fixation system for chevron bunionectomy. *Foot Ankle Int.* 2016;37(2):205-9.
  16. Hallux Osteotomy Locking Plate™ (ITS GmbH, Austria) Official Brochure. Date of acces: 04.10.2018: [http://www.its-implant.com/images/pdfs/en/HOL\\_en.pdf](http://www.its-implant.com/images/pdfs/en/HOL_en.pdf).
  17. Mini maxlock extreme™ (Wright Medical Group N.V., USA) Official Brochure. Date of acces: 04.10.2018: [http://www.wmtemedia.com/ProductFiles/Files/PDFs/SET-604-017\\_EN\\_LR\\_LE.pdf](http://www.wmtemedia.com/ProductFiles/Files/PDFs/SET-604-017_EN_LR_LE.pdf).
  18. Windhagen H, Radtke K, Weizbauer A, Diekmann J, Noll Y, Kreimeyer U et al. Biodegradable magnesium-based screw clinically equivalent to titanium screw in hallux valgus surgery: short term results of the first prospective, randomized, controlled clinical pilot study. *Biomed Eng Online.* 2013;12(1):62-8.