

JUVENILE AGGRESSIVE CEMENTOOSIFYING FIBROMA OF MAXILLA: A CASE REPORT

Mounesh kumar C D¹, Suresh K V^{2*}, Mustaq I Parkar³, Neelima Malik⁴, Nilesh Patil⁵

1. Dr., MDS, Senior lecturer, Department of Oral & maxillofacial surgery, School of Dental Sciences, Krishna Institute of Medical Sciences, Deemed University, Karad, Satara (District), Maharashtra (State), India.
2. Dr., MDS, Senior lecturer, Department of Oral Medicine and Radiology, School of Dental Sciences, Krishna Institute of Medical Sciences, Deemed University, Karad, Satara (District), Maharashtra (State), India.
3. Dr., MDS, Professor, Department of Oral & maxillofacial surgery, School of Dental Sciences, Krishna Institute of Medical Sciences, Deemed University, Karad, Satara (District), Maharashtra (State), India.
4. Dr., MDS, Professor and HOD, Department of Oral & maxillofacial surgery, School of Dental Sciences, Krishna Institute of Medical Sciences, Deemed University, Karad, Satara (District), Maharashtra (State), India.
5. Dr., MDS, Senior lecturer, Department of Oral & maxillofacial surgery, School of Dental Sciences, Krishna Institute of Medical Sciences, Deemed University, Karad, Satara (District), Maharashtra (State), India.

Abstract

Central Cemento Ossifying Fibromas [COF] are uncommon benign fibroosseous lesions of the jaw thought to originate from the periodontal ligament.

Presence of cementum or bone differentiates the lesion into cementifying fibroma or ossifying fibroma respectively while lesions with mixture of both cementum and bone are called COF. These lesions have overlapping clinical, radiologic and pathologic features causing difficulty in diagnosis.

The juvenile form is clinically more aggressive and have higher recurrence rate. We describe an unusual case of juvenile COF in 13 years old girl which was mimicking Calcifying Epithelial Odontogenic Tumor.

Case report (J Int Dent Med Res 2012; 5: (2), pp. 106-109)

Keywords: Cementoossifying Fibromas, Fibroosseous Lesions, Cementifying Fibroma, Ossifying Fibroma.

Received date:

Accept date:

Introduction

Central COF is a distinct form of rare benign fibroosseous tumor composed of metaplastic bone, cementum, and fibrous tissue¹.

It occurs more frequently in women than in men. When this tumor arises in children, it is called as juvenile aggressive COF². It occurs between 20 and 40 years of age. Most COF are small and incidentally diagnosed with routine dental radiographs.

With larger lesions, patients may complain of slowly enlarging mass leading to

facial asymmetry. Very few cases have been reported with maxillary arch involvement. We report a rare case of COF who's clinical, imaging and histological characteristics were unique.

Case Report

A 13-years old girl presented to the department of oral medicine and radiology with a slowly enlarging mass in the left upper back tooth region since two weeks. Physical examination revealed a 4 X 3 cm hard, non-tender mass with smooth surface and the patient presented an asymmetric expansion of the left maxilla [Figure 1]. Panoramic radiograph showed an irregular but well bordered, opacification of the left maxilla. There were retained deciduous canine, and molars with impacted permanent premolars [Figure 2]. CT demonstrated a large well-defined, lesion with mixed-density. A mass filling the left maxillary sinus was noted. The mass extended from the hard palate to the lateral maxillary sinus wall [Figure 3,4]. A biopsy of the lesion confirmed

*Corresponding author:

Dr Suresh K V,
Senior lecturer, Department of Oral Medicine and Radiology,
School of Dental Sciences, Krishna Institute of Medical Sciences,
Deemed University,
Karad, Satara (District), Maharashtra (State), India.

Email: dr_suri88@yahoo.co.in / dr.suri88@gmail.com

the lesion as Cemento Ossifying Fibroma [Figure 5]. Complete surgical excision was performed through a transoral approach [Figure 6].

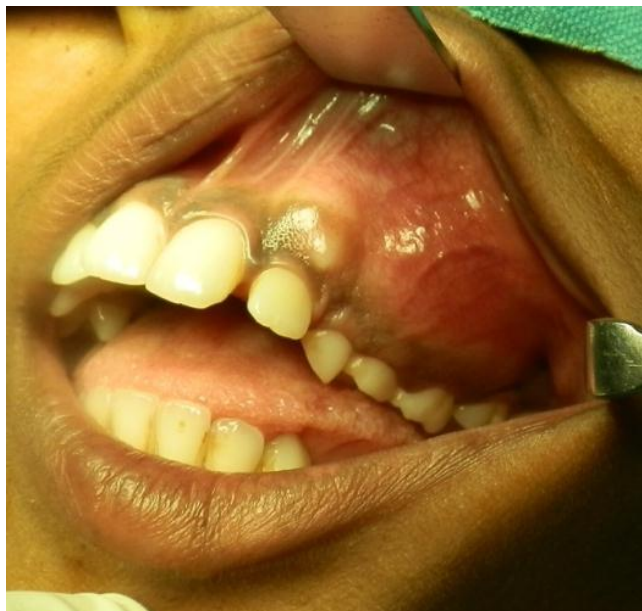

Figure 1. Diffuse bony swelling in left maxillary arch.

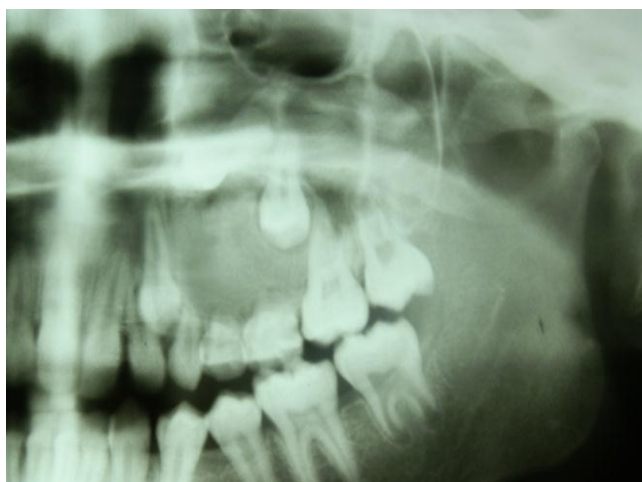

Figure 2. Cropped Panoramic showing well defined radiopacity with impacted canine, first & second premolars & retained deciduous canine & molars.

Discussion

Most benign fibro-osseous lesions of jaws are asymptomatic and slowly progressing. The hybrid name central COF is used because there is a spectrum of fibroosseous lesions that arise from the periodontal ligament, ranging from those with only deposition of cementum to those with only deposition of bone¹.

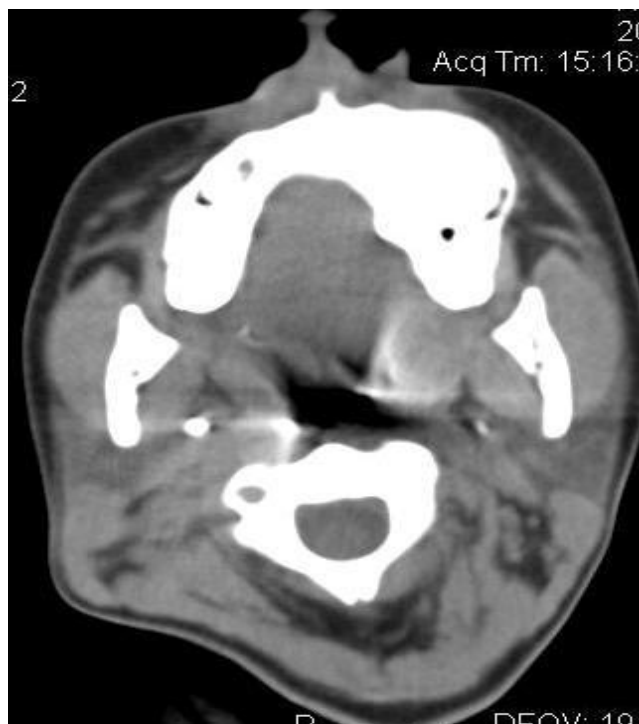


Figure 3. Axial CT view at level of maxilla showing buccal expansion.

As the presence of both of these substances is seen in many of the lesions, COF is the most accurate histologic term, but it can be interchanged with either central ossifying fibroma or central cementifying fibroma². There is no apparent clinical or radiologic difference between the COF or central ossifying fibroma, so the hybrid central COF works well for radiology, too. Rare reports of lesions behaving in an aggressive fashion, diagnosed as “aggressive”, “juvenile” or “active” COF, have appeared in literature³.

Clinically, the tumor present as a slow-growing intrabony mass most often located in the region of the mandibular premolars and molars in contrast to the posterior maxillary location of our case. Although COF of the mandible are common, central COF of the maxilla are unusual tumors². The swelling is usually asymptomatic, until they cause expansion.

Tumor may cause root resorption or displacement of neighboring teeth. These phenomena were not noticed in our patient. One remarkable finding is the large size of the maxillary tumor in our case at the time of diagnosis, probably attributable to the large amount of available space in the maxillary sinus into which they could expand.

An unusual clinical presentation with apparent aggressive and destructive growth may be expected when the lesion is encountered in a younger patient, especially below the age of 15 years, similar to the present case⁴.

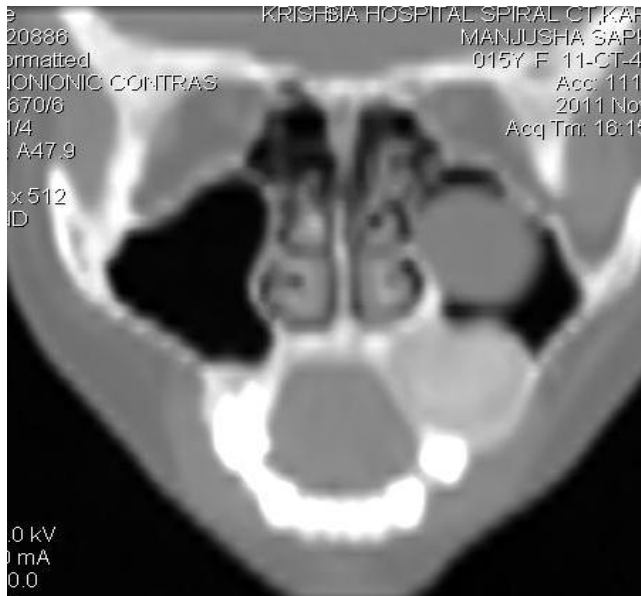


Figure 4. Coronal CT scan of maxilla showing tumor expanding mediolaterally, obliterating left maxillary antrum, and displacing floor of left antrum and well defined mucosal polyp in left maxillary sinus.

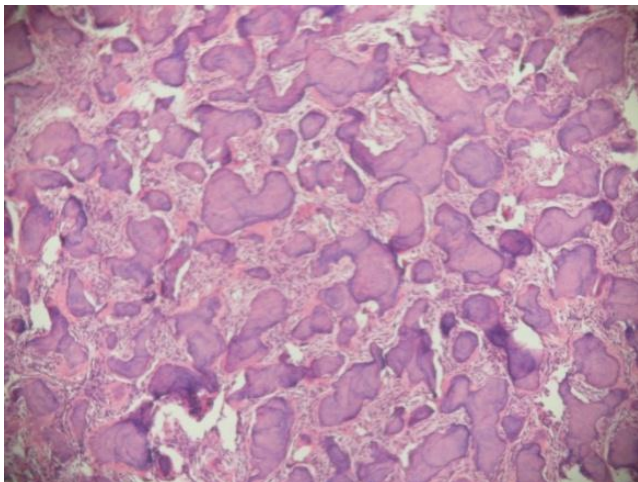


Figure 5. Photograph showing histopathological picture of lesion.

In the early stages, COF appears as radiolucent lesion with no internal radiopacities. With maturity of the lesion there is increasing calcific flecks progressing ultimately to an extremely radiopaque mass. The growth pattern of the mass is centrifugal so grows equally in all

directions presenting therefore as a well circumscribed mass. They maintain a spherical shape, expand the surrounding cortical bone without cortical perforation, and may cause tooth divergence. This was in accordance with our case⁵.

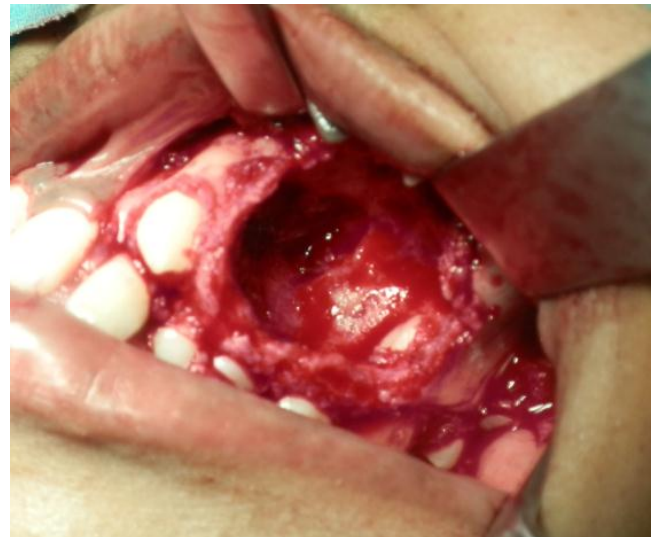

Figure 6. Intraoperative photograph showing exposed tumour.

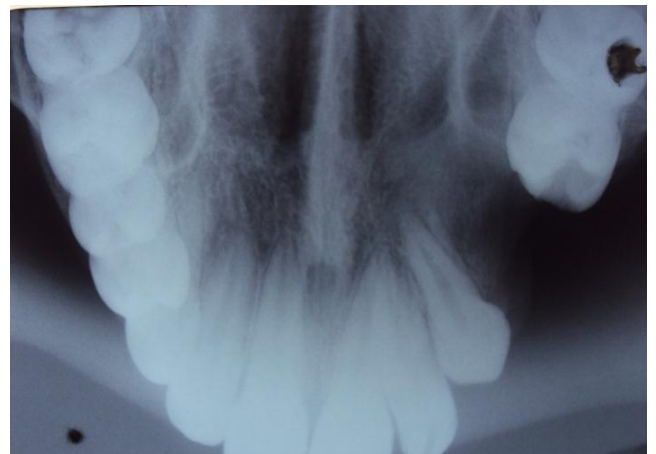


Figure 7. Postoperative maxillary occlusal radiograph after 6 months.

The differential diagnosis includes other lesions that contain radiopacities within a well defined.

Radiolucent mass: chondrosarcoma or osteosarcoma, fibrous dysplasia, odontogenic cysts, calcifying odontogenic cysts, and calcifying epithelial odontogenic tumors.⁶

The well-defined border of the COF helps differentiate it from the aggressive sarcomas and carcinomas. Fibrous dysplasia has a characteristic “ground glass” appearance not

seen in the COF. The radiologic differentiation of COF from Gorlin cysts and Pindborg tumors is difficult; hence the final diagnosis is based on histologic appearance. Pindborg tumors also have a high association with impacted teeth⁶.

Histopathologic examination shows irregularly shaped calcifications within a hypercellular fibrous connective tissue stroma. The calcifications are extremely variable in appearance and represent various stages of bone and cementum deposition. Histologic differentiation between osteoid and cementum is difficult. Maxillary COF tend to display a greater degree of immaturity than that seen in mandibular lesions, but there is no reliable pattern useful to distinguish between maxillary and mandibular lesions⁷.

COF usually “shell out” easily at surgery, but maxillary lesions are more difficult to remove completely than mandibular COF. This may be attributable to the difference in bone character between the mandible and maxilla and to the available space for expansion in the maxillary sinus. The recurrence rate of maxillary COF is unknown, but it is likely to be higher because of the greater difficulty of their surgical removal and larger size at the time of presentation^{6,7}.

The prognosis after surgical removal and curettage is usually good⁷. This was confirmed in our case, since repair of the affected area was found to be correct one year after treatment – though longer follow-up is required.

Our case was unusual in many ways. First of all the history of our patient was very short and clinical presentation was simulating CEOT with impacted premolars and canine. Such a clinical presentation has been reported in a small series of cases. Secondly, our case was reported in 13 year old girl in maxillary arch and the epicenter of the mass was located in the crown of left premolars resulting in failure of the premolars to erupt. There are only few isolated case reports of COF presenting in maxillary unerupted tooth.

Conclusions

Although juvenile COF is an uncommon clinical entity, Cosmetic and dental occlusal problems are often the first manifestations of these lesions. Its aggressive local behavior shows that it is important to make an early diagnosis and apply the appropriate treatment.

Declaration of Interest

The authors report no conflict of interest and the article is not funded or supported by any research grant.

References

1. Waldron CA, Giansanti JS. Benign fibro-osseous lesions of the jaws: a clinical-radiologic-histologic review of sixty-five cases. *Oral Surg* 1973; 35:340–350.
2. Bertrand B, Ely P, Cornelius JP, Gosseye S, Clotuche J, Gilliard C. Juvenile aggressive cemento-ossifying fibroma: case report and review of the literature. *Laryngoscope* 1994; 103:1385–1390.
3. Mehta D, Clifton N, McClelland L, Jones NS. Paediatric fibro-osseous lesions of the nose and paranasal sinuses. *Int J Pediatr Otorhinolaryngol.* 2006 Feb; 70(2):193-9.
4. Liu Y, Wang H, You M, Yang Z, Miao J, Shimizutani K et al. Ossifying fibromas of the jaw bone: 20 cases. *Dentomaxillofac Radiol.* 2010; 39:57-63.
5. Su L, Weathers DR, Waldrom CA. Distinguishing features of focal cemento-ossifying dysplasia and cemento-ossifying fibromas (II). A clinical and radiologic spectrum of 316 cases. *Oral Surg Oral Med Oral Pathol Oral Radiol Endod* 1997; 84:540-49.
6. Barberi A, Cappabianca S, Colella G. Bilateral cemento-ossifying fibroma of the maxillary sinus. *BJR* 2003; 76:279-80.
7. Sanchis JM, Peñarocha M, Balaguer JM, Camacho F. Fibroma cemento-osificante mandibular: Presentación de dos casos y revisión de la literatura. *Med Oral* 2004; 9:69-73.