

## EFFECTS OF EXPOSURES TO A MIX OF FAST NEUTRONS AND 50Hz, 0.05mT MAGNETIC FIELD ON RAT TESTES” (IN VIVO STUDY)

Fadel Mohammed Ali<sup>1\*</sup>, Wafaa Nemat Allal Ahmed<sup>2</sup>, Samira Abdel Hamid<sup>3</sup>,  
Eman Sayed Abd EL-Fattah<sup>2</sup>, Mona Ahmed<sup>3</sup>

1. Biophysics Dept., faculty of science, cairo university.

2. National Institute for Standards, Cairo. Egypt.

3. Faculty of Science, Faculty of Girls Ain Shams university.

### Abstract

In the present work; the effect of whole body exposure of rats to mixed radiation (MR) from fast neutrons (FN) and 50Hz, 0.05mT magnetic field (MF) on the structural functions of the animal testis were investigated.

For this; 100 white albino rats were divided equally into four groups namely A, B, C and D. Animals of group A were used as control, groups B and C were exposed to 50Hz, 0.05mT MF and fission neutrons from <sup>252</sup>Cf source at a dose rate 10 μSv/h respectively for a period of 4 weeks at a rate of 8h/day and 5 days/week. Group D was exposed to fission neutrons and MF at the same field strengths and dose rates for the same period as groups B and C. At the end of the exposure period, blood was collected, animals were sacrificed and testes were removed for histopathological examination.

The results indicated highly significant decrease ( $p < 0.0001$ ) of testosterone hormone level (THL) in blood for animals from all groups as compared to control. Moreover; highly significant increase ( $p < 0.0001$ ) in the creatine phosphokinase (CPK) enzyme in sera was measured for all exposed animals. Results were analyzed depending on the probable mechanisms of interaction of these types of radiation with biological tissue. It was concluded from the present findings that the induced damage of the testis and the dramatic elevated CPK enzyme levels are higher for exposure to mixed radiation as compared with exposure to a single field.

*Experimental article (J Int Dent Med Res 2011; 4: (2), pp. 94-99)*

**Keywords:** Magnetic Field, Testis, Rat, Fast Neutrons.

Received date: 17 July 2011

Accept date: 05 August 2011

### Introduction

There is long scientific history on the biological effects of ionizing radiation (IR) and the safe limits of exposures<sup>1</sup>. Damage by IR, such as X-rays, γ-rays, and ultraviolet, have been extensively and thoroughly investigated and are well established, monitored and confirmed<sup>2</sup> as a significant risk for carcinogenic events<sup>3,4</sup>.

On the other hand; questionable consequences of everyday exposure to extremely low frequency magnetic field (ELFMF) pollution has become of great concern and

debate. Moreover, exposure to a mixture of both ionizing and non-ionizing radiation do exist for occupational exposures from nuclear generating facilities such as nuclear accelerators in medicine, manufacture, research and the use of nuclear reactors for generating electric power.

Exposure to electric and magnetic fields may increase the incidence of various types of cancers<sup>5,6</sup>.

Alterations in the erythrocyte's membrane elasticity and permeability in addition to changes in the hemoglobin molecular structure and heart injuries were detected after one month whole body exposure of rats to 50Hz, 0.2mT magnetic fields.<sup>7</sup> In addition; possible cytotoxic and/or cytostatic effects on differentiating spermatogonia after 50Hz, 1.7mT magnetic fields for 28 days of mouse were reported<sup>8</sup>.

Atrophy of the seminiferous tubules (ST) and renal necrosis due to 50Hz, 0.207μT

#### \*Corresponding author:

Dr. Wafaa N. Ahmed,  
National Institute for Standards, Cairo- Egypt.

E-mail: dr.wafaa.neamatallah@gmail.com

magnetic field exposure were detected<sup>9</sup>. Furthermore; sub-fertility and infertility of the reproductive system of rats exposed to 50Hz were also observed<sup>10, 11</sup>. Other complications such as significant decreased THL and main tissue changes in some ELFMF exposures<sup>12</sup> and degeneration similar to apoptosis in spermatogenic cells in mice after continuous exposure to 60Hz 14  $\mu$ T magnetic field were detected<sup>13</sup>.

The damage of the male rat's ST after short term MF- 50Hz, 50 and 100 $\mu$ T exposure was attributed to the increased level in the Follicle Stimulating Hormone (FSH) in serum<sup>14</sup>. Other studies reported that exposure to MF, either strong or weak, may damage the testis function by inducing injury to ST, Leydig cells and sperms<sup>15</sup>. Moreover; single exposure to 60Hz 6 mT for 30 min. resulted in DNA double-strand breaks and apoptosis<sup>16</sup>. It was also concluded that prolonged exposure to 50 Hz, 1G MF is biologically toxic on testes<sup>17</sup>.

Therefore, this study is carried out to investigate the effects of a mixed exposure of extremely low frequency magnetic field (ELF-MF) in the presence of fast neutrons (FN) on rats' testis functions.

### Materials and methods

One hundred adult male Albino rats of average weights  $200 \pm 10$ g were divided into four equal groups namely; A, B, C and D. Animals of group A were used as control, groups B and C animals were exposed to 50Hz, 0.05mT MF and fission neutrons from <sup>252</sup>Cf source at a dose rate 10  $\mu$ Sv/h respectively for a period of 4 weeks at a rate of 8h/day and 5 days/week. Group D was exposed to a mixed radiation of <sup>252</sup>Cf fission neutrons and magnetic field at the same field strengths and dose rates for the same period as groups B and C.

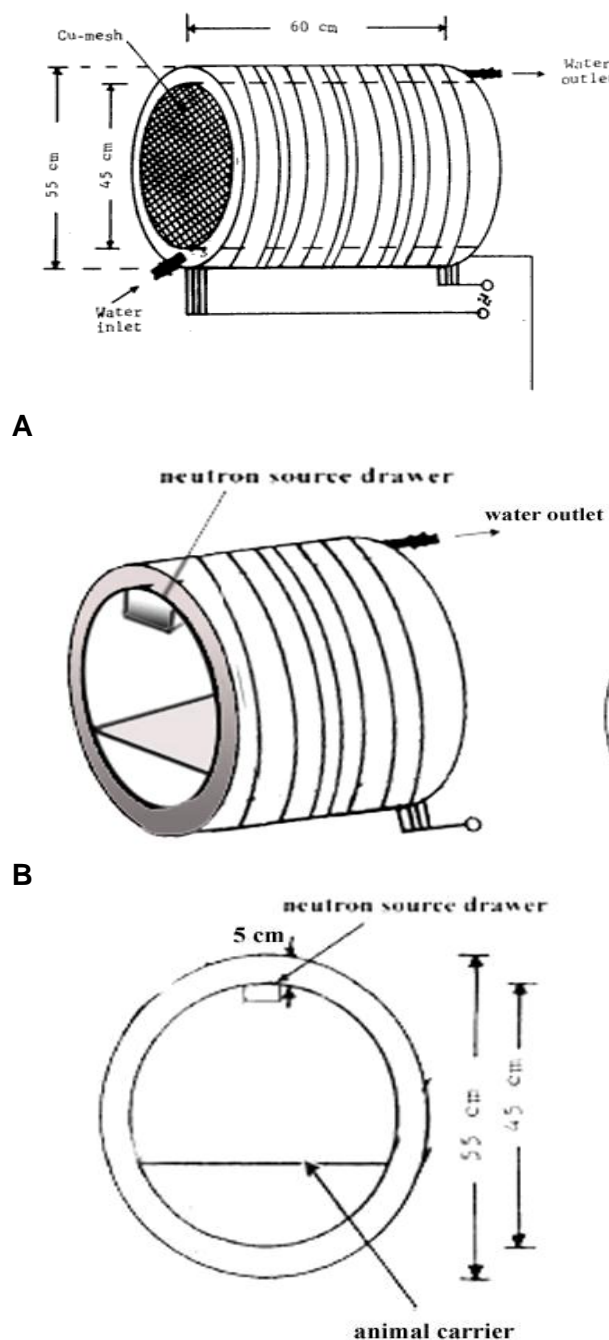
The total neutron dose received by the animals during the exposure period was 1.6 mSv. The animals were kept in special cages that permit normal ventilation, daylight and suitable environmental conditions, cleaning and changing water was done for all animals twice daily.

### Irradiation Facilities

The MF exposure system has been already described in details elsewhere<sup>7, 17</sup>.

It is composed of 4 solenoids of copper

wires connected in parallel. Cf<sup>252</sup> point source of 50 $\mu$ gm (original activity 27 mCi), purchased from Amersham radiochemical center (UK) with present yield  $5.4 \times 10^4$  n/s was used. The source was put in a special housing fixed on the inner top wall at the center of the solenoid chamber to allow average homogeneous fields of FN during MF exposure (Figure 1).



**C** **Figure 1.** Irradiation facility for mixed neutron and magnetic fields (A) show the solenoid, (B and C) show cross section at the mid of the solenoid showing the position of <sup>252</sup>Cf source.

The average neutron dose rate delivered to the animals was 10µSv/h as measured by a neutron monitor model NM2, manufactured by Nuclear Enterprises, England. The irradiation facilities of the animals were done in the Biophysics Department, Faculty of science, Cairo University. At the end of the exposure period, animals were individually weighed and the weights were recorded to the nearest 0.5/gm, and then blood samples were collected from the eye vein for biochemical CPK enzyme and THL investigation.

The animals were then directly sacrificed; both testicles were removed, weighted and prepared for histopathological investigations. There are no restrictions in Egypt for the use of experimental animals for scientific research, but the international ethics were followed in the present work.

*For THL estimation;* blood samples were spun at 3000 rpm for 10 minutes and serum was decanted. Sera were decanted, placed in glass bottles with rubber caps, labeled and stored at -60°C until quantification of testosterone.

Quantitative determination of testosterone in serum samples was performed using a commercially available radioimmunoassay (RIA) kit for testosterone according to the manufacturer's specifications. Results are expressed as nano-grams per milliliter (ng/ml).

*For histological investigations;* testes were fixed in 10% formal saline and subsequently processed for Microtomy at 6 µ thick. For Histopathological study, paraffin sections were routinely stained in Harris's Haematoxylin and Eosin (HE). The sections were photographed using an Image Analysis System-Compact Video Microscope (CVM); SN. 1148-JAPAN.

*For biochemical sera analysis;* total creatine phosphokinase (CPK) was performed at the Autoanalyser Unit, National Research Center (NRC) Cairo-Egypt using an Olympus Chemical Auto-analyzer, Model, Au400; GmbH. Wendenstr, 14-18, D-20097. Hamburg, Germany.

### Statistical Analysis

The Microsoft Excel was used for data analysis, and P value of 0.05 or less taken as (\*P < 0.05, \*\*P < 0.01, \*\*\*P < 0.001) for all statistical tests (with Student's t-test).

## Results

At termination of exposure, rats were investigated for body and testicular weights, THL and total CPK; these data are presented in Table 1.

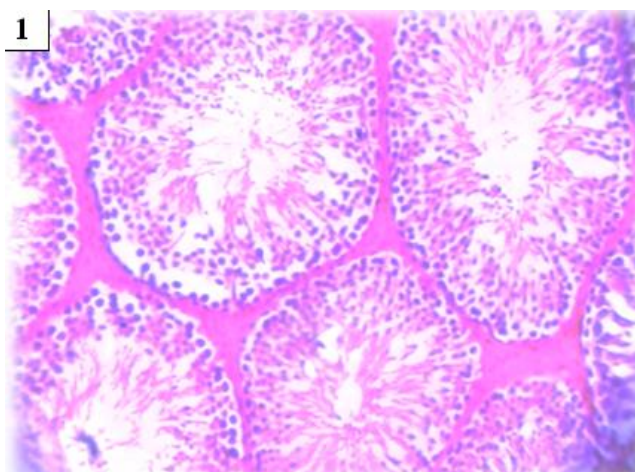
| Parameter                            | Groups       |                |               |                |
|--------------------------------------|--------------|----------------|---------------|----------------|
|                                      | (A)          | (B)            | (C)           | (D)            |
| Average Body Wt. (g)                 | 205 ± 4.9    | 217 ± 3.8**    | 192 ± 8.8'    | 206 ± 12.5     |
| Average Testicular Wt. (g)           | 3.42 ± 0.13  | 3.69 ± 0.065** | 3.25 ± 0.076' | 3.23 ± 0.078'  |
| Average Testosterone Level (ng/ml)   | 6.44 ± 0.09  | 6.12 ± 0.13**  | 5.96 ± 0.25** | 5.48 ± 0.29*** |
| Average Creatine Phosphokinase (U/L) | 24.67 ± 0.58 | 68 ± 6***      | 35 ± 1***     | 74 ± 1***      |

**Table 1.** Alterations in body weight, testicular weight and testosterone hormone level.

\*significant (p<0.05), \*\*highly significant (p<0.001), \*\*\*highly highly significant (p<0.0001) **Gp. (A):** is the control. **Gp. (B):** is whole body exposed to 50 Hz, 0.05 mT magnetic field for 4 weeks, 10 µSv/h, 8 hours/day and 5 days/week. **Gp. (C):** is whole body exposed to fast neutrons from <sup>252</sup>Cf source to receive a maximum dose of 1.6 mSv distributed over a period of 4 weeks, 10 µSv/h, 8 hours/day and 5 days/week. **Gp. (D):** is exposed to a complex of both ionizing (FN) radiation and non-ionizing ELF-MF exposure over a period of 4 weeks, 10 µSv/h, 8 hours/day and 5 days/week.

### Histological Observations:

*In control group (Gp. A),* testes generally showed normal testicular weight and architecture with an orderly arrangement of differentiating spermatogenic and Sertoli cells in the wall of the seminiferous tubules (ST) and Leydig cells in the interstitial space (Figure 2.1).



**Figure 2.1**

*Exposed animals to MF (Gp. B)* showed marked pathological lesions in the interstitial connective tissues in the form of edematous and hemorrhagic areas with excessive accumulation of intensely eosinophilic ground substance among the tubules (Figure 2.2).



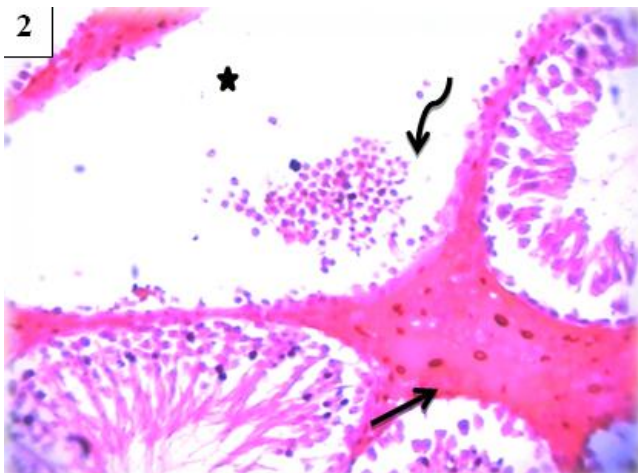


Figure 2.2

Inflammatory cells were observed within the inter-tubular spaces where atrophy, Leydig cell hyperplasia, congested and dilated blood vessels, ST deterioration, degenerated germ cells and focal sloughing were also observed (Figure 2.3).

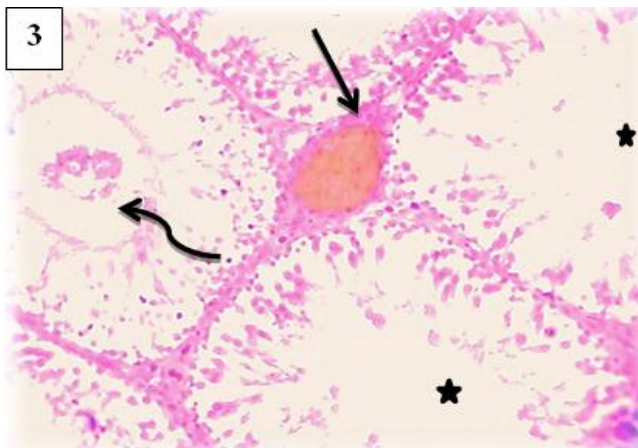


Figure 2.3

**Animals of (Gp. C)** showed severe lesions in the form of ST inflammatory reactions and interstitial tissues, damaged spermatogenic cells, basement membrane disruption, Leydig cell edema and hypoplasia of interstitial tissue.

Depleted germ cells, hyalinization, calcification and necrotic in the seminiferous tubules were frequent (Figure 2.4).

**Exposure to mixed radiations (Gp. D)** resulted in distortion of the ST and degeneration of Leydig cells. Marked increase of fibrous interstitial tissues were observed that difficulties emerged during cutting paraffin blocks, staining, and investigating the sections for this phase that the

processes of wax impedance, cutting, staining and section investigations were repeated twice (Figure 2.5).

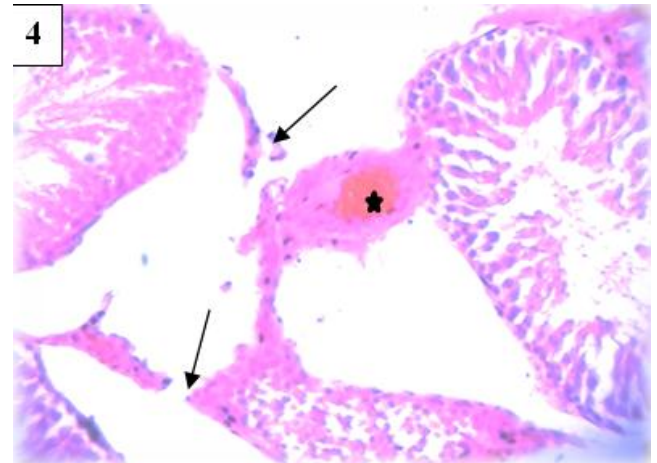


Figure 2.4

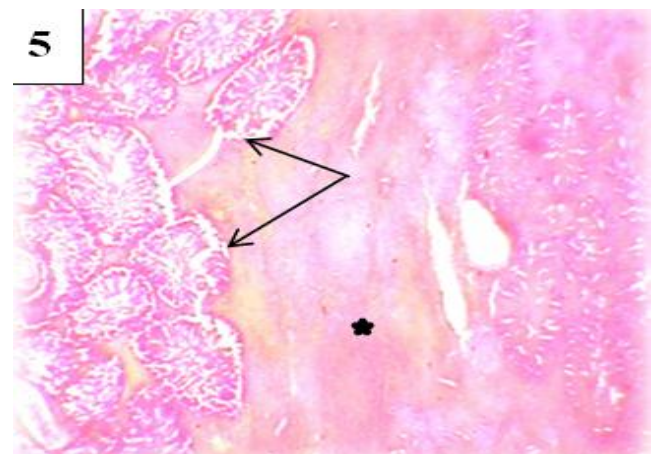


Figure 2.5

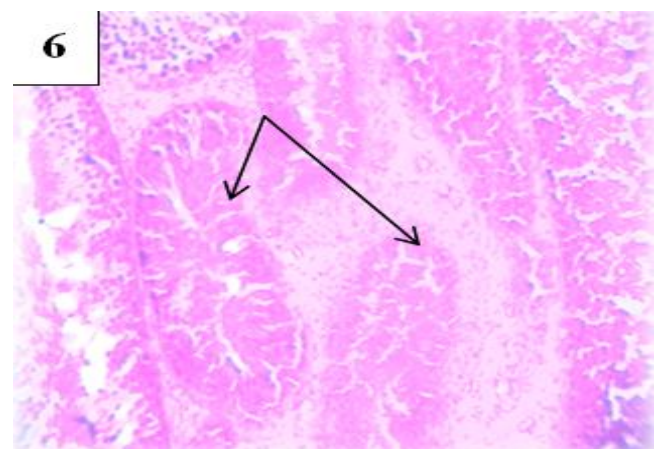
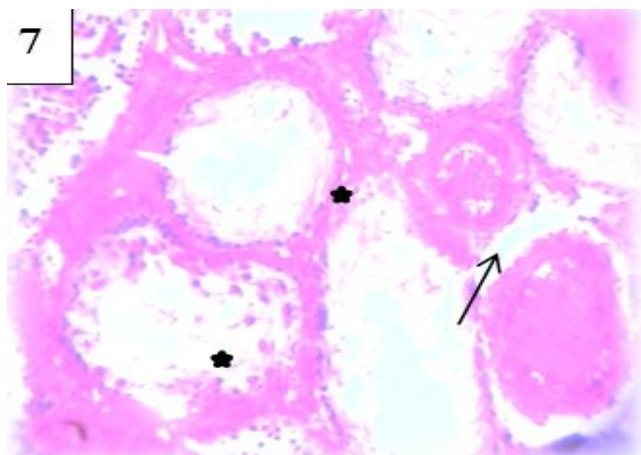


Figure 2.6

Fibrous interstitial tissue, edema, and hypoplasia of Leydig cells were seen. Moreover; hyalinization and calcification were abundant

(Figure 2.6), normal ST were hardly seen for some sections (Figure 2.7).



**Figure 2.7**

**Figure 2.** (Gp.A),1: Testis histology of control rat, showing normal seminiferous tubules and interstitial tissues;(X250). (Gp.B),Rat exposed to magnetic field; 2: Degenerated and depleted germ cells (*star*),eosinophilic ground substances (*curved arrow*), edematous, hemorrhagic and hyperplasia of interstitial tissues (*arrow*); (X400). 3: Atrophy and focal sloughing tubule (*curved arrow*); loss of spermatogenic substances (*stars*);and Leydig cell hyperplasia(*arrow*); (X250). (Gp.C), Rat exposed to fission neutrons; 4: Disrupted tubules (*arrows*); hemorrhage (*star*); and marked severe hypoplastic interstitial tissues (X100). (Gp.D), Rat exposed to mixed fields; 5: Abnormal ST (*arrow*); infibrous interstitial tissues (*star*); and hemorrhage(X100). 6: Hyalinization and calcification of seminiferous tubules within fibrous interstitial tissues (*arrows*); (X250).7: Abundantnecrotic ST, hemorrhages of interstitial tissues and Leydig cells and edema (*stars*), and blood vessel dilation (*arrow*); normal ST are hardly seen (X400)[H&E]

## Discussion

Despite of the large number of both experimental and epidemiological studies that were extensively carried out on (ELF-MFs), the interaction mechanisms with biological systems are still unclear. However, the mechanisms of interaction of fast neutrons with biological systems is completely different than ELF-MFs since the average energy associating 50 Hz MF is around  $10^{13}$ eV while it is  $2 \times 10^6$ eV for fission neutrons<sup>18</sup>. Therefore, it seems logic to carry the discussion of the present findings depending on the basic possible interactions of each type of

radiation with the biological system. The most probable interaction of FN with biological system is the formation of highly energetic nuclear recoils resulting from neutron elastic scattering with the nuclei forming the biological macromolecules. Hydrogen nuclei have the highest scattering cross-section and the average logarithmic energy transferred per collision (unity) for fast neutrons. These highly energetic nuclear recoils migrate in the hydrocarbon network resulting in deficient regions, highly energetic active species and free radicals<sup>17</sup>.

The radiative capture of chlorine nuclei to neutrons share considerable source of damage to the biological system since all electrolytes are in the form of chlorides. The basic interaction mechanism of MF with moving ions is the formation of perpendicular forces on the ions which cause their shift from target directions. Since all metabolic functions are run through ionic currents and potentials, the application of MFs will result in the disturbance of these metabolic activities and the formation of free radicals. These free radicals can cause oxidative cell damage at the cellular level, interfering with the protein synthesis to finally result in acute inflammation, cellular destruction and tissue edema<sup>19,10,11</sup>.

According to the fore-mentioned interaction mechanisms of the MFs and FN with the biological tissues; one can analyze the present findings. The observed hyperplasia of the interstitial tissues and Leydig cells of the exposed animals to 50Hz MF in addition to the degenerated spermatogonia (Figure 2.2) and the highly significant decreased testosterone level in blood; all represent structural and functional changes in the testis.

One may speculate that; the normal tilting movement of the phospholipid bilayer macromolecules forming the cellular membrane could be disrupted under the influence of the MF which may lead to the changes in the packing properties of these molecules and hence the intermolecular forces of cellular membrane. This analysis could be supported by the observed atrophy of the ST, hemorrhage, hyalinization and calcification (Figures 2.5, 2.6, 2.7).

Moreover; the highly significant increased CPK level in the blood is mainly attributed to the damage of the cellular membrane in cells of different organs. On the other hand; the observed hypoplasia of the interstitial tissues and the



disrupted ST (Figure 2.4) are indication for the direct damaging mechanisms carried by the fast neutrons to the macromolecules forming the cellular membrane. Exposure of animals to both types of radiation caused more cellular damage as well as the highly significant increased CPK level in blood.

## Conclusions

*It may be concluded from the present findings that;*

1. Exposure to either fast neutron doses within the limits recommended by ICRP-60 is harmful to the testis.
2. Whole body exposure to 50 Hz, 0.5 G magnetic field is harmful to the body and decreases the fertility of the animal.
3. It seems necessary to reconsider the permissible dose limits recommended by the ICRP-60 in case of exposures to mixed radiation with 50Hz magnetic field.

## Acknowledgements

Appreciation and gratitude are expressed to Dr. Mahmoud S. Morsy, professor and head of Textile Division, National Institute for Standards; Cairo-Egypt, for technical assistance in providing the photographing imaging system.

## Declaration of Interest

The authors report no conflict of interest and the article is not funded or supported by any research grant.

## References

1. ICRP-60, Recommendations of the International Commission on Radiological Protection. ICRP-Publication 1990: 60, Pergamon Press.
2. Chung HC, Kim SH, Lee MG et al. Mitochondria dysfunction by gamma- irradiation accompanies the induction of cytochrome p450 2E1 (CYP2E1) in rat liver. Toxicology 2001; 161(1-2): 79-91.
3. Jones JA, Casey RC, Karouia F. Ionizing Radiation as a Carcinogen. Comprehensive Toxicology 2010; (Second Edition) 14: 181-228.
4. Adachi S, Ryo H, Hongyo Tet al. Effects of fission neutrons on human thyroid tissues maintained in SCID mice. Mutat Res 2010; 696(2): 107-13.
5. ClearySF. A review of in vitro studies: low-frequency electromagnetic fields. Am. Ind. Hyg. Assoc. J.1993; 54(4): 178-85.
6. Bowman JD, Thomas DC, LondonSJ, Peters JM. Hypothesis: the risk of childhood leukemia is related to combinations of power-frequency and static magnetic fields. Bioelectromagnetics1995; 16(1): 48-59.
7. Fadel MA, Wael SM, MostafaRM. Effect of 50 Hz, 0.2 mT magnetic fields on RBC properties and heart functions of albino rats, Bioelectromagnetics 2003; 24(8): 535-45.
8. Raffaele De Vita, Delia Cavallo, Luigi Raganella, PatriziaEleuteri, Maria G Grollino, Alberto Calugi. Effects of 50Hz magnetic fields on mouse spermatogenesis monitored by flow cytometric analysis. Bioelectromagnetics 2005; 5(16): 330-334.
9. Zare S, Alivandi S, Ebadi AG. Histological studies of the low frequency electromagnetic fields effect on liver, testes and kidney in guinea pig. World Applied Sciences Journal 2007; 2(5): 509-511.
10. Khaki AA, Tubbs RS, Shoja M Met al. The effects of an electromagnetic field on the boundary tissue of the seminiferous tubules of the rat: a light and transmission electron microscope study. Folia Morphol 2006; 65(3): 188-94.
11. Khaki AA, Zarrintan S, Khaki A, Zahedi A. The effect of electromagnetic field on the microstructure of seminal vesicles in rat: a light and transmission electron microscope study. Pak J BiolSci 2008; 1; 11(5): 692-701.
12. Farkhad SA, Zare S, Hayatgeibi H, Qadiri A. Effects of extremely low frequency electromagnetic fields on testes in Guinea pig. Pak. J BiolSci2007; 15; 10(24): 4519-22.
13. Yoon-WK, Hee SK, Jin SL et al. Effects of 60Hz 14µT magnetic field on the apoptosis of testicular germ cell in mice. Bioelectromagnetics 2009; 30(3): 66-72.
14. Akram A, HadiF M, Mohammad J,Tahmasebi B, Hajieh S, Mohammad B. Hypothalamic- pituitary- gonadal axis responses of the male rats to short and long term alternative magnetic fields (50 Hz) exposure. JRMS 2009; 14(4): 231-238.
15. Cao Y, Zhang W, Lu MX et al. 900-MHz microwave radiation enhances gamma- ray adverse effects on SHG44 cells. J Toxicol Environ Health A 2009; 72(11-12): 727-32.
16. Jiyeon K, Chang SH, Hae JL, Kiwon S. Repetitive exposure to a 60-Hz time-varying magnetic field induces DNA double-strand breaks and apoptosis in human cells. Biochemical and Biophysical Research Communications 2010; 400(4): 739-44.
17. Islam MS, Fadel MA, Hamada MM, El-Badry AA. Reproductive Impacts from Exposure of Male Albino Rats to 50Hz, 1 Gauss Magnetic Field Effects of Exposure to 50Hz, 1 Gauss Magnetic Field on Reproductive Traits in Male Albino Rats. ACTA VET. BRNO 2011, 80: 107-111.
18. David O. Carpenter, Sinerik Ayrapetyan. Biological Effects of Electric and Magnetic Fields. 1994; Volume 1, Ch. 2.
19. Khaki AA, Choudhry R, Kaul JK et al. Montazam H. Effect of electromagnetic field on Sertoli cell of rat testes. A light and transmission electron microscope study. JIMSA 2004; 17: 136-140.