

Electron microscopic examination of needles used in infraclavicular brachial plexus block

İnfraklaviküler brakial pleksus bloğunda blok iğnelerinin elektron mikroskopik incelenmesi

Bora Bilal¹, Ömer Faruk Boran¹, Mustafa Fevzi Sargon², Kemal Erdem Başaran³, Adem Doğaner⁴

¹ Kahramanmaraş Sutcu İmam University Faculty of Medicine Department of Anesthesiology, Kahramanmaraş, Turkey

² Atılım University Faculty of Medicine Department of Anatomy, Ankara, Turkey

³ Erciyes University Faculty of Medicine Department of Physiology, Kayseri, Turkey

⁴ Kahramanmaraş Sutcu İmam University Faculty of Medicine Department of Biostatistics and Medical Informatics, Kahramanmaraş, Turkey

ORCID ID of the author(s)

BB: 0000-0003-3884-8042
ÖFB: 0000-0002-0262-9385
MFS: 0000-0002-7740-7111
KEB: 0000-0001-6035-9398
AD: 0000-0002-0270-9350

Abstract

Aim: The application of peripheral block is frequently used in anesthesia practice. One of the most significant complications of this procedure is peripheral nerve damage that can develop due to the needles used. The aim of this study was to determine the presence of tissue residue on the needle and to obtain information about damage to surrounding tissues during this procedure by examining the needles used in brachial plexus block with electron microscopy.

Methods: This prospective-cohort study included patients who were to undergo forearm or hand surgery in the Orthopedics Clinic under anesthesia with infraclavicular brachial plexus block performed with 2 different techniques: The local anesthetic agent was administered to the subclavian artery at 6 and 9 o'clock levels in Group 1 and 2, 6 and 9 o'clock levels in Group 2. The needles used during the block were preserved in glutaraldehyde solution then examined with electron microscopy. The presence of tissue on the needles was recorded and statistical evaluations were made.

Results: The needles used in two different techniques of infraclavicular brachial plexus block were examined under scanning electron microscope. The amount of tissue residue remaining on the needle in Group 1 was significantly less than that in Group 2 ($P<0.001$).

Conclusion: When it is considered that ultrasound provides a 2-dimensional image, the fewer the number of needle manipulations made during the procedure of brachial plexus block application, the less damage will be made to the surrounding tissues, thus reducing the possibility of mechanical nerve damage.

Keywords: Infraclavicular block, Electron microscopy, Neuronal damage

Öz

Amaç: Periferik blok uygulamaları anestezi pratiğinde sıklıkla kullanılmaktadır. Bu işlemin en önemli komplikasyonlarından biri de kullanılan iğnelere bağlı gelişebilecek periferik sinir hasarıdır. Çalışmamızda brakial pleksus blok işlemlerinde kullanılan iğnelerin işlem sonrası elektron mikroskopisi ile incelenerek iğne üzerinde kalan doku parçalarının varlığı ile iğnenin işlem sırasında çevre dokulara verdiği hasar hakkında bilgi sahibi olmak amaçlanmıştır.

Yöntemler: Prospektif kohort olarak planlanan çalışmamızda ortopedi kliniğinde ön kol veya el cerrahisi yapılacak hastalara farklı iki teknik ile infraklaviküler brakial pleksus bloğu ile anestezi yapıldı. İnfraklaviküler blok; Grup 1'de subklavian arterin saat 6 ve 9 hizasına lokal anestetik verilererek, Grup 2'de subklavian arterin saat 2, 6 ve 9 hizasına verilerek uygulandı. Blok sırasında kullanılan iğneler glutaraldehit solüsyonunda korunarak sonrasında elektron mikroskopik olarak incelendi. İğne üzerinde doku varlığı kaydedildi, istatistiksel olarak değerlendirildi.

Bulgular: İnfraklaviküler brakial pleksus bloğunda iki farklı teknikte kullanılan iğnelerin SEM değerlendirilmesinin yapıldığı çalışmamızda. Grup 1'de iğne üzerinde kalan doku kalıntısı miktarı grup 2'den daha az saptanmıştır ($P<0,001$).

Sonuç: Ultrasonun iki boyutlu görüntü vermesi göz önüne alındığında brakial pleksus blok uygulamalarında işlem sırasında iğne yönlendirme sayısı ne kadar az olursa çevre dokulara daha az zarar verilecektir dahası muhtemel mekanik sinir hasarı olasılığı da azalacaktır.

Anahtar kelimeler: İnfraklaviküler blok, Elektron mikroskopi, Nöronal hasar

Corresponding author / Sorumlu yazar:

Bora Bilal

Address / Adres: Kahramanmaraş Sütçü İmam Üniversitesi Tıp Fakültesi Anesteziyoloji Anabilim Dalı, Kahramanmaraş, Türkiye
e-Mail: bilalboran@yahoo.com

Ethics Committee Approval: Approval for this study was granted by K.S.U Faculty of Medicine Scientific Research Ethics Committee (Date: 18.01.2017 Number: 2017/01/22).

Etik Kurul Onayı: KSÜ Tıp Fakültesi Bilimsel Araştırmalar Etik Kurulu (Tarih: 18.01.2017 No: 2107/01-22) onayı alındı.

Conflict of Interest: No conflict of interest was declared by the authors.

Çıkar Çatışması: Yazarlar çıkar çatışması bildirmemişlerdir.

Financial Disclosure: The authors declared that this study has received no financial support.

Finansal Destek: Yazarlar bu çalışma için finansal destek almadıklarını beyan etmişlerdir.

Published: 1/9/2020

Yayın Tarihi: 09.01.2020

Copyright © 2020 The Author(s)

Published by JOSAM

This is an open access article distributed under the terms of the Creative Commons Attribution-NonCommercial-NoDerivatives License 4.0 (CC BY-NC-ND 4.0) where it is permissible to download, share, remix, transform, and build upon the work provided it is properly cited. The work cannot be used commercially without permission from the journal.



Introduction

Applications of peripheral block are frequently used in anesthesia practice. Over time, the use of ultrasound has gained a stronger ground in regional anesthesia applications, in which various effects such as shortening the time to onset of the block [1], high rates of block success [2], and postoperative analgesia [3,4] have been reported. Furthermore, with the use of ultrasound during the procedure, there are advantages such as reducing the number of needle manipulations and shortening the duration of the procedure. There are limited data related to the occurrence and frequency of neurological complications. In peripheral block applications, the nerve to be blocked is located with the neurostimulation technique and ultrasound guidance with the aid of peripheral block needles. Peripheral block applications, both with the use of the neurostimulation technique and the use of ultrasound under current conditions, are performed more safely and with lower complication rates. However, as ultrasound provides a 2-dimensional image of the vascular, neural, and muscular structures together, complications such as vascular access, direct nerve damage with the needle and intraneural injection may be seen [5]. It has been reported that fewer needle manipulations during peripheral block under ultrasound guidance will reduce the risk of mechanical nerve damage [6,7].

The use of electron microscopy has been helpful for better understanding of the ultrastructure and associated details related to peripheral nerves. Findings obtained with electron microscopy can be of guidance in physiological, pharmacological, and mechanical complications related to regional and peripheral blocks [8].

In the current study, two techniques used in infraclavicular brachial plexus block were compared. The aim was to evaluate which technique caused less tissue damage through post-procedural examination of the peripheral block needles used during the procedures under an electron microscope.

Materials and methods

This study included 30 patients aged between 18-70 years who were to undergo elective forearm or hand surgery with infraclavicular brachial plexus block. Patients were excluded from the study if they did not wish to participate, if they were pregnant, had neuromuscular disease, a history of infraclavicular region surgery, nerve damage or neurological disease, bleeding disorder or coagulopathy, a history of allergy to local anesthetic drugs, an infection in the needle entry site or any contraindications to regional anesthesia.

Block administration protocol

Patients were admitted to the preoperative block room, intravenous vascular access was obtained from the back of the hand, through which an infusion of 0.9% NaCl was started at the rate of 3ml/kg/hour. Throughout the procedure, nasal O₂ (2L/min) was administered and patients were monitored with electrocardiography, pulse oximetry, and non-invasive blood pressure measurements. All blocks were performed by a single anesthetist (BB), using a 21-gauge 100 mm peripheral block needle (Stimuplex® A, B. Braun Melsungen AG, Germany). During administration of the peripheral block, an ultrasound

device (Esaote MyLab Five, Italy) with a 10MHz linear probe was used. The ultrasound probe was placed parasagittally immediately medial to the coracoid process using the previously described coracoid technique [9]. After visualization of the subclavian artery and the surrounding brachial plexus cords, 25 ml of 0.5% bupivacaine was administered to the subclavian artery at 6 and 9 o'clock levels in Group 1 and 2, 6 and 9 o'clock levels in Group 2. The duration of the block procedure, time to onset, and complications such as vascular puncture during the procedure and paresthesia were noted. After completion of the peripheral block application, the peripheral block needle used was numbered and prepared for electron microscopic examination.

Electron microscopic examination of the block needles

The needles used in the peripheral block application were fixed in 2.5% glutaraldehyde for 24 hours, washed in phosphate buffer (pH: 7.4), then dehydrated in increasing concentrations of acetone. They were then post-fixed in 1% osmium tetroxide for one hour, washed in phosphate buffer (pH: 7.4), and dehydrated again in increasing concentrations of acetone. The samples were then attached to metal stubs with double-sided adhesive bands. Using a BIO-RAD (England) sputter apparatus, the samples to be examined were coated with gold at a thickness of 100 Angstrom. The prepared materials were examined with a Fesem Zeiss Gemini 500 (Germany) scanning electron microscope. Photographs were taken at x60, x1000, and x5000 magnification, numbered and examined by another researcher (ÖFB). Evaluations were made with respect to the deformation of the needle surface on the images at x60 and x1000 magnification. The amount of soft tissue remaining on the tip of the needle was evaluated under x5000 magnification and classified using a 5-point Likert scale (1: none, 2: minimal, 3: moderate, 4: mostly, 5: completely).

Statistical analysis

Data obtained in the study were analyzed statistically using IBM SPSS v. 22 software (IBM SPSS for Windows, IBM Corporation, Armonk, NY, USA). Conformity of the data to normal distribution was assessed with the Shapiro-Wilk test. Group comparisons of variables showing normal distribution were made using the Independent Samples t-test. Statistical parameters were stated as mean and standard deviation mean (SD) values. For comparisons of variables not showing normal distribution, the Mann Whitney U-test was applied. Statistical parameters were stated as median (25%-75% quartiles) values. The relationships between group distributions of categorical variables were examined with the Chi-square test and the Fisher Exact test. A value of $P < 0.05$ was considered statistically significant.

Results

Scanning electron microscopic evaluation made of the needles used in 2 different techniques of infraclavicular brachial plexus block showed that the amount of tissue residue remaining on the needle in Group 1 was significantly less than that in group 2 ($P < 0.001$). Duration of procedure was shorter in Group 1 ($P = 0.025$). The onset time of the block was less in group 2 ($P = 0.001$) (Table 1). No deformation or breakage of the needle

surface were determined on the images at x60 and x1000 magnification in either one of the groups (Figure 1). Findings of tissue residue were observed on all the needles on images magnified at x5000 (Figure 2). Paresthesia was observed during the procedure in 2 patients in Group 2.

Table 1: Patient and block characteristics, tissue residue on the needles

		Group 1	Group 2	P-value
Procedure time ^b min	Median(Q1-Q3)	4.00(3.00-4.00)	4.00(4.00-5.00)	0.025*
Block onset time ^b min	Median(Q1-Q3)	14.00(13.00-14.00)	12.00(12.00-12.00)	0.001*
Gender ^c	Female	7(46.7)	5(33.3)	0.456
	Male	8(53.3)	10(66.7)	
Tissue residue ^b	Median(Q1-Q3)	2.00(2.00-3.00)	4.00(4.00-4.00)	<0.001*

^a Independent samples t test, ^b Mann-Whitney U test, ^c Chi-Square test, ^d Fisher exact test. * Difference between the groups is statistically significant; Median(Q1-Q3): Median (25% quartile-75% quartile)




Figure 1: Images of a Group 1 needle at x60 and x1000 magnification. At x1000 magnification, mostly epithelial residue can be seen on the needle tip

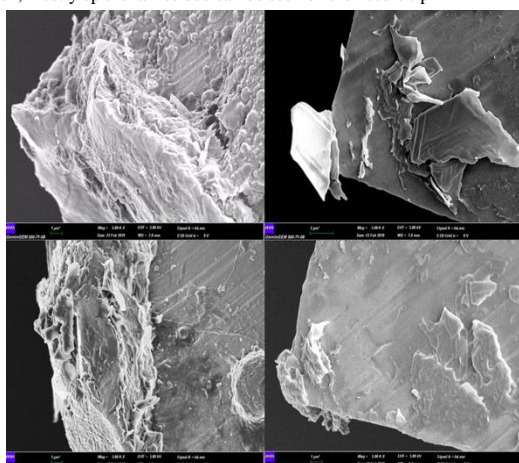


Figure 2: Electron microscope image of needle tips at x5000 magnification

Discussion

In peripheral blocks administered under ultrasound guidance, one of the most significant complications is mechanical nerve damage related to the needles used. When it is considered that ultrasound provides a 2-dimensional image, the fewer the number of needle manipulations made during the procedure of brachial plexus block application, the less damage will be made to the surrounding tissues, thus reducing the possibility of mechanical nerve damage.

With ultrasound guidance it is usually difficult to differentiate neural structures from other soft tissues, and despite real-time ultrasonographic imaging in clinical practice, it may not be possible to prevent complications such as contact of the needle to the nerve and epineurium injury. In the literature related to peripheral blocks with ultrasound guidance, there are studies that have reported peripheral nerve damage, unintended intraneural injections, and the anatomic and histological properties of these nerves [10,11]. Hara et al. [12] reported the frequency of unintended intraneural injection as 16.3% in sciatic nerve block administered under ultrasound guidance in subgluteal approach. In a study of interscalene and supraclavicular brachial plexus blocks, Liu et al. [13] reported unintended intraneural injection at the rate of 17%. In both

studies, the intraneural injections in these patients did not reportedly result in clinical neural injury during the postoperative period. The most likely reason for this was stated as the fact that intraneural injections were made within the neural connective tissue and there was no damage to the neural fascicles. In this study, electron microscope examination of the needles used in infraclavicular block showed that the tissue residue on the needle tips, as seen at x5000 magnification in both groups, was of connective tissue in character.

Previous studies have not shown any superiority between the methods of single, double or triple injections [14,15]. Bowens et al. [16] reported that the single injection technique used in the posterior cord in the infraclavicular block had high success rates. In accordance with these data in literature, by examining the block needles used in infraclavicular blocks achieved with double and triple injections, the effects formed in the neural structures or soft tissues during these procedures were evaluated. In the electron microscopic examination of the needle tips of Group 2 at x5000 magnification, where triple injections were made, a significantly greater amount of tissue residue was observed on the needle tips. When the course of the brachial plexus in the upper extremity and the surrounding soft tissue and the proximity to vascular structures are taken into consideration, it can be said that if the number of needle manipulations is reduced during block application, less damage will be incurred.

In a cadaver study of upper extremity blocks administered under ultrasound guidance, Sermeus et al. [17] found the incidence of intraneural injection higher in procedures performed with a direct approach with ultrasonographic guidance to the target nerve compared to those performed with a tangential approach. In the current study, the possibility of needle contact with the brachial plexus was increased in Group 2, where local anesthetic agents were administered at 2, 6 and 9 o'clock levels of the subclavian artery. Especially in maneuvers which consider the medial cord as the target, the risk of direct contact with the medial cord increases. Paresthesia was observed in 2 patients in Group 2 in this study.

Limitations

Limitations of this study include the lack of histological examination of tissue residues at the tip of the needle. Further randomized controlled studies may be planned in the future.

Conclusion

In peripheral blocks administered under ultrasound guidance, it is recommended to use additional techniques such as real-time peripheral nerve stimulator, injection pressure monitorization and hydro-localization to reduce the incidence of intraneural injection. Decreasing needle manipulations will prevent damaging of the surrounding connecting tissue and lessen the possibility of the needle causing mechanical damage in the peripheral nerves.

References

- Casati A, Danelli G, Baciarello M, et al. A prospective, randomized comparison between ultrasound and nerve stimulation guidance for multiple injection axillary brachial plexus block. *Anesthesiology*. 2007;106:992-6.
- Perlas A, Brull R, Chan VW, McCartney CJ, Nuica A, Abbas S. Ultrasound guidance improves the success of sciatic nerve block at the popliteal fossa. *Regional Anesthesia and Pain Medicine*. 2008;33:259-65.
- Oberndorfer U, Marhofer P, Bosenberg A, et al. Ultrasonographic guidance for sciatic and femoral nerve blocks in children. *British Journal of Anaesthesia*. 2007;98:797-801.
- Marhofer P, Sitzwohl C, Greher M, Kapral S. Ultrasound guidance for infraclavicular brachial plexus anaesthesia in children. *Anaesthesia*. 2004;59:642-6.
- Hadzic A, Sala-Blanch X, Xu D. Ultrasound guidance may reduce but not eliminate complications of peripheral nerve blocks. *Anesthesiology*. 2008;108:557-8.

6. Neal JM, Bernards CM, Hadzic A, et al. Asra practice advisory on neurologic complications in regional anesthesia and pain medicine. *Regional Anesthesia and Pain Medicine*. 2008;33:404–15.
7. Bernards CM, Hadzic A, Suresh S, Neal JM. Regional anesthesia in anesthetized or heavily sedated patients. *Regional Anesthesia and Pain Medicine*. 2008;33:449–60.
8. Reina, Miguel Angel, et al. Electron microscopy and the expansion of regional anesthesia knowledge. *Techniques in Regional Anesthesia and Pain Management*. 2002;6(4):165-71.
9. Taboada M, Rodriguez J, Amor M. Is ultrasound guidance superior to conventional nerve stimulation for coracoid infraclavicular brachial plexus block? *Reg Anesth Pain Med*. 2009;34:357–60.
10. Liu SS, YaDeau JT, Shaw PM, Wilfred S, Shetty T, Gordon M. Incidence of unintentional intraneural injection and postoperative neurological complications with ultrasound-guided interscalene and supraclavicular nerve blocks. *Anaesthesia*. 2011;66:168–74.
11. Robards C, Hadzic A, Somasundaram L, et al. Intraneural injection with low-current stimulation during popliteal sciatic nerve block. *Anesthesia and Analgesia*. 2009;109: 673-7.
12. Hara K, Sakura S, Yokokawa N, Tadenuma S. Incidence and effects of unintentional intraneural injection during ultrasound – guided subgluteal sciatic nerve block. *Reg Anesth Pain Med*. 2012;37:289-93.
13. Desgagnes MC, Levesque S, Dion N, et al. A comparison of a single or triple injection technique for ultrasound-guided infraclavicular block: a prospective randomized controlled study. *Anesth Analg*. 2009;109:668-72.
14. Tran de QH, Bertini P, Zaouter C, Munoz L, Finlayson RJ. A prospective, randomized comparison between single and double injection ultrasound-guided infraclavicular brachial plexus block. *Reg Anesth Pain Med*. 2010;35:16-21.
15. Fredrickson MJ, Wolstencroft P, Kejrwal R, Yoon A, Boland MR, Chinchawala S. Single versus triple injection ultrasound-guided infraclavicular block: confirmation of the effectiveness of the single injection technique. *Anesth Analg*. 2010 Nov;111(5):1325-7.
16. Bowens C Jr, Gupta RK, et al. Selective local anesthetic placement using ultrasound guidance and neurostimulation for infraclavicular brachial plexus block. *Anesth Analg* 2010;110:1480–5
17. Sermeus LA, Sala-Blanch X, McDonnell JG, Lobo CA, Nicholls BJ, van Geffen GJ, et al. Ultrasound-guided approach to nerves (direct vs. tangential) and the incidence of intraneural injection: a cadaveric study. *Anaesthesia*. 2017 Apr;72(4):461-9.

This paper has been checked for language accuracy by JOSAM editors.

The National Library of Medicine (NLM) citation style guide has been used in this paper.

Suggested citation: Patrias K. Citing medicine: the NLM style guide for authors, editors, and publishers [Internet]. 2nd ed. Wendling DL, technical editor. Bethesda (MD): National Library of Medicine (US); 2007-[updated 2015 Oct 2; cited Year Month Day]. Available from: <http://www.nlm.nih.gov/citingmedicine>