

## Kommerell's Diverticulum Association Of Aberrant Left Subclavian Artery And Right Arcus Aorta In An Adolescent

### Adolesan Olguda Kommerell Divertikülü, Aberran Sol Subklaviyen Arter Ve Sağ Arkus Aorta Birlikteliği

Hüseyin Yılmaz<sup>1</sup>, Mehmet Burhan Oflaz<sup>1</sup>, Emin Ünal<sup>1</sup>, Muhammed Güneş<sup>1</sup>, Fatih Şap<sup>1</sup>,  
Tamer Baysal<sup>1</sup>

<sup>1</sup>Necmettin Erbakan University, Meram Medical Faculty, Department of Pediatrics, Division of Pediatric Cardiology, Konya, Turkey

#### Özet:

Konjenital aortik ark anomalileri brakial arkın embriyolojik gelişiminde ki hatalardan kaynaklanmaktadır. Sağ aortik ark ve aberran sol subklaviyen arter hastalarında Kommerell divertikülü, arka sol dördüncü aortik arkın embriyolojik bir kalıntısıdır. Trakea veya özefagusu basıya bağlı havayolu darlığı ya da disfaji belirtileri gösterebilir. Asemptomatik olan vakalar bazen farklı görüntülemelerin yapıldığı esnada tanı alabilir. Burada tonsillektomi yapılması planlanan hastanın bradikardilerin olması nedeni ile bakılan ekokardiyografisinde subkostal görüntüleme aortada çift akım paterni izlenmesi üzerine çekirilen torakal BT anjiyografi sonucunda Sağ arkus aorta,aberran sol subklaviyen arter (ASSA) ve Kommerell divertikülü anomalisi olduğu tespit edilen bir olgu sunulmaktadır. Belirgin bir şikayeti olmayan hastalar erken anevrizma oluşumunu tespit etmek ve mediastinal yapılara olabilecek bası nedeniyle yakından izlenmelidir.

**Anahtar Kelimeler:** Disfaji, sağ arkus aorta, Kommerel divertikül, aberran sol subklaviyen arter

#### Abstract:

Congenital aortic arch anomalies are caused by errors in the embryological development of the brachial arch. In patients with right aortic arch and aberrant left subclavian artery, Kommerell diverticulum is an embryological residual tissue of the posterior left fourth aortic arch. This anomaly may present with signs of airway stenosis or dysphagia due to compression of the trachea or esophagus. Asymptomatic cases can be diagnosed at the time of different imaging. Here, a case is presented, aberrant left subclavian artery and Kommerell diverticulum in the right arcus is depicted in thoracic CT angiography imaging after an subcostal echocardiographic examination revealed a double-flow pattern in aortic view due to bradycardia was detected in patient's evaluation for pre-op tonsillectomy. Patients without significant complaints should be monitored closely to detect early aneurysm formation and compression to the mediastinal structures.

**Keywords:** Dysphagia, right aortic arch, Kommerell diverticulum, aberrant left subclavian artery

#### Introduction

Aortic arch anomalies can be seen alone or with congenital heart anomalies or genetic syndromes (1). Congenital aortic arch anomalies result from abnormal development of the aortic arch and its branches, and encompasses a wide heterogenous spectrum with or without a vascular ring (2). The association of right aortic arch and aberrant left subclavian artery (LSCA) is rare and is an anatomic feature observed in approximately 0.06% to 0.1% of the healthy

population. The Kommerell diverticulum in patients with right aortic arch and aberrant LSCA is an embryologic remnant of the posterior left fourth aortic arch (3). We present a case of Kommerell diverticulum, LSCA and right aortic arch who diagnosed while evaluation of pre-operatively for adenoidectomy.

### Case

A 12-year-old male patient was referred to our clinic because of bradycardia on ECG before adenoidectomy. All systemic examination findings were normal. ECG was in sinus rhythm, normal QRS axis, rate: 60/min, PR: 120ms, QTc: 400ms. Echocardiographic examination revealed normal cardiac cavities and functions (EF:77%, FS:45%). Patient with right aortic arch showed at subcostal imaging a double flow pattern in the aorta view. Thoracic CT angiography was performed for the differential diagnosis of vascular anomalies and right aortic arch, aberrant LSCA and Kommerell diverticulum was detected (Figure 1). When the patient's history was questioned again with these findings, it was learned that he had occasional swallowing and sore throat problems while eating. Barium esophageal examination revealed compression of the posterior-left side at the proximal level of the esophagus (Figure 2).

### Discussion

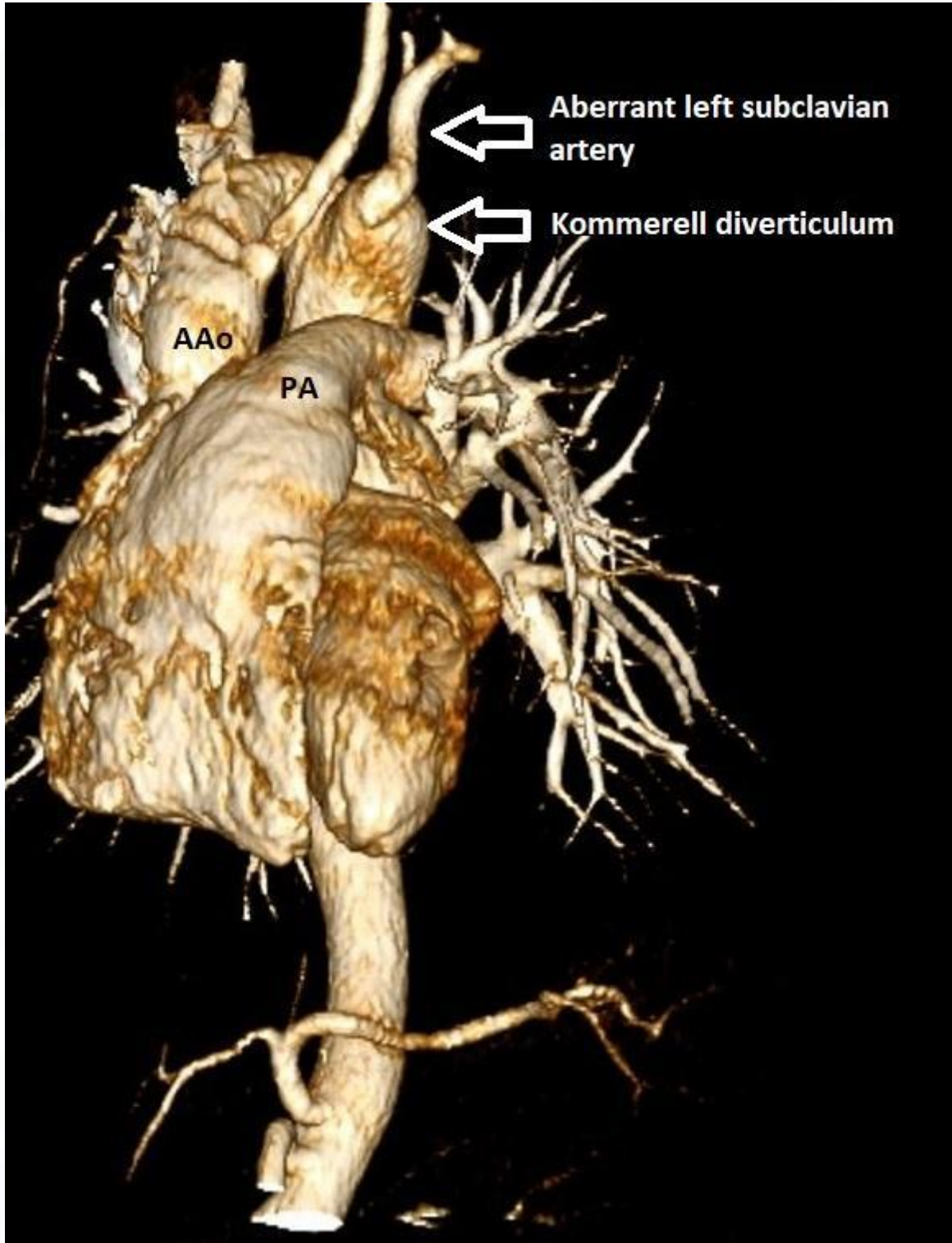
Clinical appearance of aortic arch anomalies are variable due to compression of vascular anomaly. Infants and children may present with signs related to compression of mediastinal structures such as the trachea or the esophagus or anomalies can be found incidentally during imaging studies obtained for other reasons (2). In normal embryologic development, the right 4th arch regresses while the left 4th arch gains continuity and forms a normal left arch (4). If the arcus anomaly, which arises as a result of insufficient regression of aortic arches and forms ring formation, these cases become symptomatic at neonatal and early infant periods. Respiratory distress and feeding problems can be seen due to compression of the trachea and esophagus.

In our case, aortic arch was enlarged as a diverticulum in the transverse aortic line from the descending aorta to the right (Kommerell diverticulum) and it was seen that the left subclavian artery was separated aberrantly from the top of this structure. Barium esophageal x-ray showed vascular compression from the left posterior aortic arch in the proximal part of the esophagus. In his history, he had a feeling of stuck in the throat from time to time but did not describe clinically significant respiratory symptoms. Pediatric gastroenterological evaluation revealed that the patient's symptoms are mild and did not require surgical intervention and clinical follow-up was taken.

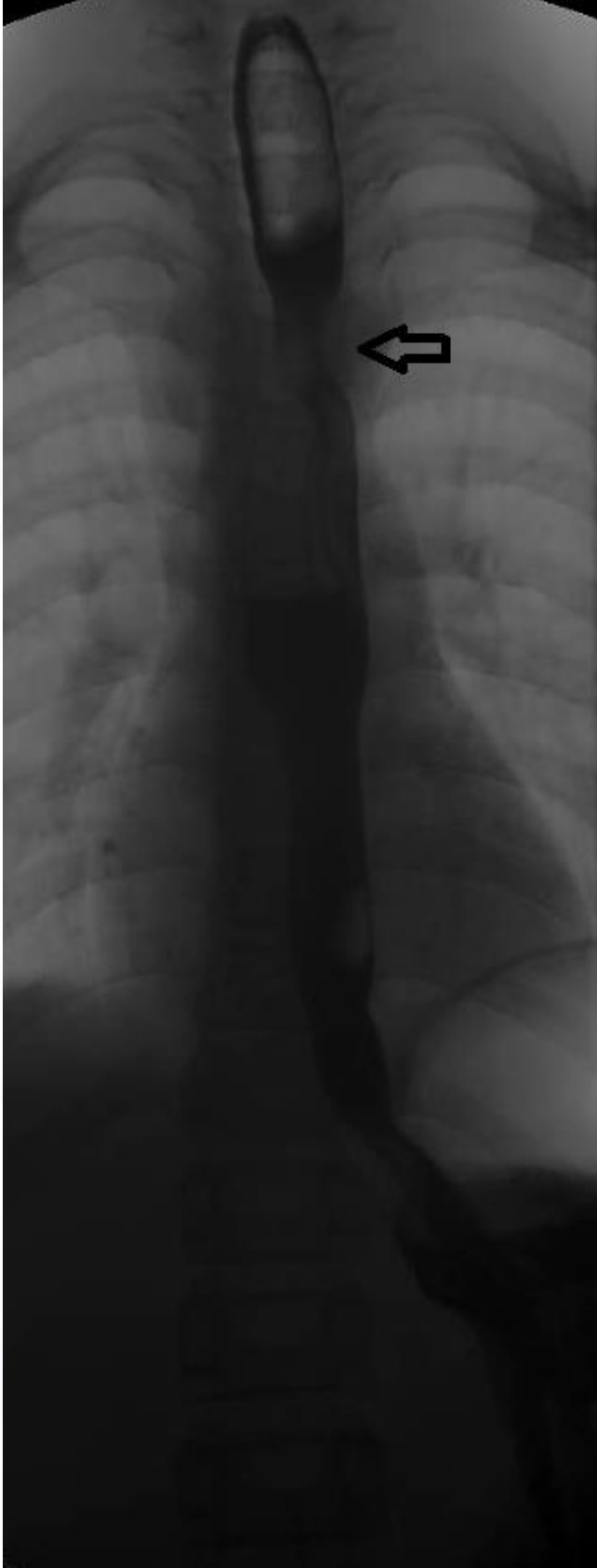**Conclusion:** Patients without surgical correction of aortic arch anomalies and Kommerell diverticulum should be closely monitored to detect early aneurysm formation and pressure to the mediastinal structures.

### References

1. Guron N, Oechslin E, .Congenital Aortic Arch Anomalies: Lessons Learned and to Learn; *Canadian Journal of Cardiology* 2019;35:373-375
2. Jadranka Stojanovska J, Cascade P, , Suzanne Chong S, , et all. Embryology and Imaging Review of Aortic Arch Anomalies *J Thorac Imaging* 2012;27:73–84
3. Luciano D., Mitchell J., Fraisse A., et All Kommerell Diverticulum Should Be Removed in Children With Vascular Ring and Aberrant Left Subclavian Artery *Ann Thorac Surg* 2015;100:2293–7
4. Matherne GP, Lim DS. Double aortic arch. In: Allen HD, Driscoll DJ, Shaddy RE, Feltes TF, editors. *Moss & Adams heart disease in infants, children & adolescents: including the fetus and young adults*. Philadelphia: Lippincott Williams & Wilkins; 2008. p. 749-52



**Figure1:** CT angiographic examination of the thoracic aorta reveals the right aortic arch extending from the descending aorta to the transverse aorta line (Kommerell diverticulum) and aberrant left subclavian artery was separated from the top of this structure.  
AAo: Aorta Ascendens PA: Pulmoner artery



**Figure 2:** Esophageal x-ray with barium shows vascular compression (arrow) in the proximal part of the esophagus due to aortic arch.