

FT47

## Hinman Syndrome: Insidious Course of Chronic Kidney Disease

Zehra Nihan COŞKUN<sup>1</sup>, Bülent ATAŞ<sup>2</sup>

<sup>1</sup>Necmettin Erbakan Üniversitesi Meram Tıp Fakültesi, Çocuk Sağlığı ve Hastalıkları  
Anabilim Dalı, Konya

<sup>2</sup>Necmettin Erbakan Üniversitesi Meram Tıp Fakültesi, Çocuk Nefroloji Bilim Dalı, Konya

### ABSTRACT

**Introduction:** Hinman syndrome (non-neurogenic neurogenic bladder); is a severe voiding dysfunction that significantly affects the upper urinary tract due to the discordance between detrusor contraction and sphincter relaxation without neurological dysfunction. Typically, patients have incomplete bladder emptying and chronic urinary retention, urinary incontinence, day and night urinary incontinence, fecal retention, recurrent urinary tract infections, and renal dysfunction. Typically, patients have incomplete bladder emptying and chronic urinary retention, urinary incontinence, day and night urinary incontinence, fecal retention, recurrent urinary tract infections, and renal dysfunction. In this article, two cases followed up in pediatric nephrology clinic due to chronic kidney disease caused by Hinman syndrome are discussed.

**Cases:** The first case; a 12-year-old female patient presented to our pediatric nephrology clinic with complaints of sudden urination and urinary incontinence for three months. At the time of admission GFR was calculated as 23.7 ml / min / 1.73m<sup>2</sup> and bilateral hydronephrosis, bladder trabeculations and high detrusor pressure (51 cm / H<sub>2</sub>O) were determined. The second case; an 11-year-old male patient was presented to our clinic with the complaint of long-standing urinary urgency and daytime urinary incontinence. According to examinations GFR was found to be 34.5 ml / min / 1.73m<sup>2</sup> and severe hydronephrosis on the right, diverticula in the bladder and high detrusor pressure (49 cm / H<sub>2</sub>O) were detected. Spinal magnetic resonance imaging was found to be normal in both cases and the cases were evaluated as chronic kidney disease developing because of Hinman syndrome.

**Conclusion:** Bladder-sphincter coordination disorder can cause damage to the bladder and upper urinary tract, leading to the development of neurogenic bladder and chronic kidney disease when early diagnosis and effective treatment is not applied. Families and clinicians should be aware that urinary urgency and day and night urinary incontinence are not benign in every child, and they should be aware that it can have very serious consequences. Clinicians should keep this syndrome in mind in order to recognize the preventable cause of chronic kidney disease such as Hinman syndrome early.

**Keywords:** *Hinman syndrome, nonneurogenic neurogenic bladder, incontinence, chronic kidney disease*

### ÖZET

**Giriş:** Hinman sendromu (nonnörojenik nörojenik mesane); nörolojik işlev bozukluğu olmaksızın detrüör kasılması ve sfinkter gevşemesi arasındaki uyumsuzluk nedeniyle gelişen, üst üriner sistemi önemli derecede etkileyen ciddi işeme disfonksiyonudur. Tipik olarak hastalarda mesanenin tam boşalamaması ve kronik idrar retansiyonu, sıkışma bulguları, gece ve gündüz üriner inkontinans, fekal retansiyon, tekrarlayan idrar yolu enfeksiyonları ve böbrek fonksiyon bozuklukları görülür. Semptomlar ve radyolojik bulgular nörojenik mesanesi olan

FT-209

çocuklarla benzer olmasına rağmen Hinman sendromlu hastalarda, spinal nörolojik muayene ve manyetik rezonans görüntülemeleri normaldir. Bu yazıda Hinman sendromu sonucu gelişen kronik böbrek hastalığı nedeni ile çocuk nefroloji kliniğinde izlenen iki olgudan bahsedilmiştir.

**Olgular:** Birinci olgu; on iki yaşında kız hasta, üç aydır ani idrara sıkışma ve gece idrar kaçırma şikayeti ile çocuk nefroloji kliniğimize başvurdu. Yapılan incelemelerde başvuru anında GFR 23,7 ml/dk/1,73m<sup>2</sup> olarak hesaplandı, bilateral hidronefroz, mesanede trabekülasyonlar ve yüksek detrüör basıncı (51 cm/H<sub>2</sub>O) tespit edildi. İkinci olgu; on bir yaşında erkek hasta, uzun süredir devam eden ani idrara sıkışma ve gündüz idrar kaçırma şikayeti ile kliniğimize başvurdu. Tetkikler sonucu GFR 34,5 ml/dk/1,73m<sup>2</sup> bulundu, sağda ağır hidronefroz, mesanede divertiküller ve yüksek detrüör basıncı (49 cm/H<sub>2</sub>O) tespit edildi. Her iki olgunun da spinal manyetik rezonans görüntülemeleri normal bulundu ve olgular Hinman sendromu sonucu gelişen kronik böbrek hastalığı olarak değerlendirildi.

**Sonuç:** Mesane-sfinkter koordinasyon bozukluğuna, erken tanı konulup etkin tedavi uygulanmadığında; mesane ve üst üriner sistemde hasara neden olarak nörojenik mesane ve kronik böbrek hastalığı gelişimine yol açabilir. Aileler ve klinisyenler; sıkışma ve gece-gündüz idrar kaçırmanın her çocukta iyi huylu bir durum olmadığını bilincinde olmalıdırlar ve çok ciddi sonuçlara yol açabileceğinin farkında olmalıdırlar. Hinman sendromu gibi kronik böbrek hastalığının önlenabilir sebebinin erken tanıyabilmek için klinisyenler bu sendromu akılda tutmalıdırlar.

**Anahtar sözcükler:** *Hinman sendromu, nonnörojenik nörojenik mesane, inkontinans, kronik böbrek hastalığı*

## INTRODUCTION

In 1971 Frank Hinman and Franz Baumann; described Hinman syndrome (HS) as a condition that is not associated with any neurological lesion and that the bladder does not fully discharge as a result of narrowing of the external urethral sphincter due to coordination disorder between sympathetic and parasympathetic activity (1,2). Initially, these patients were evaluated as neurogenic bladder dysfunction because of having unilateral or bilateral hydronephrosis, vesicoureteral reflux and irregularly shaped trabeculated bladder, but imaging of the central nervous system and spinal cord was normal. when these patients voluntarily urinate, their failure to relax the sphincter muscles causes changes in bladder wall thickness, vesicoureteral reflux, and progressive hydroureteronephrosis (3). As a result of detrusor decompensation, patients may have signs of urgency, day and / or night incontinence, chronic urinary retention, recurrent urinary tract infection, renal scarring and early age chronic kidney disease. It has been shown that especially children who have incontinence during daytime and who exert external urethral sphincter muscle to prevent this leakage have excessive detrusor activity (4).

The aim of treatment in Hinman syndrome (HS) is the protection of the upper urinary tract and the prevention of renal damage. Early diagnosis and prevention methods are the basis of success in treatment. In the early stages of the disease; bladder education, psychological support and clean intermittent catheterization are recommended as conservative treatment methods. Today, anticholinergic drugs and constipation is not recommended because of increasing intestinal constipation, increasing residual urine volume and causing urinary tract infections except for children who miss urine during daytime as a result of bladder overactivity. Invasive procedures such as botox injection into the external urethral sphincter have been described in the literature. If kidney damage has developed; instead of conservative methods, patients should be managed with surgical methods that protect kidney function and prevent the progression of damage (5).

## CASE 1

A 12-year-old female patient presented to our clinic with complaints of sudden urination and urinary incontinence. There was no consanguinity between the parents and no genetic disease in the family.

The patient, who had no known disease before, started to have urinary incontinence three months ago. There was no urinary incontinence or stool incontinence during the day, but she had had urinary urgency since the beginning of her childhood. He completed toilet training at the age of three. On physical examination, the patient was pale and her body weight was 3 percentile below the normal value. Blood pressure was measured as 120/75 mmHg. Other system examinations were normal. Anemia (Hb: 8.5 g / dL), metabolic acidosis (pH: 7.30 and bicarbonate: 19 mmol / L) were observed. GFR was found to be 23.7 ml / min / 1.73m<sup>2</sup> and chronic kidney disease was detected. Bilateral renal enlargement and hydroureteronephrosis and trabeculation in the bladder are observed in Abdominal ultrasonography. Increased bilateral renal size, more severe on the left, and bilateral severe hydroureteronephrosis are detected in MR pyelography (figure 1). Voiding cystoureterography showed mild irregularities in the bladder contours and diverticulas was partly observed. The capacity was normal (figure 2). Vertebrae and spinal cord were normal in magnetic resonance imaging. After high detrusor pressure (51 cm / H<sub>2</sub>O) and dissynergy between detrusor and external urethral sphincter were detected in urodynamic study, the patient was diagnosed as Hinman Syndrome. He had no complaints related to gastrointestinal retention. Phenotype was normal and the family did not have any genetic kidney disease. Family education, voiding recommendations, clean intermittent catheterization, pediatric urology follow-up and antibiotic prophylaxis for the prevention of renal damage in the long term were started. The patient is being followed up in our clinic because of chronic kidney disease as a result of Hinman syndrome.

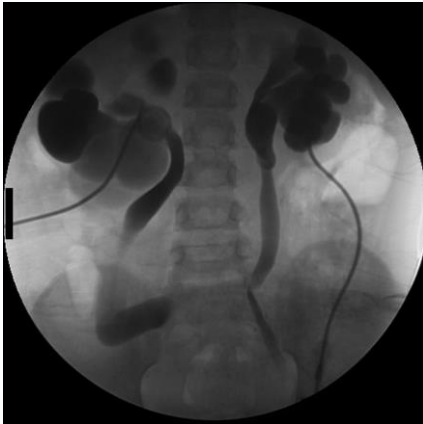

Figure 1. MR pyelography: Bilateral increase in renal size and hydroureteronephrosis

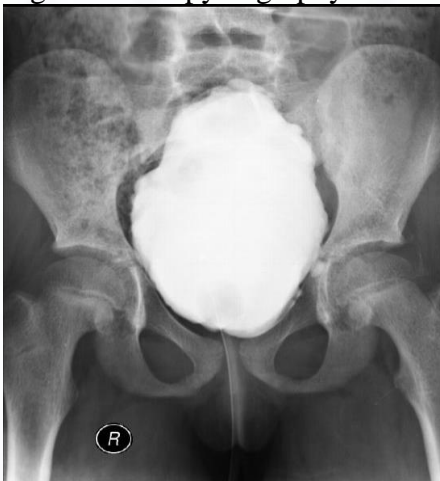

Figure 2. Voiding cystoureterography: Irregularity and diverticulas in some parts in bladder contours Voiding cystoureterography

#### CASE 2

An eleven-year-old mentally retarded male patient presented to our clinic with complaints of daytime incontinence, urgency symptoms and intermittent urination since his childhood. There was no urinary incontinence or no constipation. Toilet training could not be completed. She had febrile convulsions in the newborn period. There was no consanguinity between the parents and no genetic disease in the family. When the patient was four years old, she had undergone three surgical operations through the urinary system due to recurrent urinary tract infection, right vesicoureteral reflux, and left ureterovesical stenosis. He was still having urinary incontinence during daytime. On physical examination, the patient was mentally retarded and her body weight was 3 percentile below normal value. Blood pressure was measured as 120/80 mmHg. Other system examinations were normal. GFR was found to be 34.5 ml / min / 1.73m<sup>2</sup> and chronic kidney disease was detected. Abdominal ultrasonography showed severe hydronephrosis in the right kidney; atrophy was seen in the left kidney. The bladder wall was thick and trabecular in appearance. Voiding cystoureterography showed right grade 5 VUR, mild irregularity in the bladder, and diverticulae (figure 3). Vertebrae and spinal cord were normal in magnetic resonance imaging. In urodynamic study, high detrusor pressure (49 cm / H<sub>2</sub>O) and dyssynergy between detrusor and external urethral sphincter were detected and the patient was diagnosed as Hinman Syndrome. He had no complaints related to gastrointestinal retention. Phenotype was normal and the family did not have any genetic kidney disease. Family education, voiding recommendations, clean intermittent catheterization, pediatric urology follow-up and antibiotic prophylaxis for the prevention of renal damage in the long term were started. The patient is being followed up in our clinic because of chronic kidney disease as a result of Hinman syndrome.

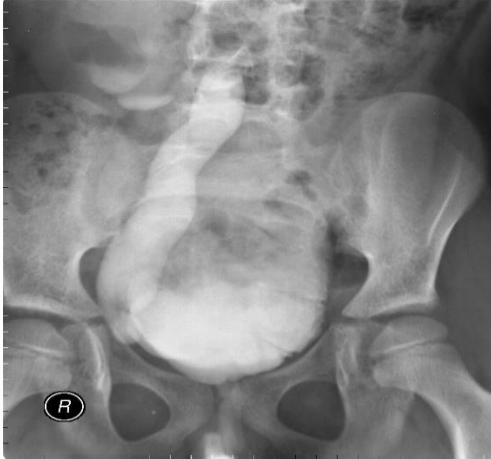


Figure 3. Voiding cystoureterography showed mild irregularity in the bladder, right grade 5 VUR

#### ARGUMENT

HS is a severe voiding dysfunction that affects the upper urinary tract with bladder dysfunction in the absence of a neurological abnormality (6). Hinman syndrome is a functional bladder outlet obstruction due to detrusor-sphincter dyssynergia, and these children typically experience intermittent voiding, day and night incontinence, recurrent urinary tract infections, constipation and encopresis. The patients often have vesicoureteral reflux, trabecular bladder, and decreased urinary flow rate. In severe cases, hydronephrosis, renal damage and end-stage renal disease may occur. Urodynamic studies and MRI of the spine are required to exclude neurological causes of bladder dysfunction (7). The main objective is to protect the upper urinary tract and prevent progressive renal damage. Bladder training, transient suprapubic catheters, clean

intermittent catheterization, drug therapy, and psychotherapy can prevent serious kidney damage and stabilize renal function. Urinary retention, urinary incontinence dysfunction, high detrusor pressure, bladder diverticulum, vesicoureteral reflux, renal damage and chronic kidney disease developed in both cases without any neurological disorder. During our follow-up, antibiotic prophylaxis was given and clean intermittent catheterization was performed to prevent recurrent urinary tract infections and to reduce renal damage and to postpone the progress of chronic kidney disease.

## CONCLUSION

Hinman syndrome is a rare but more serious condition among voiding disorders. This detrusor-sphincter mismatch causes upper urinary tract damage and, therefore, chronic kidney disease if not diagnosed and treated early. Clinicians should be able to recognize the preventable cause of chronic kidney disease such as Hinman syndrome early; they should be aware that incontinence is not always innocent, and this syndrome should be kept in mind when evaluating patients. In this article, it is aimed to emphasize the importance of careful examination and follow-up of patients presenting with urinary incontinence.

## References

1. Hinman F, Bauman FW (1973) Vesical and ureteral damage from voiding dysfunction in boys without neurologic or obstructive disease. *J Urol* 109:727–732
2. Rashid S, Waqar M, Khawaja AA, Arshad MS, Sarwar MK (2011) Efficacy of transcutaneous nerve stimulation (TENS) therapy in overactive non-neurogenic neurogenic bladder (Hinman's syndrome). *Pak J Med Sci* 27:528–532
3. Allen TD: The non-neurogenic neurogenic bladder. *J Urol* 1977; 117: 232.
4. McGuire EJ, Savastano JA (1984) Urodynamic studies in enuresis and the nonneurogenic neurogenic bladder. *J Urol* 132:299–302
5. Yılmaz AÇ, Buyukkaragoz B, Kivilcim S, Tayfur AC, Gunbey S. An adolescent boy progressing insidiously to end-stage renal disease: Answers. *Pediatr Nephrol*.2018 Mar;33(3):429-431. Epub 2017 Jun 19. PubMed PMID: 28631041.
6. Van Gool J, Tanagho EA. External sphincter activity and recurrent urinary tract infection in girls. *Urology*. 1977;10:348–53.
7. Robert M. Kliegman, Bonita F. Stanton, Nina F. Schor, Joseph W. St Geme Nelson Textbook of Pediatrics, 20th Edition Elsevier Inc, 1600 John F. Kennedy Blvd. Ste. 1800 Philadelphia, PA 19103-2899, p2583, 2016