

A Rare Complication After Cesarean Section: Vesicouterine Fistula

Eser Ördek*, Eyyup Sabri Pelit, Bülent Kati

DOI: 10.17944/mkutfd.676883

Eser Ördek: Res. Asst. Dr., Harran University Faculty of Medicine, Research and Application Hospital, Department of Urology, Şanlıurfa
Email: dr_eseser@hotmail.com
ORCID id: <https://orcid.org/0000-0001-6737-4259>

Eyyup Sabri Pelit: Assoc. Prof. Dr., Harran University Faculty of Medicine, Research and Application Hospital, Department of Urology, Şanlıurfa
Email: dreyyupsabri@hotmail.com
ORCID id: <https://orcid.org/0000-0001-8550-5072>

Bülent Kati: Assoc. Prof. Dr., Harran University Faculty of Medicine, Research and Application Hospital, Department of Urology, Şanlıurfa
Email: bulentkati@yahoo.com
ORCID id: <https://orcid.org/0000-0002-4024-5147>

Bildirimler/Acknowledgement

* Sorumlu Yazar/Corresponding Author

Çıkar Çatışması/Conflict of Interest

Yazarlar bu makale ile ilgili herhangi bir çıkar çatışması bildirmemişlerdir.
The authors declare that they have no conflict of interests regarding content of this article.

Maddi Destek/Financial Support

Yazarlar bu makale ile ilgili herhangi bir finansal destek bildirmemişlerdir.
The Authors report no financial support regarding content of this article.

Etik Beyan/Ethical Declaration

Yazarlar, bu çalışmada tanımlanan olgudan gerekli izin alınarak "Aydınlatılmış onam formu" nun düzenlenmiş olduğunu, çalışmanın yürütülmesi esnasında Helsinki Beyanname'si 2013, ICMJ tavsiyeleri ile COPE'un Editör ve Yazarlar için Uluslararası Standartlarının yanısıra ilgili diğer biyoetik kılavuzların dikkate alındığını beyan etmişlerdir.

Informed consent was obtained from the participant and Helsinki Declaration rules were followed to conduct this study.

Geliş/Received: 20.01.2020

Düzeltilme/Revised: 14.07.2020

Kabul/Accepted: 05.09.2020

e-ISSN: 2149-3103

Web: <http://dergipark.org.tr/mkutfd>

Öz

Sezeryan Sonrası Görülen Nadir Bir Komplikasyon: Vezikouterin Fistül

Vezikouterin fistüller çoğunlukla jinekolojik ve obstetrik cerrahlere bağlı iyatrojenik nedenlerle meydana gelen ve nadir görülen (%1-4) genitoüriner fistüllerdendir. Çoğunlukla iyatrojenik sebeplerle meydana gelirler. Sezaryen sonrası görülen, üriner inkontinansın eşlik etmediği, amenore ve siklik hematuriyeye sebep olan vezikouterin fistüllere Youssef sendromu denilmektedir. Bu makalede beşinci sezaryen ameliyatı sonrası gelişen bir vezikouterin fistül olgusunu literatür bilgileri ışığında sunmayı planladık.

Anahtar Kelimeler: Sezeryan, Vezikouterin Fistül, Youssef's Sendromu

Abstract

A Rare Complication After Cesarean Section: Vesicouterine Fistula

Vesicouterine fistulas are rarely seen (1-4%) genitourinary fistulas which occur mostly due to iatrogenic reasons related to gynecologic and obstetric surgeries. They are mostly caused by iatrogenic reasons. Vesicouterine fistulas which are seen after cesarean section, which are not accompanied by urinary incontinence but cause amenorrhea and cyclic hematuria are called Youssef syndrome. In this article, we aim to present a case of vesicouterine fistula which developed after the fifth cesarean section, in the light of the literature.

Keywords: Cesarean Section, Vesicouterine Fistula, Youssef's Syndrome

INTRODUCTION

Vesicouterine fistula is an infrequent disease group classified among genitourinary fistulas. They are mostly caused by iatrogenic reasons (1). Vesicouterine fistulas which are seen after cesarean section, which are not accompanied by urinary incontinence but cause amenorrhea and cyclic hematuria are called Youssef syndrome (2). In this article, we aim to present a case of vesicouterine fistula which developed after the fifth cesarean section, in the light of the literature.

CASE

A 28-year-old woman applied to our outpatient clinic with complaints of macroscopic hematuria and amenorrhea during menstruation period. It was learned that 3 months ago the fifth cesarean section was performed at an another center and the Foley catheter was removed and patient discharged on the postoperative 1st day. Patient states that in the postoperative period, there was intermittent hematuria for a month and then this condition decreased gradually. The patient did not have any complaint of urinary incontinence. Abundant erythrocytes and leukocytes detected in urinalysis. There was no pathologic finding of any hydronephrosis or ureteral dilatation in urinary system sonography. At the same time, vaginal examination revealed no pathological findings in external genitourinary organs. The patient was inflated with a foley catheter and inflated with approximately 300 cc of sterile contrast saline. Cystogram showed no contrast material extravasation from the bladder, but contrast agent transition was observed toward the posterior of the bladder, filling the uterine structure (Image 1).

The patient was then advised for a diagnostic cystoscopy. The timing of cystoscopy was scheduled to coinciding with the patient's menstruation period. On cystoscopy which is performed on 3rd day of the menstruation period, a fistula mouth with the diameters of 1.5x1 cm was found just behind the trigone, at the junction of the posterior wall and the bladder base (Image 2).

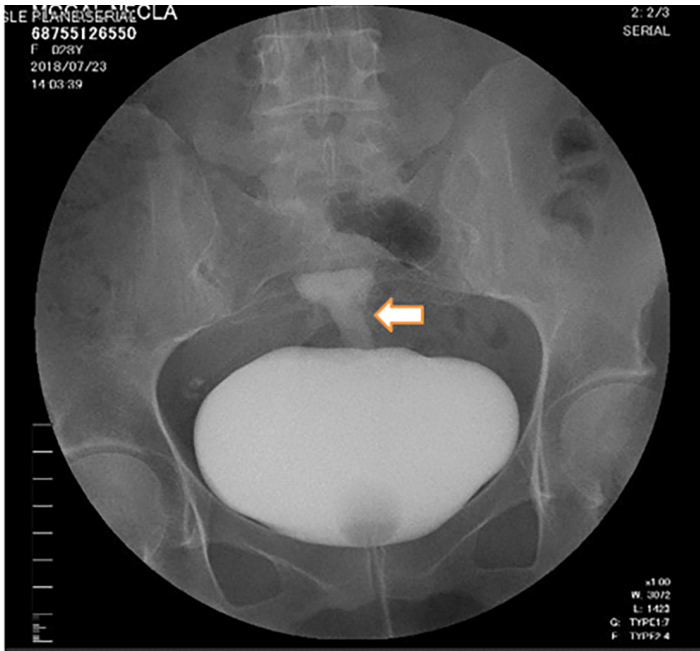


Image 1. Cystogram: Vesicouterine fistula tract (indicated by arrow)

Simultaneous examination with cystoscopy revealed bleeding from the mouth of the fistula (menstruation bleeding). The situation was explained in details to the postoperative patient and decision is made for an open vesicouterine fistula repair. Surgical repair planned after written consent was obtained.

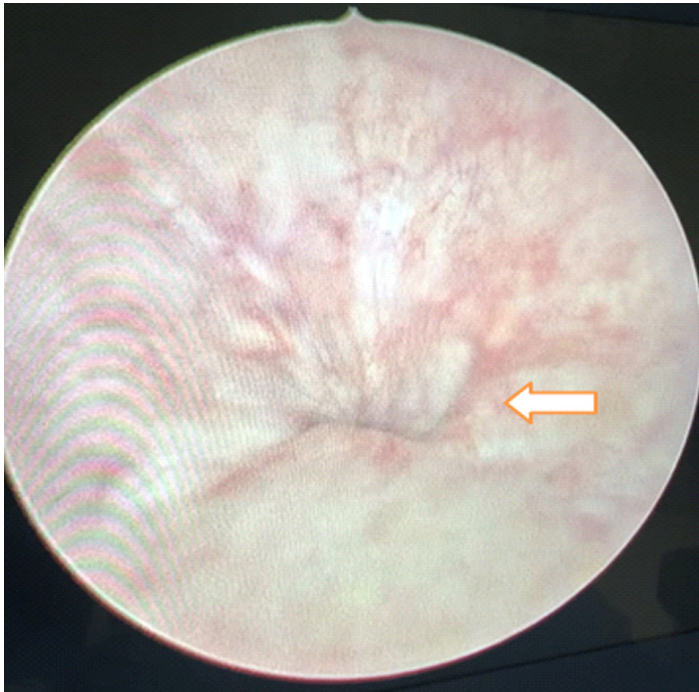


Image 2. Cystoscopy: Vesicouterine fistula mouth (indicated by arrow)

Surgical Technique

16 Fr 2-way Foley catheter was placed in supine position under sterile conditions; the bladder was inflated with 200 cc of saline solution, and then the anatomical layers were crossed with a median incision inferior to the umbilicus. Following incision, the bladder was separated from peritoneal layer. Then, transperitoneally, the fistula tract was reached between the corpus-cervix at the anterior of the uterus. The bladder dome was incised as exposing the bladder and the incision was advanced to the fistula tract at the posterior. Tract of the fistula was completely excised, including its mouths in the bladder and uterus. The bladder wall was combined in double layers as mucosa and serosa. Then the bladder was filled with saline to test the leakage and no leakage observed. The opening in the uterus wall was closed in two layers with number zero polyglycolic acid suture. Then, a sufficient length of omentum flap was prepared and fixed on the repaired area of the bladder. On the 3rd postoperative day, drains were taken out. At postoperative 14th day, the patient's Foley catheter was removed after control cystography (Image 3). At the first week and first month follow-ups, cyclic hematuria was discontinued and menstrual cycles has started.

Ethical Declaration

Informed consent was obtained from the participant and Helsinki Declaration rules were followed to conduct this study.

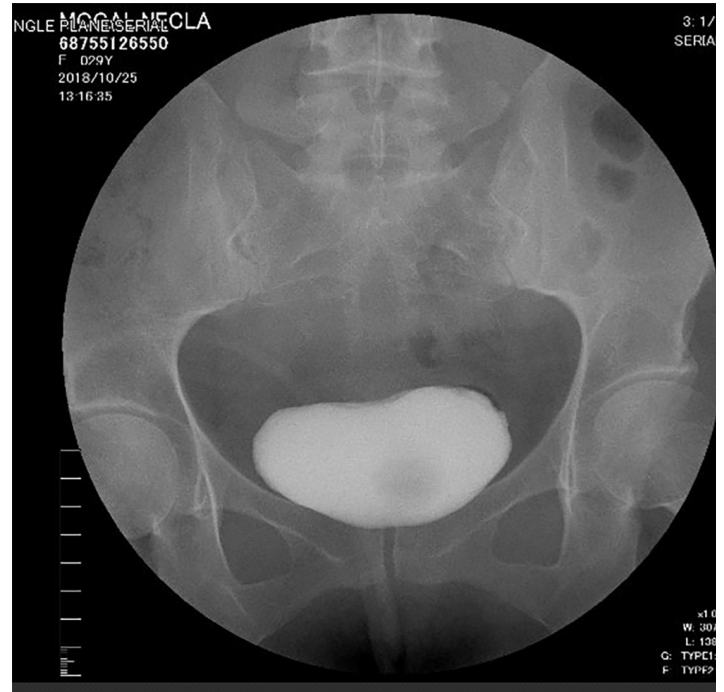

Image 3. Postoperative cystogram: No contrast filling was observed in the endometrial cavity with the repair of the vesicouterine fistula tract.

DISCUSSION

Vesicouterine fistula is a very rare condition and is estimated to occur in only 1-4% of all genitourinary fistulas (3). In 90% of the cases, menstrual disorders and cyclic hematuria (menuria) are accompanied. It is a rare entity with cyclic hematuria, amenorrhea and absence of urinary incontinence (Youssef syndrome). It is a rarely occurring fistula between the bladder and uterus, which is secondary to iatrogenic etiologies following cesarean section. Increased cesarean rates in recent years have increased the incidence of surgery related complications such as genitourinary fistulas. The clinical presentation of vesicouterine fistula may vary. Patients may present with complaints such as urinary incontinence, menstrual disorder and cyclic hematuria. In addition, it may cause clinical conditions like secondary infertility and abortus (6). Especially in the case of cyclic hematuria, vesicouterine fistulas should come to mind; likewise, endometriosis should be considered. In our case, the classic triad of Youssef syndrome was there: cyclic hematuria, severe menstrual bleeding and absence of urinary incontinence. The diagnosis of vesicouterine fistula is made by exclusion of common urogenital fistulas and showing the fistula tract between the bladder and uterus. Intravenous pyelography (IVP), hysterosalpingography, cystography, methylene blue test, transvaginal ultrasonography, pelvic MRI and cystoscopy can be used in the diagnosis. These diagnostic tests have several advantages and disadvantages. While cystography is diagnostic in vesicovaginal fistulas, it may not be sufficiently helpful in diagnosis of vesicouterine fistulas because uterine pressure is higher than the intravesical pressure. Urethrocystoscopy can reveal the presence of a fistula, but if the fistula is not wide, it is not useful in determining where the tract extends. In addition to recent developments in the field of radiology, it is possible to diagnose fistula with CEUS (contrast-enhanced ultrasound-contrasted ultrasound), which is also called acoustic contrast imaging. CEUS is a new technology that significantly enhances the solubility, sensitivity and specificity of ultrasonic diagnosis by enhancing the scattering echo using contrast agent. (7). The intravesical CEUS, vesicouterine fistula or intraperitoneal bladder fistula with the use of contrast agent dynamically demonstrates the perfusion process of the fistulae, as well as the relationship, size, shape and anatomical relationship of the fistula with surrounding tissues. In our case, a large fistula mouth was seen during cystoscopy and menstruation bleeding was observed flowing through the fistula tract. Currently, conservative approach or surgical techniques are used in the treatment of vesicouterine fistula. If the diagnosis of uterovesical fistula is made immediately after birth, observation with Foley probe for four to eight weeks might be enough for spontaneous closure of the fistula tract (3,4). Our patient presented to our clinic with complaints three

months after cesarean section and had no examination during that period in any center. Transvaginal, transvesical and transperitoneal approaches have been described in the surgical repair of the uterovesical fistula. The main purpose of these surgeries is excision of the fistula tract and to provide support tissue between bladder and uterus after they have been repaired. Omentum can be placed between uterus and the bladder, as well as harvesting free fat tissue graft from abdominal fat tissue is described in the literature. In recent years, minimally invasive methods such as laparoscopic fistula repair, fistula repair with robotic surgery and fistula repair with single-port laparoscopic surgery have been reported for uterovesical fistula repair (5).

CONCLUSION

Emptying of the bladder before gynecological and obstetric surgeries, strict adherence to surgical rules and careful dissection of uterus can reduce the risk of genitourinary fistula formation. Genital urinary fistulas may occur after pelvic surgeries, especially in gynecological and obstetric operations. Repetitive gynecologic operations and repeated cesarean section surgeries increase the risk of vesicouterine fistula formation. In case of cyclic hematuria appearing after cesarean section, uterovesical fistulas should be considered first.

References

1. Lenkovsky Z, Pode D, Shapiro A, Caine M. Vesicouterine fistula: a rare complication of cesarean section. *J Urol.* 1988; 139:123-5. [https://doi.org/10.1016/S0022-5347\(17\)42315-9](https://doi.org/10.1016/S0022-5347(17)42315-9)
2. Youssef, A.F. Menouria following lower segment caesarean section. *Am. J. Obstet. Gynecol.* 1957; 73:759-67. [https://doi.org/10.1016/0002-9378\(57\)90384-8](https://doi.org/10.1016/0002-9378(57)90384-8)
3. Molina LR, Lynne CM, Politano VA. Treatment of vesicouterine fistula by fulguration. *J. Urol.* 1989; 141: 1422-3. [https://doi.org/10.1016/S0022-5347\(17\)41333-4](https://doi.org/10.1016/S0022-5347(17)41333-4)
4. Hemal AK, Wadhwa SN, Kriplani A, Hemal U. Youssef's syndrome: An appraisal of hormonal treatment. *Urol. Int.* 1994; 52: 55-7. <https://doi.org/10.1159/000282572>
5. Bettez M, Breault G, Carr L, Tu LM. Early versus delayed repair of vesicouterine fistula. *Can Urol Assoc J.* 2011;5(4):E52-5 <https://doi.org/10.5489/auaj.10065>
6. Akter MD, Islam F, Tasnim S. How tragic is the woman's life? Uterovesical fistula: A case report. *Medicine Today.* 2012;23:55-7. <https://doi.org/10.3329/medtoday.v23i1.11948>
7. Mao R, Xu EJ, Li K, vd. T-tüpü çıkarıldıktan sonra biliyer kaçak teşhisinde kontrastlı ultrason kullanımı. *J Clin Ultrason* 2010; 38: 38-40.