

Immediate dentures and histological changes of bone under pressure

(An experimental investigation in rats) (*)

Senih ÇALIKKOCAOĞLU (**)

I n t r o d u c t i o n

Normal bone changes constantly throughout the life. The reason for that is the process of resorption to occur in all skeletal system. This particular process eliminates the old bone and a reverse process, namely the apposition helps to compensate the loss and maintain the shape and the size of bone almost the same. Histologically, bone resorption and apposition occur in close approximation. This makes possible the bone to keep its balance.

The etiologic factors of the alveolar bone resorption may be classified as pathologic and physiologic. Although the various factors may be divided into these groups for academic purposes, they are so interrelated that it is almost impossible to evaluate one single factor in this chaotic situation.

The condition that leads to osteoclastic activity which results in the resorption of bone are not fully understood. But it is believed basically correct that the organic components of intercellular sub-

(*) Revised from a thesis presented in partial fulfillment of the requirements for the (Dr. med. dent.) degree at the Faculty of Dentistry, University of İstanbul — Turkey.

(**) İ. Ü. Total - Parsiyel Kürsüsü Asistanı (Dr. med. dent.)

tance are removed by proteolytic action of the osteoclasts. Then, the inorganic calcium salts are dissolved by a chelating action of these particular cells. As resorption takes place, the osteocytes may revert to osteoclasts. This depends upon the physiologic and pathologic demands at that time. Also, the changes in the chemistry of bone play a dominant part as a stimulus for fibrocytes and osteocytes to metamorphose into osteoclasts to commence resorption.

Dentists generally tend to believe that the alveolar ridge resorption is the end results of pressure exerted by denture base. However, this seems a paradoxical situation. Because the chewing pressure causes both resorption and apposition. But the increase of pressure within the limits of physiologic tolerance results in bone apposition. But if pressure is severe enough to interfere with the blood and nerve supply, then resorption occurs.

However, the denture bearing bone has some anatomical advantages to resist the chewing pressure relatively better than the bones in the other parts of skeletal system.

In this study an experimental investigation has been undertaken to examine the changes of bone under immediate dentures and the effects of early functional stimulation of the alveolar residual ridges have been evaluated histologically.

Materials and Method :

The experimental animals were Wistar rats which weighed approximately 200 Gm. each. At the beginning, a few animals were sacrificed in order to determine the method to be used. For that, an animal with overdosed ether was killed and the mandible resected with the soft tissues intact. An alginate impression was made and poured into hard stone. So a model was obtained what we called the master cast on which 30 immediate dentures were made with self curing acrylic resin after scraping the teeth to be extracted. The dentures have been polished well so they do not irritate soft tissues. Then two small holes were drilled with a round bur, a little farther anteriorly next to the incisor teeth.

Under general anesthesia in ether, the right mandibular first and second molars of 60 Wistar rats were removed and immediate

dentures which were made previously have been placed into the mouths of 30 experimental rats. The dentures were fixed into the mouths by passing the silk thread through the lingual and labial side of the mandible on two sites by means of a surgical needle. Thread was tied in the midline under the mental region.

The control animals had no immediate dentures inserted upon the removal of their above mentioned teeth.

Both the control and experimental animals were divided into 3 groups of 10 rats in each one. The experimental animals kept their dentures in their mouths for 13, 23 and 33 days according to their decided groups. The animals in each group were put into cages separately, and every care was given for their well beings.

In the end of the particular days, the animals in each group were sacrificed one by one and their mandible were resected and cleaned out of soft tissues as possible as it could. The first and second molar areas were then cut off with a sharp knife almost 2 mm. in length and fixed in 10 % formol solution. They were then decalcified in 10 % nitric acid - formol solution.

Serial cuts were then made from the paraffin blocks and stained in Hematoxylin-Eosin to examine the histologic changes of bone.

F i n d i n g s :

C o n t r o l g r o u p : These three groups consist of 10 animals in each one which have no immediate dentures inserted upon the removal of teeth.

At the end of 13 days —

The bone socket is filled with granulation tissue and resorption took place as it is expected. (Fig. 1)

At the end of 23 days —

The resorption process is still in action, especially next to the surface of the periodontal membrane. However, the labial and buccal surfaces of the alveolar bone seem to develop thickness due to apposition. (Fig. 3)

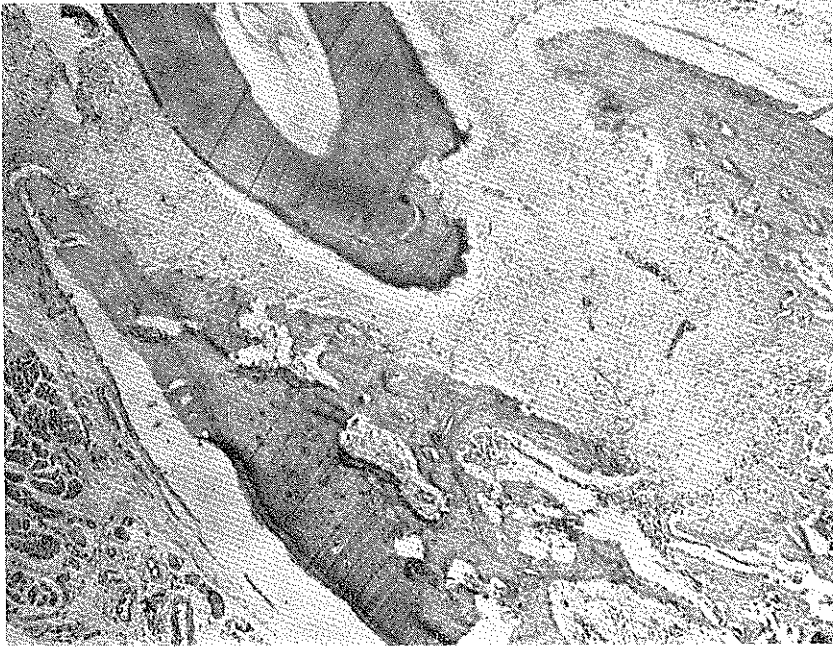


Fig : 1

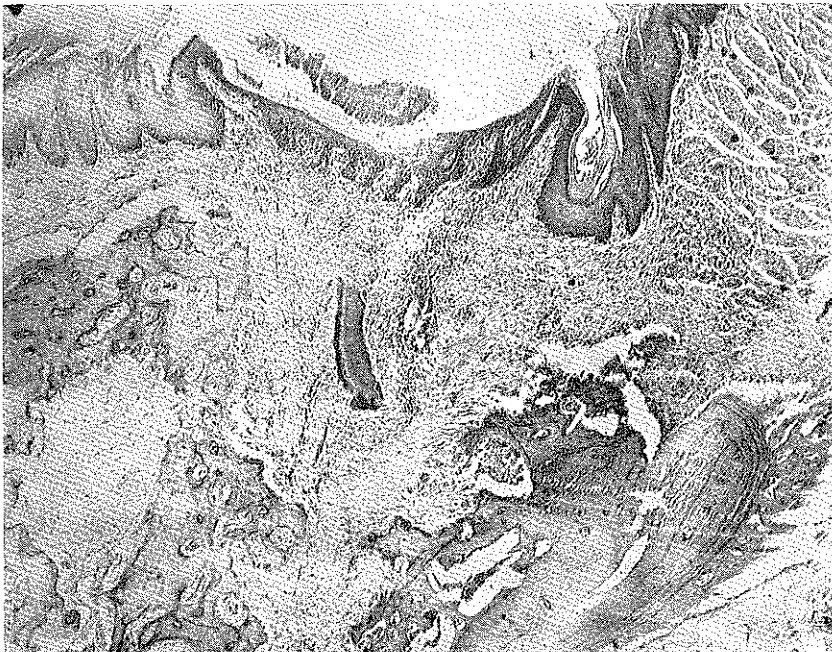
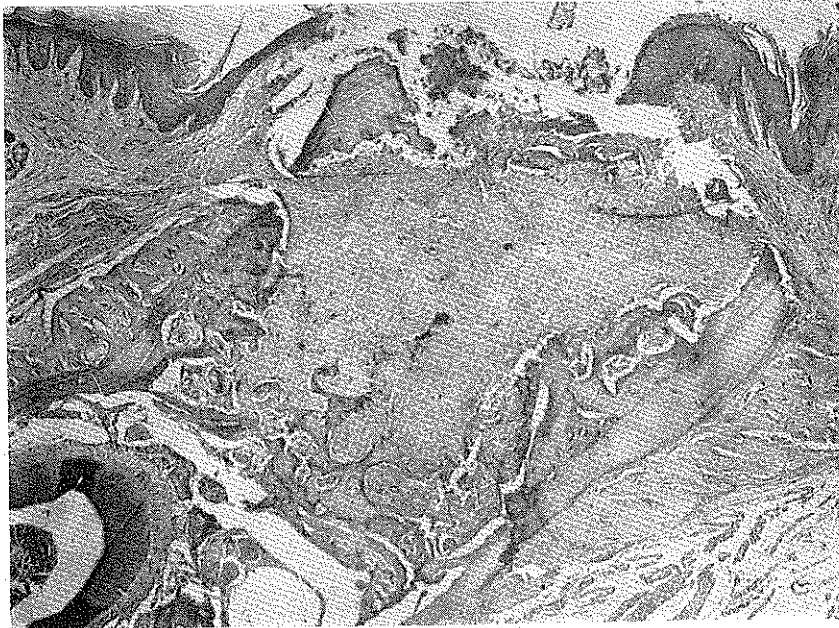


Fig : 2



Rig : 3

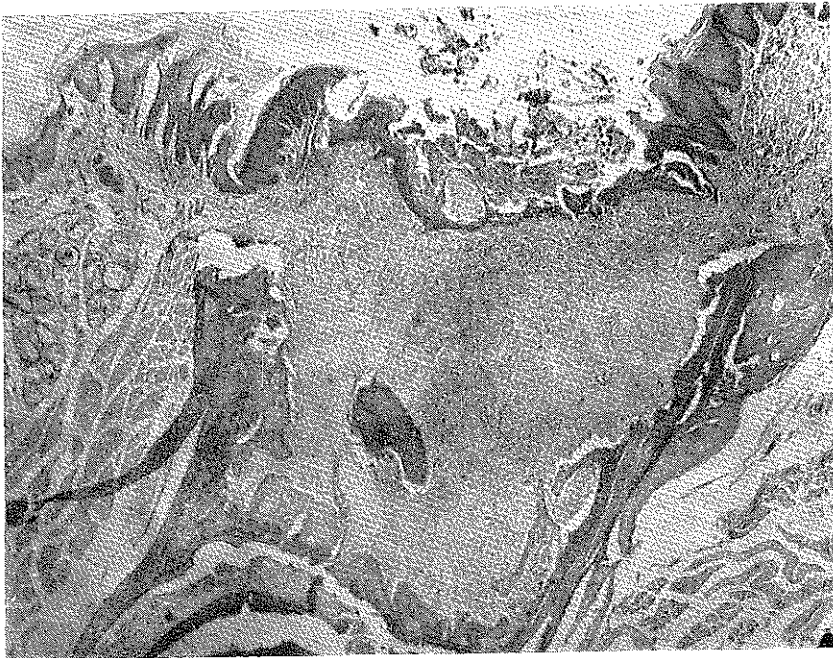

Fig : 4

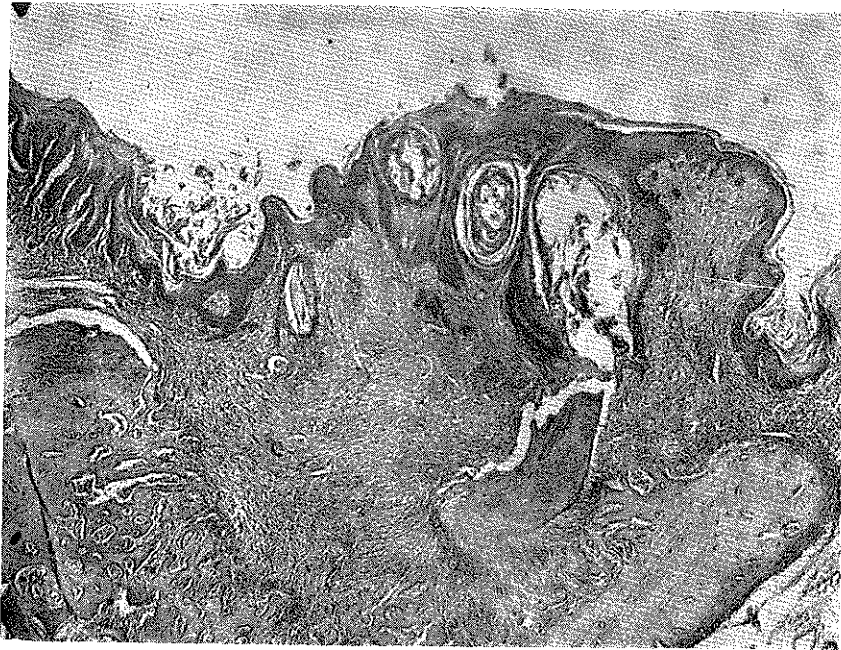

Fig : 5

At the end of 33 days —

The bone formation on the labial and the buccal side is significant. But the formation of new bone inside the socket is not very much. (Fig. 5)

Experimental group : These three groups consist of animals in each one which have immediate dentures inserted upon the removal of teeth.

At the end of 13 days —

The appearance of the residual alveolar ridge is almost normal. The socket is also filled with granulation tissue. (Fig. 2)

At the end of 23 days —

The new bone formation is more in the control group. (Fig. 4)

At the end of 33 days —

The formation of new bone is very marked and can be seen directly in the middle of the socket as it is shown in (Fig. 6)

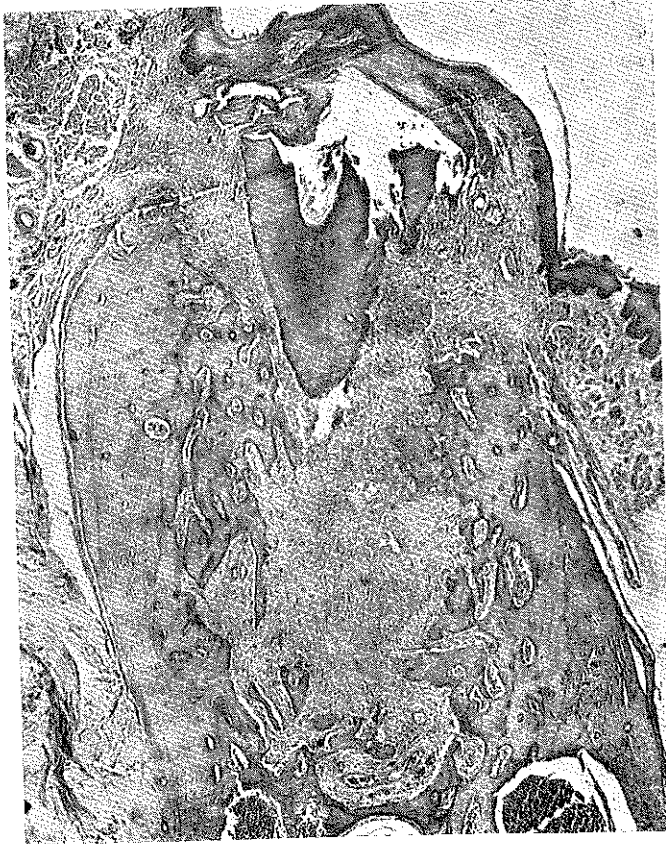

Fig : 6

As a result, in the experimental group the reduction of the residual alveolar ridge is less marked; the formation of new bone is quite significant and the epithelium covering the extraction wounds is regular. These findings are directly proportioned with the time involved.

In the other hand, the animals in the control groups showed the reduction of residual alveolar ridge, the decrease in the depth of

sockets and the irregularity of epithelium covering the extraction wounds.

Discussion :

The time factor is usually taken 60 years in human patients versus 3 years in rats in experimental studies. According to our point of view, this may be true for the degree of physiologic degeneration of the body at large. Even though the healing process in rats might be faster than in human beings, the speed of healing is expected to occur slower than 1/20 ratio.

In the end of definite time which was decided previously, the animals that showed inflammatory changes under the chin where dentures tied up via thread and on the soft tissues in the mouth are discarded. Only the «happy» animals which did not exhibit degenerative changes were taken to evaluate the effects of immediate dentures.

Our knowledge on the chewing mechanisms of rats is limited. It may well be possible for the animals not to chew their food on the side of appliance and preferred his own teeth. If this is so, the degree of pressure exerted by the denture base might be different.

As it is well known, the removable dentures exert intermittent pressure on tissues. Fixing the appliance in place by means of threads might be objected for having transmitted a continuous pressure on the denture bearing area. But the method of fixation via thread may allow prosthesis to come away from the mucosa just so far and no farther. It would then be expected the mucosa would receive the same intermittent stimulation. Because this method is not the one which stabilizes the appliance in place firmly such as a nail or a screw. We only hoped that the appliance would not fall off the mouth and allows a reasonable degree of movements which in turn gives an intermittent pressure.

The histologic changes caused by immediate dentures in human patients were only examined by direct methods such as radiographic and visual examinations. Although we definitely accept the differences between immediate dentures made for human patients and immediate appliances for rats, in our experiment we had been able to observe the changes of bone under immediate dentures in a given time.

We sincerely hope that this experiment will be followed by better ones to be done on bigger animals with similar chewing mechanisms to human beings.

Conclusion :

The early functional stimulation of bone tissue by immediate dentures within the physiologic limits of tolerance seems to help the formation of new bone faster than if it is left alone.

My sincere appreciation is expressed to Prof. Lem'i Belger at the department of Prosthodontics and Prof. Dr. Melih Tahsinođlu at the department of Pathology for their invaluable help in the evaluation of the materials and the data used in this investigation.

L İ T E R A T Ü R

- 1 — **Albright, F. ve Reifenstein, Jr.** : The parathyroid glands and metabolic bone disease, The Williams and Wilkins o., Baltimore, Sayfa : 78, 1948. (Ref Sharry 33)
- 2 — **Applegate, Ö. C.** : An evaluation of the support for the removable partial denture, J. Pros. Den., 10:112-123, 1960.
- 3 — **Asetine, L. F.** : Preparation of the mouth for immediate denture, J. Pros. Den., 1:151, 1951.
- 4 — **Atwood, D. A.** : Some clinical factors related to the rate of resorption of residual ridges, J. Pros. Den., 12:441-450, 1962.
- 5 — **Atwood, D. A.** : Cephalometric study of the clinical rest position of the mandible. LL. The variability in the rate of bone loss following the removal of occlusal contacts, J. Pros. Den., 7:544-552, 1957.
- 6 — **Belger, L.** : Fonksiyon halinde bulunan çene kemiđi strüktürleri üzerinde arařtırmalar, İstanbul, Kader matbaası, 1951.
- 7 — **Body, L. H.** : Surgical preparation of denture bearing ridges, J. Pros. Den., 12:61, 1962.
- 8 — **Bahatirchuk, F. A.** : A study of bone resorption and the «osteoclast» problem by stain autoradiograph, Am. J. Anat., 113:117, 1963. (Ref. Paul Goldhaber, J. A. D. A., 68: 725-832, 1964)
- 9 — **Bourgoyne, J. R.** : Alveoloplasty in preparation for immediate denture insertion, J. Pros. Den., 1:254,1951.

- 10 — **Doğruer, F.** : Tebliğ, Atina Dişhekimliği kongresi, 1954.
(Ref. İlhan Çuhadaroğlu'nun doktora tezi)
- 11 — **Glickman, I., Clinical periodontology, 2. baskı, W. B. Saunders Co.** : Philadelphia and London, 1958. : 5.j
- 12 — **Goldhaber, P.** : Behavior of bone in tissue culture, in Sognaes, R. F. editor : Calcification in biological systems, Wash. D. C. 1960, Am. Ass. for the advancement of science. (Ref. Atwood 4).
- 13 — **Gottlieb, B.** : Some histological facts useful in orthodontic practice, Am. J. Ort. Surg., 28:167, 1942.
- 14 — **Hancox, N. M.** : The osteoclasts, Biol. Revs., Cambridge Phil. Soc., 24:448-471, 1949. (Ref. Sharry 33)
- 15 — **Jowsey, J.** : Age changes in human bone, Clin. Orthop. No: 17 sayfa : 210-217, 1960 (Ref. Sharry 33).
- 16 — **Kelly, E. K. ve Sievers, F. R.** : The influence of immediate dentures on tissue healing and alveolar ridge form, J. Pros. Den., 9:738-742, 1959.
- 17 — **Kramer, Ivor, R. H.** : Alveolar bone in health and disease with special reference to local factors. (Reprinted from the Dental Practitioner) Cilt XII, No: 9, Mayıs, 1962.
- 18 — **Lammie, G. A.** : The reduction of edentulous ridges, J. Pros. Den., 10:605, 1960.
- 19 — **Lerishe, R.** : The surgery of pain, Bailliere. Tindall and Cox., London, sayfa : 80, 1937. (Ref. Lammie 18).
- 20 — **Linenberg, W. B.** : Surgical preparation of the mouth for immediate dentures, J. Pros. Den., 13:95, 1963.
- 21 — **Manson, J. D. ve Lucas, R. B.** : Microradiographic study of age changes in the human mandible, Arch. Oral. Biol., 7:761, 1962 (Ref. Atwood 4)
- 22 — **Mc Lean, F. C. ve Bloom, W.** : Calcification and ossification : Mobilization of bone salts by parathyroid extract, Arch. Path., 32:315-333, 1941. (Ref. Sharry 33).
- 23 — **Mc. Lean, F. C. ve Urist, M. R.** : Bone, an introduction to the physiology of skeletal tissue, 2. baskı, Üni. of Chicago Press, Chicago, 1961. (Ref Atwood 4).
- 24 — **Moses, C. H.** : Biological emphasis in prosthodontics, J. Pros. Den., 12:695-710, 1962.
- 25 — **Neufeld, J. O.** : Changes in the trabecular pattern of the mandible following the loss of teeth, J. Pros. Den., 8:685-697, 1968 (Ref. Atwood 5).
- 26 — **O'Rourke, J. T.** : Significaiton of tests for biting strength, J. A. D. A. 38:627-633, 1949. (Ref. Sobolik 35).

- 27 — **Ortman, H. R.** : Factors of bone resorption of the residual ridges, *J. Pros. Den.*, 12:429-440, 1962.
- 28 — **Pendleton, E. C.** : Changes in the denture supporting tissues, *J. A. D. A.*, 42:1-15, 1951.
- 29 — **Pound, E.** : Achieving patient acceptance to immediate denture service, *J. A. D. A.*, 66:795-802, 1963.
- 30 — **Pound, E.** : An all-inclusive immediate denture technic, *J. A. D. A.*, 67:16-22, 1963.
- 31 — **Reifenstein, E. C. Jr.** : The relationship of steroid hormones to the development and management of osteoporosis in aging people, *Clin. Orthop.* 10:206-253, 1957 (Ref. Atwood 4).
- 32 — **Selye, H.** : Acta Inc. Medical Publisher, Montreal 1950 (Ref. Ortman 27).
- 33 — **Sharry, J. J.** : Complete denture prosthodontics, McGraw-Hill Co., Inc., Blakiston Division, sayfa: 268, 1962.
- 34 — **Simpson, H. E.** : Experimental investigation into the healing of extraction wounds in *Macacus rhesus* monkeys, *J. Oral Surg., Anesth. and D. Service*, 18:391-399, 1960 (Ref. Atwood 5).
- 35 — **Sobolik, C. F.** : Alveolar bone resorption, *J. Pros. Den.*, 10:612-617, 1960.
- 36 — **Stahl, S. S., Wisan, J. M. ve Miller, S. C.** : Influence of systemic diseases on alveolar bone, *J. A. D. A.*, 45:277-283, 1052 (Ref. Sharry 33).
- 37 — **Stones, H. H.** : Oral and dental diseases, 3. baskı. E. and S. Livingstone Ltd., Edinburgh, sayfa: 531-533, 1954 (Ref. Lammie 18).
- 38 — **Swenson, M. G.** : Complete dentures, 4. baskı, The C. V. Mosby Co., St. Louis, sayfa: 428, 1959.
- 39 — **Tench, R. W.** : Danger in dental reconstruction involving increase of the vertical dimension of the lower third of the human face, *J. A. D. A.*, and *D. Cosmos*, 25:566-570, 1938 (Ref. Atwood 4).
- 40 — **Terrell, W. H.** : Immediate restorations by complete dentures, *J. Pros. Den.*, 1:495, 1951.
- 41 — **Thomas, B. O.** : Gerodontology : The study of changes in oral tissues associated with aging, *J. A. D. A.*, 33:207-213, 1946 (Ref. Sharry 33).
- 42 — **Townsley, W.** : Influence of mechanical factors on development and structure of bone, *Am. J. Phys. Anthropol.*, 6:25-45, 1948 (Ref. Sharry 33).
- 43 — **Tylman, S. D. ve Tylman, S. G.** : Theory and practice of crown and bridge prosthodontics, 4. baskı, The C. V. Mosby Co., St. Louis, sayfa: 69, 1960.
- 44 — **Weinmann, J. P. ve Sicher, H.** : Bone and Bones, Fundamentals of bone biology, 2. baskı, The C. V. Mosby Co., St. Louis, 1955.