

## *Odontogenic myxoma : report of case*

Melih TAHSİNOĞLU, MD, and A. Sedat ÇÖLOĞLU, DMD. (\*)

Myxoma is a connective tissue tumor composed of stellate fibroblast-like cells dispersed in a myxomatous substance resembling the tissue of the umbilical cord.

Daniels (3) first reported a case of myxoma of the mandible in 1908. In 1947, Thoma and Goldman (17) discussed the tumor in the dental literature. Recently, groups of cases have been reviewed by Barros and others (2), Ghosh and others (4), Gorlin and others (5), Stout (16), and Zimmerman and Dahlin (19).

Myxomas of the bone are rare lesions which are usually found in the jaws (1, 8, 16). They are generally slow growing tumors associated with unerupted or congenitally missing teeth (2). These tumors apparently arise from the dental tissues. Thoma and Goldman (17) classified the myxomas as either osteogenic or odontogenic. They believed that osteogenic myxomas originated from retained islands of non-odontogenic mesenchymal cells. According to Large and others (10), when the calcified material present is identified as bone or as dentin or cementum, the lesion is classified accordingly as an osteogenic myxoma or an odontogenic myxoma. In one of their cases (Case 2), osteoid material and foci of calcification were shown.

Very few cases of myxoma with odontogenic epithelial rests had been presented (1, 7, 9, 12-15). Myxoma or myxofibroma is a

---

(\*) Department of Pathology, Faculty of Dentistry, University of Istanbul. Çapa, Istanbul / Turkey.

histologic description depending upon the amount of collagen which is present.

### **Report of Case**

Patient Y. D., a 29-year-old woman, profession worker, examined and operated in the Hospital of Labor Insurance in Istanbul. About two years ago, the patient had noticed a pain in the right mandibular area, with a mass between the premolar teeth. The mucosa which concerned the mass appeared intact and light pink in color with white spots on.

Radiographs of the area revealed an unilocular radiolucency (Fig. 1). The roots of the affected teeth were displaced and showed resorption of the lamina dura. The margins of the lesion were not visualised and within the radiolucency were finely trabeculated striations.

The operation was performed under intravenous anesthesia. The lesion was resected together with the affected teeth. The specimen consisted of premolars with a small yellowish-gray tumor between the roots of the mentioned teeth (Fig. 2).

Sections showed the typical odontogenic epithelial cells within the myxoma or/and myxofibroma (Figs. 3, 4 and 5).

When the patient was controlled six years after surgery, there was no evidence of recurrence.

### **Discussion**

In the twenty-six cases of Zimmerman and Dahlin (19), most of the patients were between the ages 10 and 29, the average age being reported as 30. This figure was shown as 28.5 years by Barros and others (2).

Myxomas occur more frequently in the mandible than the maxilla. Posterior areas of the jaws are most affected (4, 17, 19). Most of the cases have a multilocular appearance, and the margins of the lesions may or may not be noticeable (9). These lesions are frequently associated with unerupted teeth which are absent congenitally.

Excision or/and curettage is acceptable treatment for small lesions (19), but the recurrence rate is higher than the resected tu-

mors in such treatments. Resection is an excellent method for the extensive tumors (11). Killey and Kay (9) supported that the treatment should be radical surgery combined with radiotherapy.

Macroscopically, the specimen shows white-gray-yellowish color, with a jelly or lipomatous tissue consistency.

Isles of odontogenic epithelial cells are scattered throughout the myxomatous or myxofibromatous tissue, although they are rarely seen (1, 7, 9, 12-15). The myxomatous tissue resembles the stellate reticulum that is found in developing teeth staining poorly with hematoxylin and eosin. The nuclei are hyperchromatic and oval, and the cytoplasm is lightly basophilic and granular in nature. According to Sedano and Gorlin (14), the intercellular substance of this tumor is mucopolysaccharide. The intercellular substance of the myxoma has been identified as mucoid (17), mucus (19), and mucin (8). Some of the authors (7, 8) believe that myxoma is a true tumor derived from myxoblasts, and the myxoblast is an active mucopolysaccharide-secreting cell. Harrison (8) described a clear zone between the odontogenic epithelium and the myxomatous tissue, furthermore the mesodermal cells change to mucopolysaccharide-secreting cells by the induction of odontogenic epithelium. Reviewing his histochemical findings revealed that the intercellular substance composed of hyaluronic acid and chondroitin sulphate. With the electron microscope, he described a secretory function of the tumor (myxoblasts). Young and Ball (18) believed that the factor which is responsible in developing of the myxomas to be the poor function of the fibroblasts. This supports the idea of Thoma and Goldman (17) that the possible origin, they believed, was an odontogenic fibroma undergoing myxomatous degeneration.

We believe that the developing of the odontogenic myxomas and the ameloblastic fibromas are due to the maturity and the enough activity of the odontogenic epithelial cells for induction to the mesenchyme. When the epithelial odontogenic cells are mature, the tumor develops as an ameloblastic fibroma by the excellent induction of these epithelial cells on the mesenchyme. If the primitive odontogenic epithelial cells have no sufficient induction on the mesenchyme, the tumor appears as an odontogenic myxoma. This was well seen in a case of ameloblastic fibroma reported by Hammarström and others (6). In this case, a section from central part of the tumor showed myxomatous tissue containing only a few isles

of primitive odontogenic epithelium. In the odontogenic myxofibroma, the primitive epithelial cells may have a bit more activity to induce on the mesenchyme.

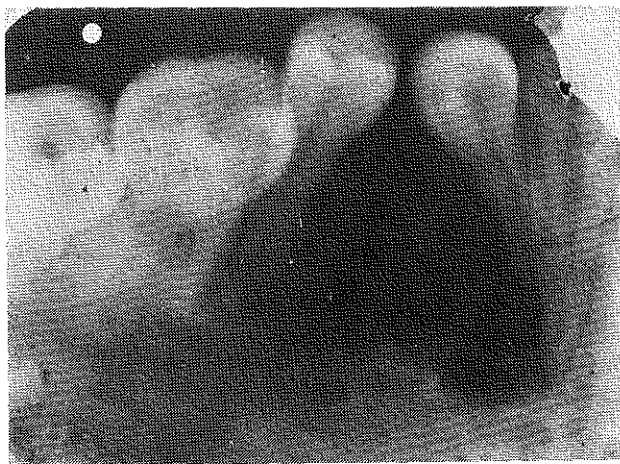


Figure 1. — A radiograph of the right side of the mandible of 29-year-old woman. An unilocular radiolucency was present in the bone between the premolar teeth.

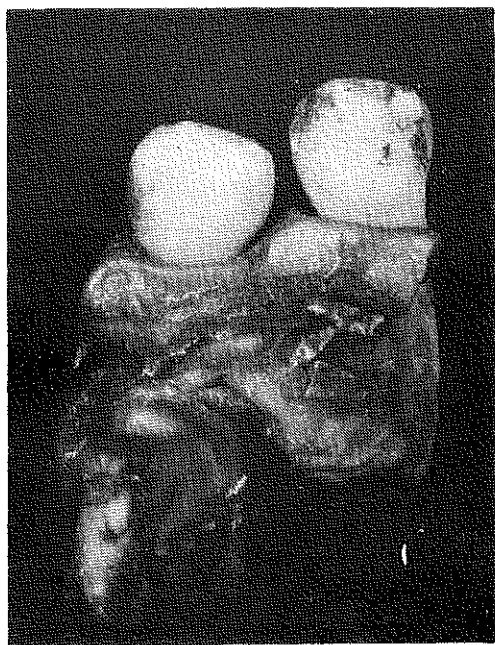


Figure 2. — The specimen consisted of tumor and the affected teeth.

## S U M M A R Y

A 29-year-old woman was treated for an odontogenic myxoma in the premolar area. Radiographs of the area revealed an unilocular radiolucency. A resection of the involved mandible was done. The patient has remained free of disease for six years.

The possible pathogenesis of the odontogenic myxoma is discussed.

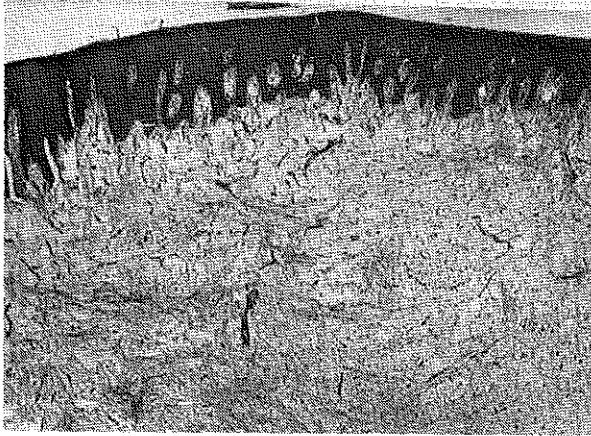


Figure 3. — Odontogenic myofibroma beneath gingival mucosa (H-E, x 40).

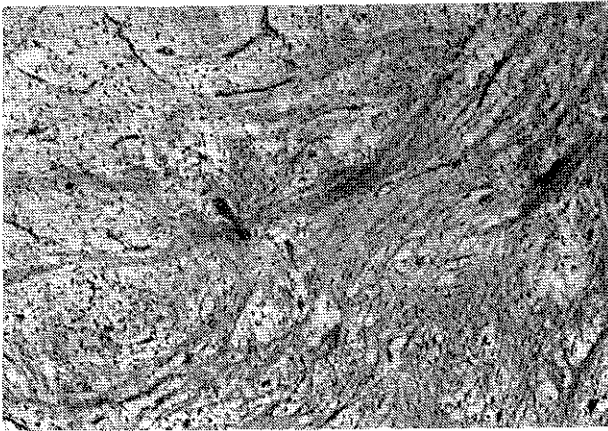


Figure 4. — A section stained with hematoxylin and eosin showing a small island of odontogenic epithelium within the myxofibromatous tumor (H-E, x63).

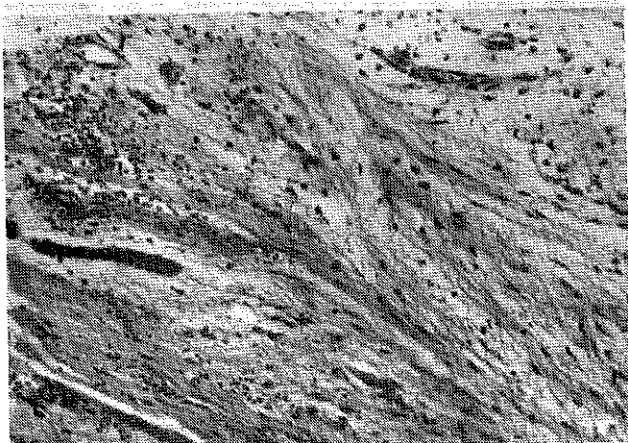


Figure 5. — Odontogenic myxofibroma (H-E, x100).

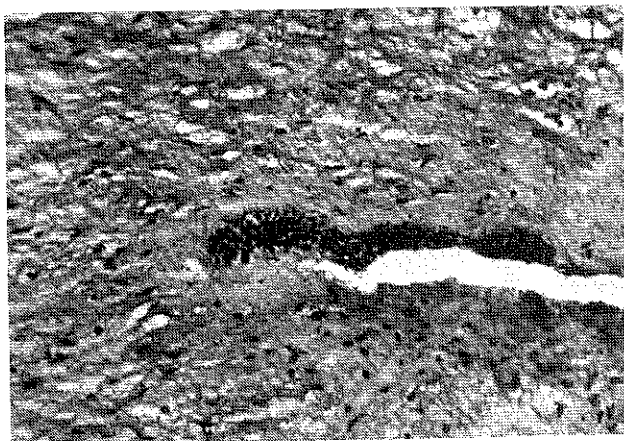


Figure 6. — Odontogenic myxofibroma (H-E, x 100).

## REFERENCES

- 1 — **Arora, B. K., and Hunter, H. A.** : Fibromyxoma of bone; report of case. *J. Oral Surg.* 28 : 125, 1970.
- 2 — **Barros, R. E., Dominguez, F. V., and Cabrini, R. L.** : Myxoma of the jaws. *Oral Surg.* 27 : 225, 1969.
- 3 — **Daniels, D. W.** : A case of pure myxoma of the lower jaw. *Lancet* 2 : 1747, 1908.
- 4 — **Ghosh, B. C., Huvos, A. G., Gerold, F. P., and Miller, T. R.** : Myxoma of the jaw bones. *Cancer.* 31 : 237, 1973.
- 5 — **Gorlin, R. J., Chaudhry, A. P., and Pindborg, J. J.** : Odontogenic tumors: classification, histopathology and clinical behaviour in man and domestic animals. *Cancer* 14 : 73, 1961.
- 6 — **Hammarström, L., Molin, C., and Clausen, F. P.** : Ameloblastic fibroma with hyalinisation and myxomatous changes. *Swed. Dent. J.* 64 : 633, 1971.
- 7 — **Harrison, J. D.** : Odontogenic myxoma; ultrastructural and histochemical studies. *J. Clin. Path.* 26 : 570, 1973.
- 8 — **Hodson, J. D., and Prout, R. E. S.** : Chemical and histochemical characterization of mucopolysaccharides in jaw myxoma. *J. Clin. Path.* 21 : 582, 1968.
- 9 — **Killey, H. C., and Kay, L. W.** : Fibromyxomata of the jaws. *Brit. J. Oral. Surg.* 2 : 124, 1965.
- 10 — **Large, N. D., Niebel, H. H., and Fredericks, W. H.** : Myxoma of the jaws. Report of two cases. *Oral Surg.* 13 : 1462, 1960.
- 11 — **Miglani, D. C., and Balltynne, A. J.** : Myxoma of the mandible, followed by resection and prosthetic repair. *Oral Surg.* 12 : 1032, 1959.
- 12 — **Radden, B. G., and Reade, P. C.** : Odontogenic myxoma of the jaws. *Oral Surg.* 15 : 355, 1962.
- 13 — **Schultz, L. W., and Vazirani, S. J.** : Central odontogenic fibromyxoma of the mandible. *Oral Surg.* 10 : 690, 1957.
- 14 — **Sedano, H. O., and Gorlin, R. J.** : Odontogenic myxoma; some histochemical consideration. *Arch. Oral. Biol.* 10 : 727, 1965.
- 15 — **Stafne, E. C., and Parkhill, E. M.** : Myxomatous tumor associated with an unerupted tooth; report of a case. *Amer. J. Orthodont. Oral Surg. Sect.* 33 : 597, 1947.
- 16 — **Stout, A. P.** : Myxoma, the tumor of primitive mesenchyme. *Ann. Surg.* 127 : 706, 1948.
- 17 — **Thoma, K. H., and Goldman, H. M.** : Central myxoma of the jaws. *Amer. J. Orthodont. Oral. Surg. Sec.* 33 : 532, 1947.

- 18 — **Young, W. G., and Ball, A. T.** : Central myxofibroma of the jaws; report of case. *J. Oral Surg.* 26 : 408, 1968.
- 19 — **Zimmerman, D. C., and Dahlin, D. C.** : Myxomatous tumors of the jaws. *Oral Surg.* 11 : 1069, 1958.