



ARAŞTIRMA / RESEARCH

Effects of Quercetin and Coenzyme Q10 on gentamicin-induced nephrotoxicity in rats

Quercetin ve Koenzim Q10'un sıçanlarda gentamisin kaynaklı nefrotoksisite üzerine etkileri

Neslihan Pınar¹, Yusuf Karataş², Gülfiliz Gönüşen³, Yusuf Kenan Dağlıoğlu⁴

¹Mustafa Kemal University Faculty of Medicine, Department of Pharmacology, Hatay, Turkey

²Çukurova University, Faculty of Medicine, Department of Pharmacology, ³Department of Pathology, ⁴Department of Medical Sciences Experimental Search and Application Center, Adana, Turkey

Cukurova Medical Journal 2020;45(1):251-256.

Abstract

Purpose: We investigated the effects of Quercetin and Coenzyme Q₁₀ antioxidant, on gentamicin-induced renal failure in rats.

Materials and Methods: The rats were given gentamicin (100 mg/kg/day, i.m., once a day), gentamicin (100 mg/kg/day, i.m. once a day) + Quercetin (15 mg/kg i.p. once a day) and gentamicin (100 mg/kg/day, i.m.) + Coenzyme Q₁₀ (8 mg/kg i.m. once a day).

Results: In control the BUN value was 26.8 ± 0.8 (mg/100 mL); whereas, it was 117.3 ± 15.4 in gentamicin group. Renal histopathologic examination confirmed acute tubular necrosis in this group. In rats treated with gentamicin + Quercetin and gentamicin + Coenzyme Q₁₀, a partial improvement in biochemical and histologic parameters was observed. BUN values were 117.3 ± 15.4, 44.0 ± 8.3, 47.8 ± 13.8 in gentamicin, gentamicin plus Quercetin and gentamicin plus Coenzyme Q₁₀ treated groups, respectively. Creatinine values were 4.3 ± 0.6, 0.8 ± 0.1, 1.5 ± 0.4 in gentamicin, gentamicin plus Quercetin and gentamicin plus Coenzyme Q₁₀ treated groups, respectively.

Conclusion: These results suggest that the administration of Quercetin and Coenzyme Q₁₀ may have a protective effect on gentamicin-induced nephrotoxicity in rats.

Keywords: Gentamicin, nephrotoxicity, Coenzyme Q₁₀, Quercetin

Öz

Amaç: Gentamisinle böbrek yetmezliği oluşturulan sıçanlarda Quercetin ve CoQ10 nun antioksidan etkilerini araştırmak amaçlanmıştır.

Gereç ve Yöntem: Sıçanlara gentamicin (100 mg/kg/day, i.m., günde 1 kez), gentamicin (100 mg/kg/day, i.m.) + Quercetin (15 mg/kg i.p. günde 1 kez) and gentamicin (100 mg/kg/day, i.m.) + CoQ10 (8 mg/kg i.m. günde 1 kez) uygulandı.

Bulgular: Kontrol grubundaki BUN değeri 26.8 ± 0.8 (mg/100 mL); buna karşın gentamisin grubunda 117.3 ± 15.4 bulunmuştur. Böbrek histopatolojik inceleme, bu grupta akut tübüler nekrozu doğruladı. Gentamicin + Quercetin ve gentamicin + CoQ10 uygulanan sıçanlarda biyokimyasal ve histolojik parametrelerde kısmi iyileşme gözlemlenmiştir. BUN değerleri gentamisin, gentamisin + Quercetin and gentamisin + CoQ10 gruplarında sırasıyla 117.3 ± 15.4, 44.0 ± 8.3, 47.8 ± 13.8 bulunmuştur. Gentamisin ile aralarında anlamlı farklılık bulunmuştur. Kreatinin değerleri gentamisin, gentamisin + Quercetin ve gentamisin + Koenzim Q10 ile tedavi edilen gruplarda sırasıyla 4.3 ± 0.6, 0.8 ± 0.1, 1.5 ± 0.4 idi.

Sonuç: Bu sonuçlar Quercetin ve CoQ10 uygulanmasının gentamisinle nefrotoksisite oluşturulan sıçanlarda koruyucu etkisi olduğunu göstermiştir.

Anahtar kelimeler: Gentamisin, nefrotoksisite, Coenzyme Q10, Quercetin

INTRODUCTION

Gentamicin, is a aminoglycoside antibiotic. Gentamicin accumulates in renal proximal tubules, brush border loses, cell desquamation and reduced

glomerular filtration rate, its stimulates tubular necrosis. Oxidative stress and inflammation has been reported to plays an important role in nephrotoxicity induced by gentamicin¹.

Yazışma Adresi/Address for Correspondence: Dr. Neslihan Pınar, Mustafa Kemal University Faculty of Medicine, Medical Pharmacology, Hatay, Turkey E-mail: drnesli01@gmail.com

Geliş tarihi/Received: 18.11.2019 Kabul tarihi/Accepted: 25.01.2020 Published online: 10.02.2020

It has been showed that gentamicin increases the production of free oxygen radicals and leads to a deficiency in antioxidant enzymes. In different pathological conditions including renal and cardiac diseases, reactive oxygen species (ROS) were claimed to be the death cause of some cells². Furthermore, it was stated that both free radical scavengers and some antioxidant agents such as rosuvastatin³ and irbesartan⁴ prevented gentamicin-induced renal failure.

Quercetin (3,5,7,3',4'-pentahydroxy flavone), is a natural polyphenolic flavonoid existing in vegetables, fruits, cereals, plants, tea, grapes and red wine. Flavonoids widely exist in edible plants². Quercetin have some distinct characteristics such as anticancer effects⁵, antihypertansif effects⁶, antiinflamatuvar effects⁷. Several mechanisms are attributed to the antioxidant effects of quercetin like free radical scavenging, chelating metal ions, protecting LDL from peroxidation and inhibiting key enzymes such as xanthine oxidase and NADPH oxidase⁸. An essential component of the mitochondrial respiratory chain, Coenzyme Q₁₀, shuttles electrons from complexes I and II and from electron transferring flavoprotein dehydrogenase (ETF-DH) to complex III⁹.

Coenzyme Q or ubiquinone is a redox- active lipoidal substance present in the hydrophobic middle region of the phospholipid bilayer of cellular membranes including those of the mitochondria. Three main functions are attributed to this lipid depending on distribution and concentration. Coenzyme Q₁₀ is highly efficient in preventing lipid, protein and DNA oxidation and it is continuously regenerated by intracellular reduction systems¹⁰.

Coenzyme Q₁₀ can be synthesized in tissue from farnesyl diphosphate and tyrosine and can be obtained from the consumption of meat, poultry, fish, vegetables and fruits; however, total absorption of coenzyme Q₁₀ from food is thought to be lower than 10%. Coenzyme Q₁₀ supplementation reduces oxidative stress and increases antioxidant enzyme activity in patients with coronary artery disease¹¹ and breast cancer¹².

The purpose of our study is to examine protective effects of quercetin (coenzyme Q₁₀ and polyphenolic flavonoid) on nephrotoxicity caused by gentamicin in rats.

MATERIALS AND METHODS

In our study, Gentamicin sulphate (İ.E.Ulagay Genta ampoule 80 mg), Quercetin dehydrate (purity degree: $\geq 98\%$ HPLC powder) (Sigma) and as well as Quercetin dissolved in DMSO were used. Solution was prepared by using SF to obtain 25% DMSO. 45 ml stock solution was prepared to obtain 3 mg of Quercetin in 1 ml. Furthermore, CoQ₁₀ (Sigma) dissolved in olive oil was used.

In our study, we used twenty-three male Wistar albino rats weighing 250 to 300 gram and taken from Center for Medical Research and Application. Rats were kept in metabolic cages in an ambient where room temperature is $24 \pm 2^\circ\text{C}$. 12 hours light-12 hours dark cycle was applied. Rats were fed by normal water and bait. The experimental protocols were confirmed by the Local Ethics Committee of the Çukurova University Medical Sciences Experimental Search and Application Center. The procedures in the study were in accordance with the NIH Guide for Care and Use of Animals.

The rats were divided into 4 groups and both water consumption and urine excretion of the animals were monitored for 7 days.

1. Control Group: 0.2 ml of physiological saline was daily intramuscular injection (i.m.) once administered to 5 rats for 7 days.

2. Gentamicin Group: 100 mg/ kg (i.m.) of gentamicin was daily once intramuscularly injected to 8 rats for 7 days.

3. Gentamicin and Quercetin Group: Intramuscular injection of once 100 mg/kg gentamicin and daily once 15 mg/kg i.p Quercetin was administered to 5 rats for 7 days.

4. Gentamicin and Coenzyme Q₁₀ Group: Daily once 100 mg/kg of i.m gentamicin and daily once 8 mg/kg of i.m CoQ₁₀ (by dissolving in olive oil) was administered to 5 rats for 7 days.

24 hours after the last injection, urine samples were collected. Intracardiac blood samples were taken following anesthesia by 40 mg/kg of ketamine and then the animals were decapitated. For histopathological examination, left kidney of the animals was removed by incision of center-line of abdomen. After being fixed in 10% formaldehyde, tissues were sent to pathology. In blood samples taken from experimental animals, BUN and serum creatinine were evaluated. Creatinine clearance was

measured by means of standard methods [urine creatinine (mg/dl) x volume of daily urine x 1.73 / serum creatinine (mg/dl) x 1440].

After removed kidneys were fixed in 10% formaldehyde solution, they were embedded in paraffin. Sections at thickness of 3-5 μ m were obtained and stained with hematoxylin-eosin. Following these procedures, samples were examined by light microscopy. Parameters such as tubular necrosis, degeneration, tubular atrophy, hypertrophy and peri-vascular inflammation were evaluated by light microscopy and the ranking was as follows: +: slight, ++: moderate, +++: severe changes according to the extent of damage observed.

Statistical analysis

Data values were expressed as mean \pm SEM. SPSS 21 software was used for statistical analysis. Kruskal-Wallis test was applied to determine the normal distribution or variance of groups that were not homogenic. The Mann-Whitney U test was applied for comparison within the group. Significance level was set up as $p < 0.05$.

RESULTS

A significant difference was found in terms of serum BUN levels between these groups [H (3, N=23)=14.9 $p=0.002$]. BUN levels significantly increased in Gentamicin group (U=0.00 $p=0.003$) and Gentamicin + Quercetin (U = 1.5 $p = 0.021$) compared to control group. When compared with Gentamicin group, this value significantly decreased in Gentamicin + Quercetin (U=2 $p=0.008$) and Gentamicin + CoQ₁₀ (U=3 $p=0.013$) groups. There was no significant difference between the groups of Gentamicin + Quercetin and Gentamicin + CoQ₁₀. A significant difference was found in terms of serum

creatinine levels (mg/dl) between the groups [H (3, N=23) = 18.3 $p=0.000$]. Creatinine levels significantly increased in Gentamicin group (U=0.00 $p=0.003$), Gentamicin + Quercetin group (U=0.00 $p=0.005$) and Gentamicin + CoQ₁₀ group (U=0.00 $p=0.005$) compared to control group.

A significant decrease was detected in Gentamicin + Quercetin group (U=1 $p=0.005$) and Gentamicin + Coenzyme Q₁₀ group (U=3 $p=0.013$) compared to Gentamicin group. There was no significant difference between the groups of Gentamicin+ Quercetin and Gentamicin + Coenzyme Q₁₀ (U=5.5 $p=0.14$). No significant difference was found between the creatinine levels of the groups [H (3, N=23) = 2.09 $p=0.55$] (Table 1).

Histopathological analysis

In histopathological examination, kidney sections were evaluated in terms of tubular necrosis, tubular degeneration, glomerular atrophy, glomerular hypertrophy, peri-vascular inflammation (Table 2). As expected, normal histopathological findings were observed in control group (Figure 1A). Severe tubular necrosis, tubular degeneration, glomerular atrophy and hypertrophy, and peri-vascular inflammation were obviously observed in gentamicin group (Figure 1B).

It was observed that tubular necrosis, tubular degeneration and glomerular hypertrophy were at slight levels while glomerular atrophy and peri-vascular inflammation were at moderate levels in Gentamicin + Quercetin group (Figure 1C). On the other hand, tubular necrosis, glomerular atrophy and peri-vascular inflammation were at slight levels, while tubular degeneration and glomerular hypertrophy were at moderate levels in Gentamicin + Coenzyme Q₁₀ group (Figure 1D).

Table 1. Comparison of levels of BUN, creatinine and creatinine clearance in blood samples of test groups

| | BUN (mg/dl) | Creatinine (mg/dl) | Creatinine Clearance | n |
|------------------------------|-------------------------------|------------------------------|----------------------|---|
| Control | 26.8 \pm 0.8 | 0.3 \pm 0.0 | 0.69 \pm 0.28 | 5 |
| Gentamicin | 117.3 \pm 15.4 ⁺ | 4.3 \pm 0.6 ⁺ | 0.25 \pm 0.06 | 8 |
| Gentamicin+Quercetin | 44.0 \pm 8.3 ⁺ * | 0.8 \pm 0.1 ⁺ * | 0.16 \pm 0.06 | 5 |
| Gentamicin+CoQ ₁₀ | 47.8 \pm 13.8* | 1.5 \pm 0.4 ⁺ * | 0.28 \pm 0.09 | 5 |

Data were expressed as mean \pm SE.

*Shows the significance level compared to Gentamicin group ($p < 0.05$).

⁺Shows the significance level compared to control group ($p < 0.05$).

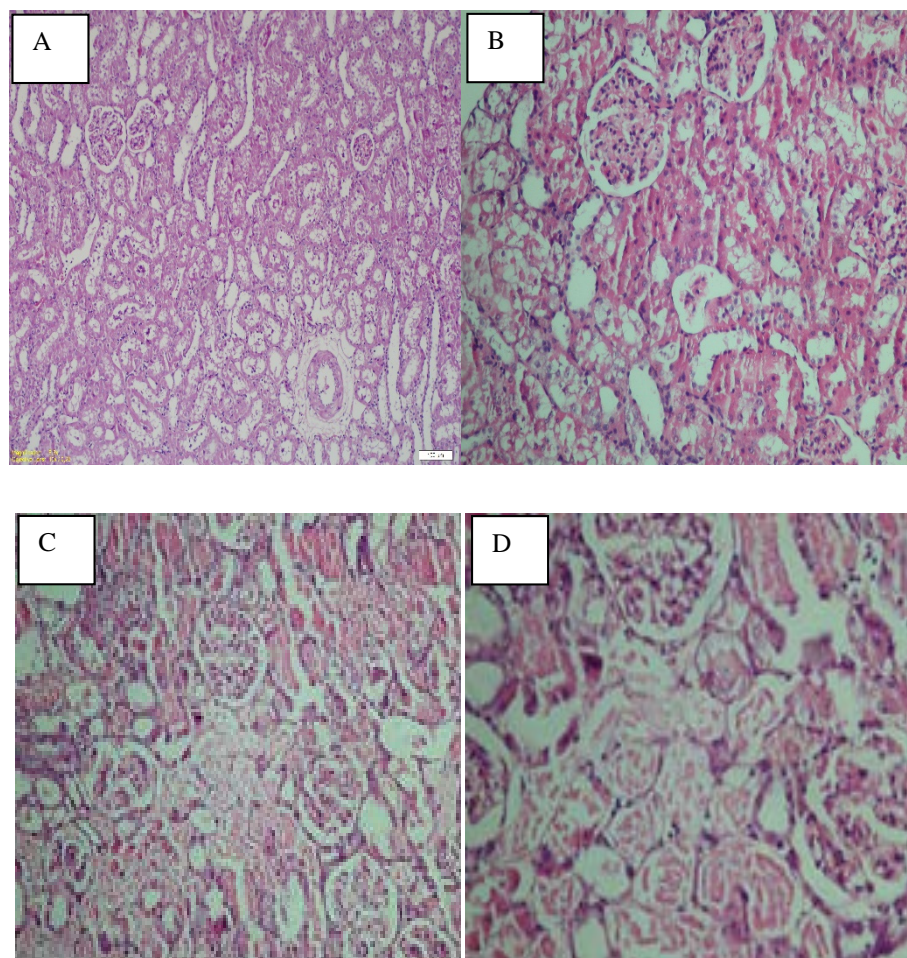


Figure 1. Histopathological kidney sections: (A) Control group, (B) Gentamicin, (C) Gentamicin + Quercetin group, (D) Gentamicin + CoQ10, (H & E \times 100).

Table 2. Results of histopathological analyses

| | Control | Gentamicin | Gentamicin + Quercetin | Gentamicin + CoQ ₁₀ |
|---------------------------|---------|------------|------------------------|--------------------------------|
| Tubular necrosis | - | +++ | + | + |
| Tubular degeneration | - | +++ | + | ++ |
| Glomerular atrophy | - | +++ | ++ | + |
| Glomerular hypertrophy | - | +++ | + | ++ |
| Perivascular inflammation | - | +++ | ++ | + |

Damage was evaluated qualitatively as +: slight, ++: moderate, +++: severe

Damage was evaluated qualitatively as +: slight, ++: moderate, +++: severe

DISCUSSION

Gentamicin-induced nephrotoxicity is caused by direct tubular necrosis in the proximal tubules. Gentamicin accumulated in the renal proximal tubules. The exact mechanism of gentamicin-induced nephrotoxicity is unknown. It has been reported that free radical

formations are the major mechanism of gentamicin-induced nephrotoxicity⁴. Severe complications of nephropathy, which gentamicin caused, restrict clinical usage of gentamicin. Aminoglycoside toxicity, including gentamicin, develops as a result of generation of destructive ROS. Gentamicin causes renal mitochondria to produce superoxide (O_2^-),

anion-peroxide (H₂O₂) and hydroxyl radicals (HO) which are strong mediators of tissue injury. Gentamicin toxicity develops as a result of production of destructive free oxygen radicals, and decreases the glomerular filtration rate by means of other mechanisms¹³. Several studies demonstrated that free O₂ radicals caused renal damage. Furthermore, a number of studies showed free radical scavengers had useful effects on renal damage^{14,15,16,17}.

It was found that polyphenols, which exist in large quantities in foods, not only removed free oxygen radicals but also had an important role in antioxidant system as a result of their ability to act as if enzyme modulator and chelating metal agent¹⁸. Quercetin is a natural polyphenolic flavonoid existing in vegetables, fruits, cereals, plants, tea, grapes and red wine². Several mechanisms are attributed to the antioxidant effects of quercetin like free radical scavenging, chelating metal ions, protecting LDL from peroxidation and inhibiting key enzymes such as xanthine oxidase and NADPH oxidase⁸.

Coenzyme Q₁₀ is known as an intracellular antioxidant protecting membrane phospholipids, mitochondrial membrane proteins and low-density lipoproteins from oxidative damage caused by free radicals¹¹.

Taking into account all these data, we examined the protective effects of antioxidant agents (Quercetin and Coenzyme Q₁₀) against nephrotoxicity caused by gentamicin in our study. In our study, it was observed that levels of serum BUN and creatinine increased, while level of creatinine clearance declined in gentamicin group. In renal histopathological examination, extensive degenerative changes were detected in tubules. These findings suggested development of acute kidney failure in gentamicin group. To prove renal damage, we examined levels of serum BUN and creatinine, calculated creatinine clearance by means of standard methods and as well as evaluated kidney histopathology.

100 mg/kg/day of Gentamicin was administered for 7 days to create nephrotoxicity. At the end of our study it was observed that gentamicin administered at the dosage of 100 mg/kg not only increased serum creatinine levels but also decreased GFR, which showed development of nephrotoxicity. In addition, glomerular dysfunction was accompanied by the increase of serum BUN levels. At the early stages of kidney diseases, serum creatinine levels are more

important than BUN levels because BUN levels appear after renal parenchymal damage.

As seen in previous studies, our study showed that gentamicin increased serum BUN and creatinine levels which are biochemical indicators of kidney function. These increased levels of serum BUN and creatinine indicated glomerular damage. On the other hand, serum BUN and creatinine levels significantly decreased when combination of Quercetin + gentamicin administered. However, no significant decrease was seen in terms of creatinine clearance. Significant decrease was also seen in serum BUN and creatinine levels when combination of Coenzyme Q₁₀ + gentamicin administered. We can see that Quercetin and Coenzyme Q₁₀ prevented renal toxicity caused by gentamicin.

Regarding that biochemical and histopathological values of kidney improved following the use of Quercetin and Coenzyme Q₁₀, we can assume that free O₂ radicals play a role in nephrotoxicity caused by gentamicin. In a previous study it was seen that CoQ₁₀ both prevented glomerular hyperfiltration and proteinuria and had beneficial effects on preventing increased oxidative stress in diabetic rats²⁰.

In our study we observed histopathological improvement in Gentamicin + Quercetin group compared to Gentamicin group. We also observed decreased tubular necrosis and tubular degeneration compared to Gentamicin + Quercetin group. Moreover we found a significant decrease in terms of tubular necrosis, glomerular atrophy, perivascular inflammation in Gentamicin + Coenzyme Q₁₀ group compared to Gentamicin group. There was no significant difference between the groups of Genta + Quercetin and Genta + Coenzyme Q₁₀. In conclusion, it was found that gentamicin led to acute kidney failure in rat kidney, and that administration of antioxidants such as Quercetin and Coenzyme Q₁₀, had protective effects against nephrotoxicity caused by gentamicin. Since they improved biochemical and histopathological toxic effects of Gentamicin on kidney, we can say that Quercetin and Coenzyme Q₁₀ are potent free radical scavengers.

Yazar Katkıları: Çalışma konsepti/Tasarımı: YK; Veri toplama: NP, YKD; Veri analizi ve yorumlama: GG; Yazı taslağı: NP; İçerğin eleştirel incelenmesi: NP; Son onay ve sorumluluk: NP, YK, GG, YKD; Teknik ve malzeme desteği: YKD; Süpervizyon: YK; Fon sağlama (mevcut ise): yok.

Etik Onay: Deney protokolleri Çukurova Üniversitesi Tıp Bilimleri Deneysel Araştırma ve Uygulama Merkezi Yerel Etik Kurulu tarafından onaylanmıştır.

Hakem Değerlendirmesi: Dış bağımsız.

Çıkar Çatışması: Yazarlar çıkar çatışması beyan etmemişlerdir.

Finansal Destek: Çalışma Çukurova Üniversitesi Araştırma Vakfı TF / 2006 / BAP 31 tarafından desteklenmiştir.

Author Contributions: Concept/Design : YK; Data acquisition: NP, YKD; Data analysis and interpretation: GG; Drafting manuscript: NP; Critical revision of manuscript: NP; Final approval and accountability: NP, YK, GG, YKD; Technical or material support: YKD; Supervision: YK; Securing funding (if available): n/a.

Ethical Approval: The experimental protocols were confirmed by the Local Ethics Committee of the Çukurova University Medical Sciences Experimental Search and Application Center.

Peer-review: Externally peer-reviewed.

Conflict of Interest: Authors declared no conflict of interest.

Financial Disclosure: The study is supported by Çukurova University Research Foundation TF/2006/BAP 31.

REFERENCES

- Vaishnu Devi D, Viswanathan P. Sulphated polysaccharide from sargassum myriocystum confers protection against gentamicin-induced nephrotoxicity in adult zebrafish. *Environ Toxicol Pharmacol*. 2019;72:103269.
- Abdel-Raheem IT, Abdel-Ghany AA, Mohamed GA. Protective effect of quercetin against gentamicin-induced nephrotoxicity in rats. *Biol Pharm Bull* 2009;32:61-7.
- Rasheed HA, Al-Kuraishy HM, Al-Gareeb AI. Rosuvastatin Attenuates acute nephrotoxicity through modulation of oxidative stress in sprague dawley rats. *J Pak Med Assoc*. 2019;69:S98-102.
- Al-Kuraishy HM, Al-Gareeb AI, Al-Naimi MS. Renoprotective effect of irbesartan in a rat model of gentamicin-induced nephrotoxicity: Role of oxidative stress. *J Lab Physicians*. 2019;11:200-5.
- Hoca M, Becer E, Kabadayı H, Yücecan S, Vatansever HS. The effect of resveratrol and quercetin on epithelial-mesenchymal transition in pancreatic cancer stem cell. *Nutr Cancer*. 2019;1-12.
- Marunaka Y, Marunaka R, Sun H, Yamamoto T, Kanamura N, Inui T et al. Actions of quercetin, a polyphenol, on blood pressure. *Molecules*. 2017;22. pii: E209.
- Piovezana Bossolani GD, Silva BT, Colombo Martins Perles JV, Lima MM, Vieira Frez FC, Garcia de Souza SR et al. Rheumatoid arthritis induces enteric neurodegeneration and jejunal inflammation, and quercetin promotes neuroprotective and anti-inflammatory actions. *Life Sci*. 2019;238:116956.
- Ertuğ P, Olguner AA, Ögülener N, Şingirik E. Protective effect of quercetin a polyphenolic compound, on mouse corpus cavernosum. *Fundam Clin Pharmacol*. 2010;24:223-32.
- Hirano M, Garone C, Quinzii CM. Co Q (10) deficiencies and MNGIE: Two treatable mitochondrial disorders. *Biochim Biophys Acta*. 2012;1820:625-31.
- Ognjanovic BI, Markovic SD, Pavlovic SZ, Zikic RV, Stajn AS, Saicic ZS. Combined effects of coenzyme Q₁₀ and Vitamin E in cadmium induced alterations of antioxidant defense system in the rat heart. *Environ Toxicol Pharmacol* 2006;22:219-24.
- Lee BJ, Huang YC, Chen SJ, Lin PT. Coenzyme Q₁₀ supplementation reduces oxidative stress and increase antioxidant enzyme activity in patients with coronary artery disease. *Nutrition*. 2012;28:250-5.
- Tafazoli A. Coenzyme Q10 in breast cancer care. *Future Oncol*. 2017;13:1035-41.
- Polat A, Parlakpınar H, Taşdemir S, Çolak C, Vardı N, Uçar M et al. Protective role of aminoguanidine on gentamicin-induced acute renal failure in rats. *Acta Histochem* 2006;108:365-71.
- Cuzzocrea S, Mazzon E, Dugo L, Serraino I, Di Paola R et al. A role for superoxide in gentamicin-mediated nephropathy in rats. *Eur J Pharmacol*. 2002;450:67-76.
- Pınar N, Özcan O, Dogan E, Cakirca G. Protective effect of dexpanthenol on gentamicin-induced nephrotoxicity in rats. *Ann Med Res*. 2019;26:1787-91.
- Altintas R, Parlakpınar H, Beytur A, Vardı N, Polat A, Sagir M et al. Protective effect of dexpanthenol on ischemia-reperfusion-induced renal injury in rats. *Kidney Blood Press Res*. 2012;36:220-30.
- Sen H, Deniz S, Yedekci AE, nangil G, Muftuoglu T, Haholu A et al. Effects of dexpanthenol and N-acetylcysteine pretreatment in rats before renal ischemia/reperfusion injury. *Ren Fail* 2014;36:1570-4.
- Rodrigo R, Bosco C. Oxidative stress and protective effects of polyphenols: Comparative studies in human and rodent kidney. A review. *Comp Biochem Physiol C Toxicol Pharmacol*. 2006;142:317-27.
- Lee BJ, Huang YC, Chen SJ, Lin PT. Effects of Coenzyme Q₁₀ supplementation on inflammatory markers (high-sensitivity C-reactive protein, interleukin-6, and homocysteine) in patients with coronary artery disease. *Nutrition*. 2012;28:767-72.
- Persson MF, Franzén S, Catrina SB, Dallner G, Hansell P, Brismar K et al. Coenzyme Q₁₀ prevents GDP-sensitive mitochondrial uncoupling, glomerular hyperfiltration and proteinuria in kidneys from db/db mice as a model of type 2 diabetes. *Diabetologia*. 2012;55:1535-43.