

## *Abbreviated Case Report*

### *Internal Resorption*

G. Ş. BAYIRLI, (\*)

A — 37 - year old man wanted, in 1962, the silicate filling of his maxillary left central incisor to be changed.

Clinical examination revealed that the maxillary left central incisor had a silicate filling on the mesial side. The pulp was found to be vital at the pulp tester. The tooth in question was normal in color. The patient stated that the silicate filling was inserted three years ago following a trauma.

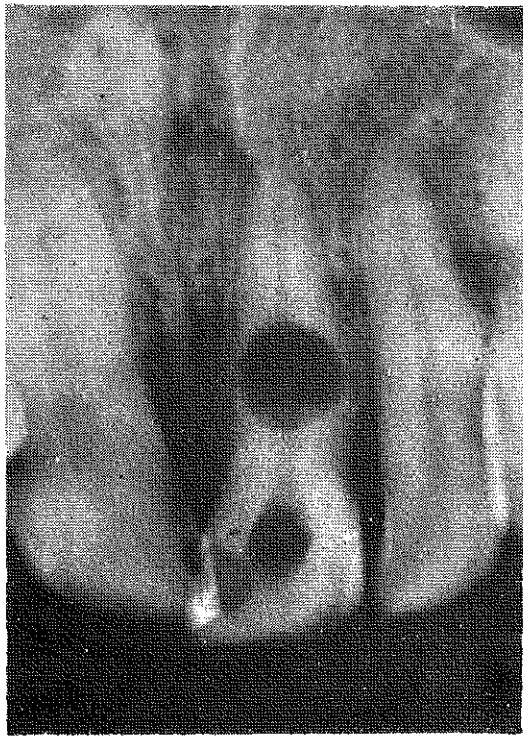
The patient's dentition was in good repair. The buccal mucosa and gingivae presented normal tone and coloring. No calculus was present on the frontal teeth. The depth of the periodontal pockets did not exceed more than 2 mm.

Radiographic examination revealed a round, central radiolucent area in the middle third of the root canal. The lesion was sharply defined and homogeneously radiolucent, without trabeculation or presence of denticles (Fig : 1). The case was diagnosed as an internal resorption. The root canal was found to be very narrow as compared with the maxillary right central incisor.

The initial treatment plan consisted of root canal treatment and filling. A coronal cavity was prepared to gain entrance into pulp chamber according to endodontic principles. The pulp tissue was

---

(\*) Assistant Professor, Department of Conservative Dentistry and Dental Pathology.

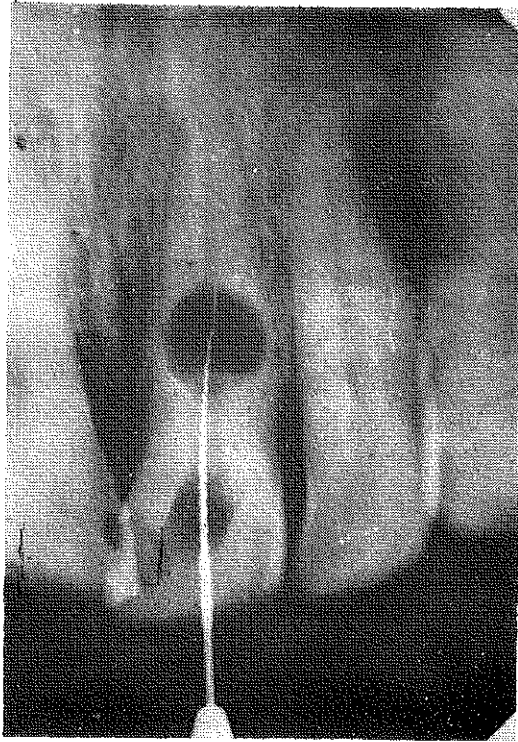


**Fig. 1.**  
**Internal resorption of maxillary left central incisor.**

removed from the pulp chamber. Despite the use of different types of root canal instruments, the canal orifice beyond the internal resorption was not to be found. The root canal instruments could reach but the terminal border of the internal resorption (Fig: 2).

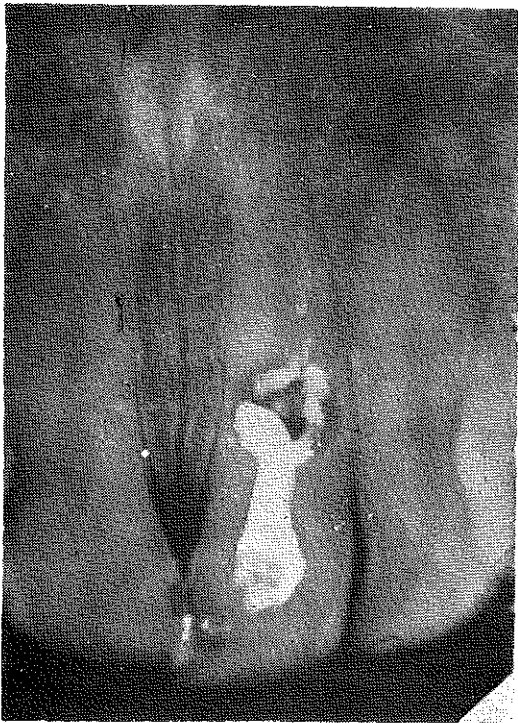
This eventually was the result of a misfortune or else the remainder of the canal portion was indeed narrow. An attempt was made to find out the remainder of the root canal in three successive visits. At last, the internal resorption was filled with iodoform paste (Fig : 3). The patient was invited for follow-up examinations with intervals of 6 months, but he did not appear again.

In 1972, the patient was finally found. The patient had no complaint at all. The tooth was brown in color. At once, an X - ray was taken. The iodoform paste which was filled in the internal resorption,



**Fig. 2.**

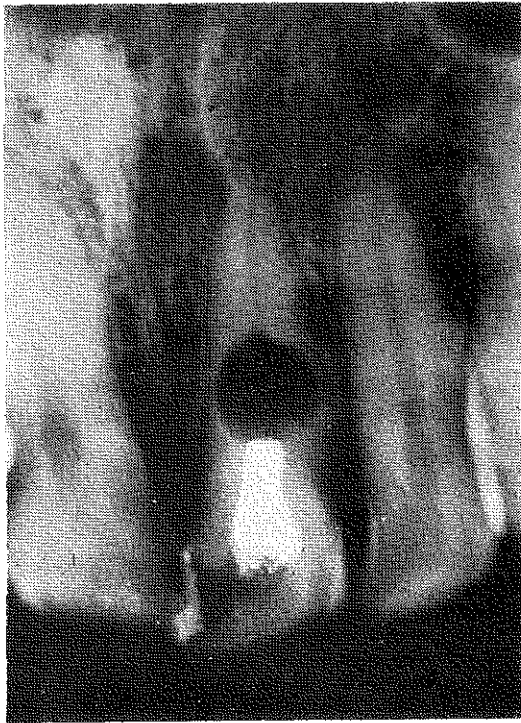
**The instrument in the root canal, Although a root canal is just apparent radiographically, it could not be found.**



**Fig. 3.**

**The internal resorption was filled with iodoform paste.**

as seen in fig : 3, had completely been resorbed (Fig : 4). The remaining root canal and periapical tissue were in normal aspect. The proposal of refilling the root canal was refused by the patient.



**Fig. 4.**  
The maxillary left central incisor after ten years.

## **DISCUSSION**

The etiology and pathogenesis of internal resorption are poorly understood. Acute trauma to the tooth and apical blood vessels, (6-8) inflammation (3, 5, 7), direct and indirect pulp capping (1, 2), pulpotomy (2) may be followed by internal resorption (4). The internal resorption concerning this particular case is due to trauma.

As stated above, the remainder of the root canal could not be reached, in the course of the initial treatment, since it was exceedingly narrow. In spite of this state of things, not a periapical lesion had occurred in the course of 10 years. The iodoform paste which had been filled into the internal resorption had completely been

resorbed (Fig : 4). A protracted slow course, usually extending over months or even years, is observed (4, 8). The lesion remained unchanged within 10 years. There does not appear to be a case parallel to this one in the dental literature.

### S U M M A R Y

This case report deals with an internal resorption clinically followed up for a period of 10 years. The iodoform paste filled within the internal resorption was completely resorbed. At the end of this 10 - year - period, no change was observed in the internal resorption, the periapical tissues were normal and the patient without any complaint.

### R E F E R E N C E S

- 1 — **Bennett, T. C. and Poleway, S. A.** : Internal Resorption, Post-Pulpotomy Type, Oral Surg. 17 : 228-234, 1964.
- 2 — **Cabrini, R. L., Maisto, O. A. and Manfredi, E. E.** : Internal Resorption of Dentin, Oral Surg. 10 : 90-96, 1957.
- 3 — **Giuliani, R. and Marmani, L.** : Several Cases of Internal Pulp Granuloma, Quintessence International, 0488/21-23, 1971 (November).
- 4 — **Gorlin, R. J. and Goldman, H. M.** : Thoma's Oral Pathology, Vol. One, ed. 6, St. Louis, 1970 The C. V. Mosby Company, PP : 208-211.
- 5 — **Kramer, I. R. H.** : The Relationship Between Pain and Changes in the Dental Pulp Following Insertion of Fillings, Brit. Dent. J. 96 : 9-13, 1954.
- 6 — **Ruston, M. A.** : Some Late Results of Injury to Teeth, Brit. Dent. J. 100 : 299-305, 1956.
- 7 — **Simpson, H. E.** : Internal Resorption, J. Canad. Dent. Ass. 30 : 355-359, 1964.
- 8 — **Stafne, E. C.** : Oral Roentgenographic Diagnosis, Ed. 3, Philadelphia, London-Toronto, 1969, W. B. Saunders Company, PP : 123-126.