

Periodontioma : A new entity

A. Sedat ÇÖLOĞLU (*)

On occasion we have discovered an odontogenic lesion for which there is no established name. The frequency of this tumor is difficult to determine with accuracy, but it appears that it is considerably less common than the other odontogenic tumors. It is likely, however, that in the past the lesion has been undescribed or misdiagnosed in the literature.

Case Report

The patient was an 18-year-old boy with a painless swelling of the right anterior maxilla. He had noticed some loose teeth, and an unerupted tooth was discovered during a routine dental examination. Recently, a bridge has been built by a general dental practitioner.

Radiographs revealed a radiolucent defect coronal to an unerupted and deformed maxillary lateral incisor. The border of the lesion appeared smooth but somewhat indistinct (Fig. 1).

The lesion was curettaged and the embedded tooth was removed under local anesthesia.

(*) Doç. Dr., Department of Pathology, Faculty of Dentistry, University of Istanbul, Çapa, Istanbul, Turkey.

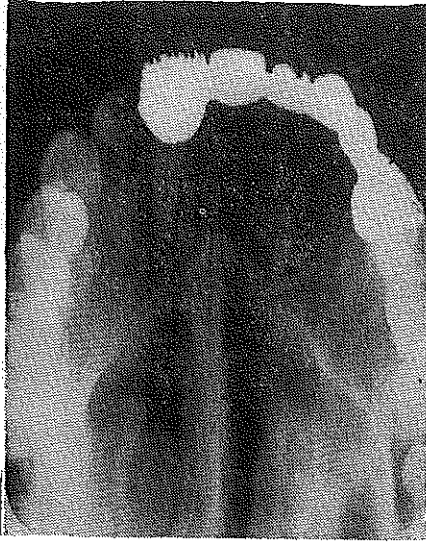


Fig. 1 — Radiograph showing a large radiolucent lesion below an unerupted maxillary lateral.

The tissue was light pink in color, rubbery consistency with calcifications in some sections.

Microscopically, the specimen consisted of cellular fibrous connective tissue containing islands of cementum, bone and odontogenic epithelium. There were connections between the bone and

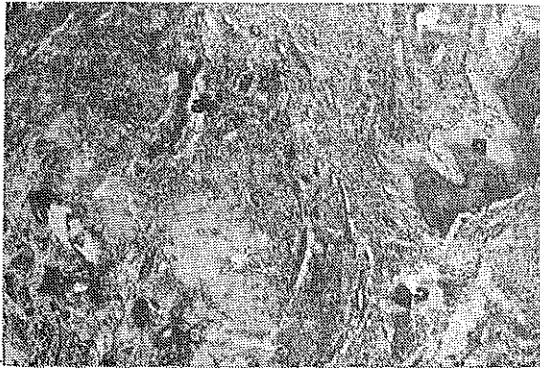

Fig. 7. — Photomicrograph showing islands of cementum/cementicles, bone and odontogenic epithelium in a mature connective tissue (Sharpey's fibers), Hematoxylin and eosin stain, x 100.

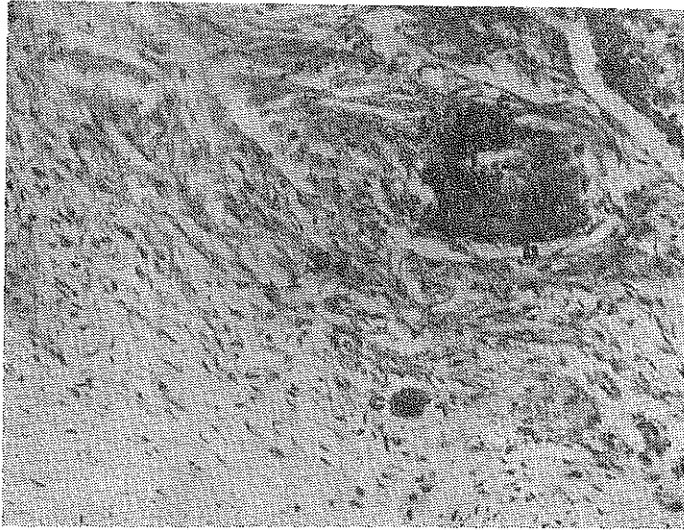


Fig. 3. — Photomicrograph showing islands of cementum/cementicles and bone surrounded by mature connective tissue. Hematoxylin and eosin stain, x 250.

the connective tissue, and the cementum and the connective tissue. In some areas, scattered cementicles were seen. The histopathologic diagnosis was **Periodontioma** (Figs. 2 and 3).

Discussion

Periodontioma is a new and previously undescribed lesion. It seems very likely that this lesion is of odontogenic origin. The lesion arises from the periodontal membrane and it contains all kind of the elements of periodontal membrane. The cellular fibrous connective tissue resembling the Sharpey's fibers is the main component of the tumor. Cementum and the cementicles, bone and odontogenic epithelium are the necessary components to diagnose the tumor as Periodontioma.

In reviewing the literature, we have found a few similar lesions described under various names. Two of them were found in the book of WHO named *Histological Typing of Odontogenic Tumours, Jaw Cysts and Allied Lesions*, written by Pindborg and Kramer in 1971 (1). Figures 33,44 and 45 contain the necessary elements found in Periodontioma. Also, the figures of peripheral odontogenic fibroma in

the book of Oral Pathology (p. 265) written by Shafer, Hine and Levy (2) are typical instances for Periodontoma.

The tumor is undoubtedly of odontogenic origin since it occurs in connection with periodontal membrane and an embedded tooth. The sections, particularly, showed rather large zones of an arranged connective tissue with intimate relation and apperent connection with the calcified bodies. Some of these bodies were basophilic and amorphous. They appeared identical with the calcifications noted in some lesions of the jaws which are commonly designated as cementicles. The osseous tissue was another component in the lesion. The epithelial component of the tumor was typical of that seen in the odontogenic tumors. They were narrow strands and cords of cells which resembled the dental lamina. The strands were usually one or two cells in thickness, although in some areas the epithelial cells formed small follicles.

The periodontoma appears to be a quite benign lesion, and curettage is probably sufficient for cure. We have observed and adequate healing in the site of operation, 9 months later following the curettage.

Ö Z E T

18 yaşındaki bir erkek çocukta üstçene sağ tarafında ve ön dişler kesiminde saptanan lezyonun daha önce tanımlanmamış bir odontogen tümör olduğu izlendi. Yapılan ışık mikroskopi incelemelerinde bu tümörün Periodontal membranı taklit ettiği gözlemlendi. Hüresel bir bağ dokusu içinde dağılan sement, kemik ve odontogen epitel adacıkları ile sement ve kemiği birbirine bağlayan bağ dokusu demetleri ilgi çekiciydi. Gömük bir dişle birlikte saptanan litik lezyon kürete edildikten 9 ay sonra yinelemedi. Bu nedenle ve histolojik görünümüyle selim bir tümör olduğu kanıtlandı. Tümörün **Periodontoma** olarak adlandırılması uygun bulundu.

S U M M A R Y

A case of a previously unnamed lesion is described and the name Periodontoma is applied. Light microscopy revealed a tumor mimicking the periodontal membrane with islands of cementum, bone and odontogenic epithelium scattered in a fibrous connective tissue. Complete curettage seems the best therapy.

REFERENCES

- 1 — **Pindborg, J. J. and Kramer, I R. H.** : Histological Typing of Odontogenic Tumours, Jaw Cysts, and Allied Lesions. International Histological Classification of Tuomurs No. 5. WHO Geneva, 1971.
- 2 — **Shafer, W. G., Hine, M. K. and Levy, M. L.** : The Textbook of Oral Pathology. Third edition. WB Saunders Co., Philadelphia, London, Toronto, 1974.