

## **Odontogenic Carcinosarcoma Of The Mandible : A Case Report**

**MELİH TAHSİNOĞLU, BEDRETTİN GÖRGÜN, A. SEDAT ÇÖLOĞLU  
and GÜLCİN ERSEVEN**

Malignant odontogenic tumours of the jaws are extremely rare neoplasms. Malignant ameloblastoma (Sugimura et al, 1969; Singleton, 1970), ameloblastic sarcoma (Tahsinoğlu and Özmerzi-fonlu, 1964; Leider et al, 1972; Howell and Burkes, 1977; Tahsinoğlu, 1980) and carcinoma arising in odontogenic cysts (Gardner, 1975; Enriques, 1980) are well known malignant neoplasms of the jaws of odontogenic origin. The purpose of this article is to present an unusual and heretofore undescribed malignant odontogenic tumour with both epithelial and mesenchymal components.

### **CASE REPORT**

A 30-year-old housewife first discovered a swelling of her left mandibular alveolus following the extraction of her second molar tooth in September, 1974.

Intraoral examination revealed a swelling of the left mandibular alveolus, predominantly on the buccal surface. The area of swelling

---

Dental Faculty of Istanbul University, and Faculty of Medicine  
of Istanbul University, Turkey

was hard and covered with an ulcerated mucosa. The posterior teeth were absent.

Radiographic analysis revealed a multilocular destructive lesion with destruction of the lower and upper margins of the left mandible and there was a large expansion in the bone (Fig. 1).

The remainder of the physical examination was unremarkable. Laboratory findings and chest radiographs were normal.

On December 1977, a left hemimandibulectomy with neck dissection was performed. The surgical specimen was submitted for microscopic examination, and a diagnosis of odontogenic carcinosarcoma was made.

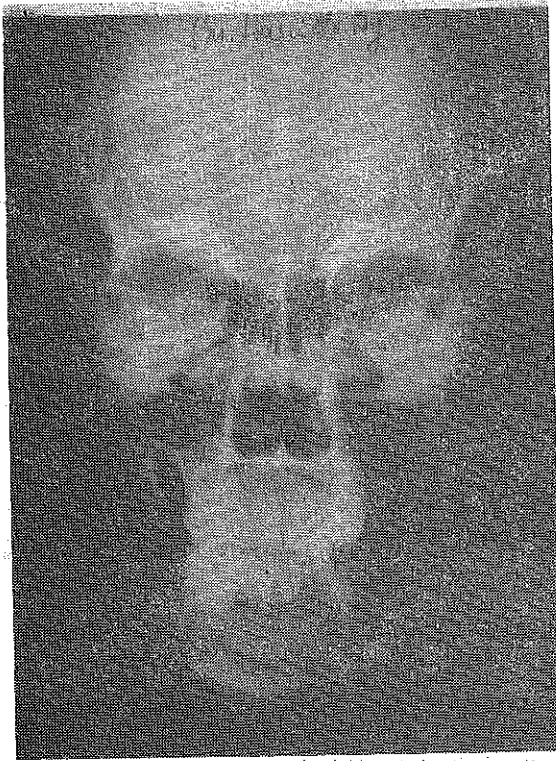
Grossly, the surgical specimen consisted of the left mandible, including the cervical lymph nodes. The tumour measured 5 x 4 x 4 cm. An exophytic bony mass with ulcerated oral mucosa was present on the buccal and lingual surface of the alveolar ridge. It extended from the left second premolar area to the ramus of the mandible. On cross section, the body of the lesion showed a hard and yellowish-white neoplasm. Radiologic examination of the surgical material revealed the details of the bony destruction (Fig. 2).

Microscopically, the tumour consisted of various types of elements. We have classified them in four groups :

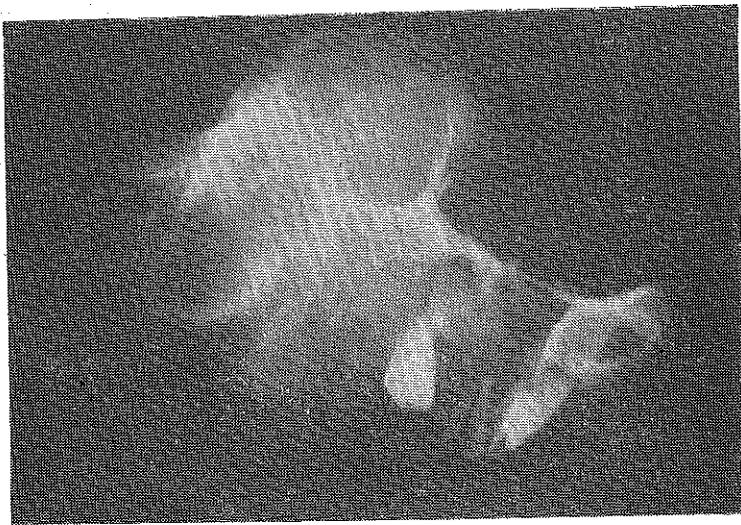
1. Plexiform ameloblastoma : The ameloblast-like cells are arranged in irregular masses, or, more frequently, as a network of strands of cells with scanty stellate reticulum (Fig. 3).
2. Malignant ameloblastoma : In some parts of the plexiform ameloblastoma, hyperchromatic and less differentiated ameloblastic cells were seen (Fig. 4).
3. Sarcoma : The mesenchymal component showed a great increase in cellularity and pleomorphism. There were numerous mitotic figures and giant cells (Figs 5 and 6).
4. Squamous cell carcinoma : In some areas of the ameloblastoma component, the columnar cells changed to atypical squamous cells with keratinization (Fig. 7).

We could not find any metastatic focus in the lymph nodes.

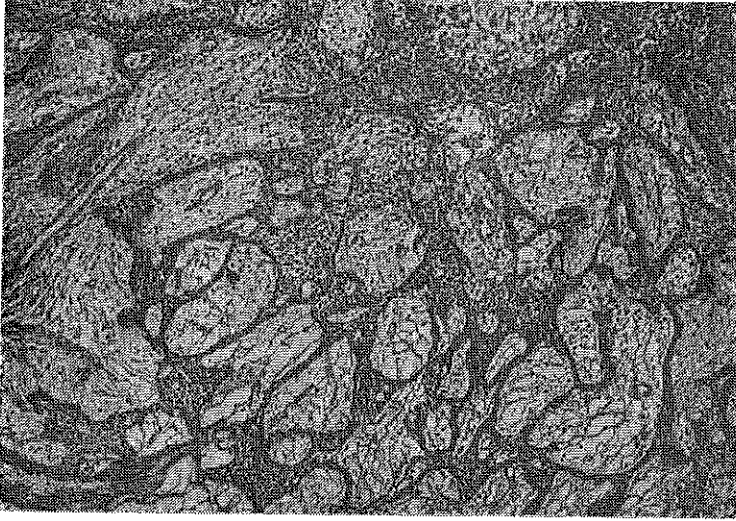
The patient had an uneventful postoperative course. However, she expired with local recurrences and lung metastasis six months after the operation.



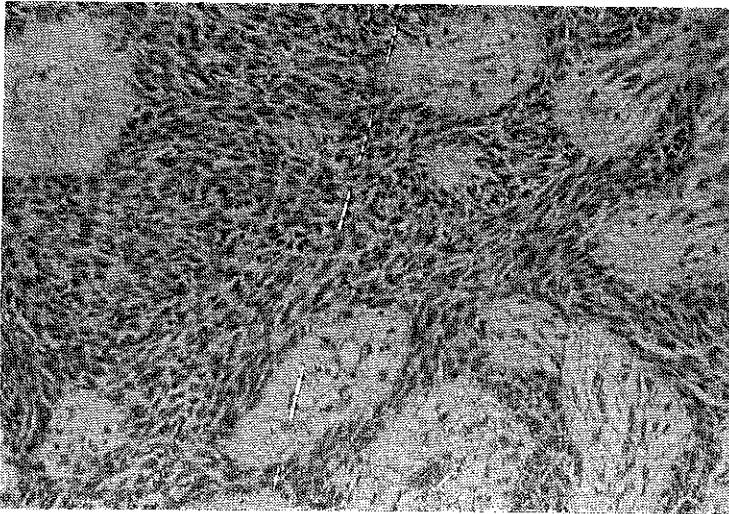
**FIG. 1.** Roentgenogram demonstrating large destruction and bony expansion.



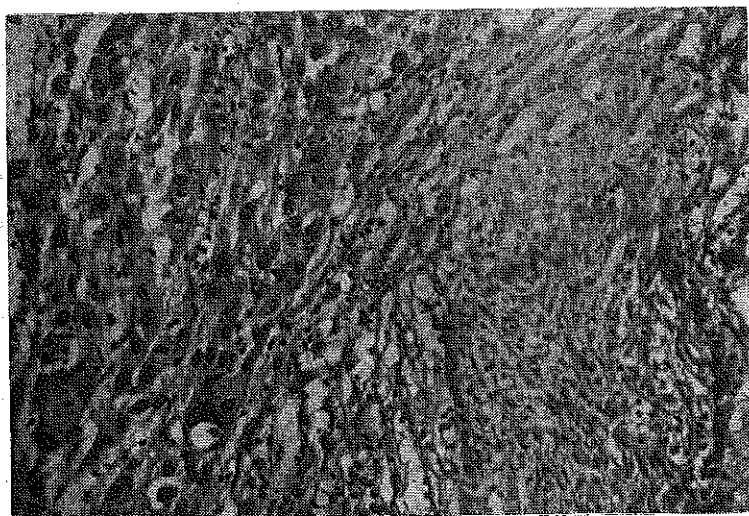
**FIG. 2.** Roentgenogram of the resected specimen showing gross expansion of the buccal and lingual cortex of the mandible.



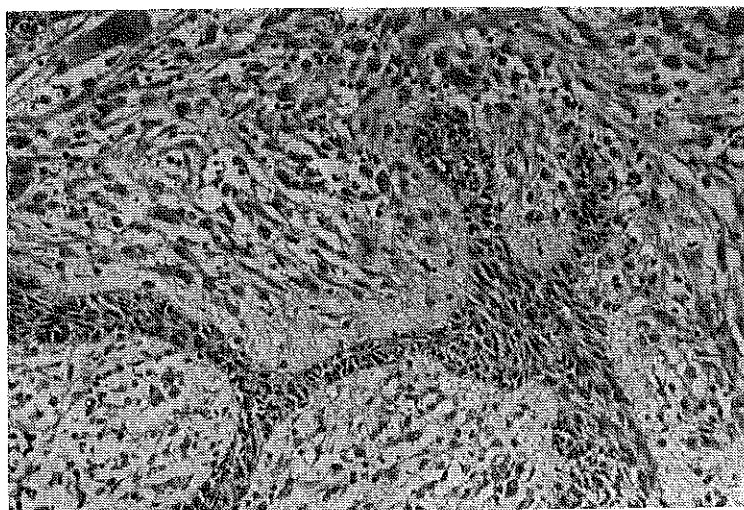
**FIG. 3. Plexiform ameloblastoma. This pattern is characterized by interdigitating cords of ameloblastic cells with scanty stellate reticulum, x 100.**



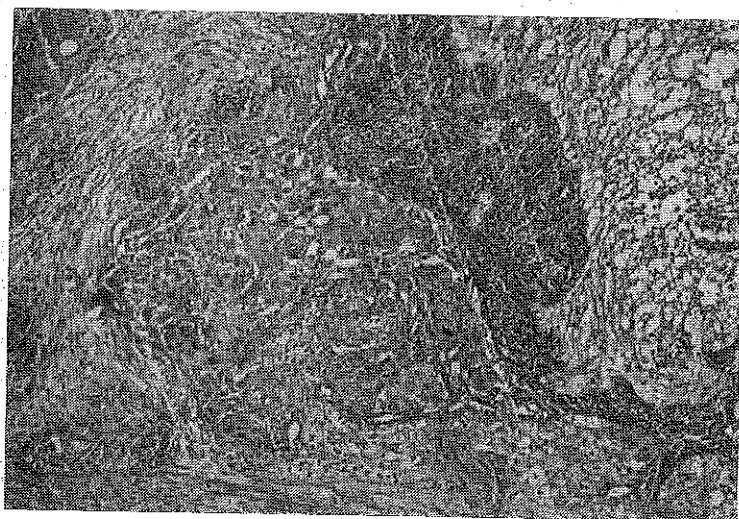
**FIG. 4. Malignant ameloblastoma. This component is characterized by less differentiated epithelial cells, x 150.**



**FIG. 5. Sarcoma component. Photomicrographs showing islands and strands of ameloblastic epithelium within a stroma exhibiting pleomorphism, hyperchromatism and giant cells. x 150.**



**FIG. 6. Photomicrograph demonstrating pleomorphism, mitotic figures and giant cells of the mesenchymal component. x 150.**



**FIG. 7.** Squamous cell carcinoma component. This component is characterized by atypical squamous cells developing in an island of ameloblastic epithelium. x 100.

### DISCUSSION

Carcinosarcoma is a rare malignant tumour containing elements which are identifiable as carcinoma and others as sarcoma (Willis, 1960). The carcinomatous elements are often like the usual forms of primary tissue (Willis, 1960). The sarcomatous components are most frequently fibrosarcoma, but areas of rhabdomyosarcoma, chondrosarcoma and osteogenic sarcoma may be seen (Willis, 1960). Many of the reported cases have been found in kidneys, breast and ovary, and metastases are usually sarcomatous, but in some cases carcinomatous metastases are also present (Willis, 1960).

The case we are presenting demonstrates the characteristic features of a carcinosarcoma. The lesion arose inside the mandibular alveolus and was attached to the soft tissues. It grew slowly over the course of two years. Correlation of the clinical behaviour and the microscopic characteristics is unrewarding in most of the malignant odontogenic tumours reported in the literature. This may be due to the low-grade malignancy of the elements of odontogenic

origin. Even in malignant ameloblastoma, one can see a tumour which may grow over a period of 30 years (Singleton, 1970). Otherwise, central fibrosarcoma grows slowly when compared with soft tissue fibrosarcoma (Jaffe, 1968).

Some instances of ameloblastic sarcoma appear to arise by malignant transformation of the ameloblastic fibroma (Leider et al, 1972). In our case, we have seen malignant transformation both in mesenchymal and epithelial components. Malignancies in epithelial component were observed as malignant ameloblastoma and squamous cell carcinoma. Squamous cell carcinoma may have arisen from squamous cell metaplasia in ameloblastoma.

#### S U M M A R Y

Odontogenic carcinosarcoma is an undescribed tumour of the jaws. A case involving the mandible of a 30-year-old woman is presented, and details of the lesion is discussed.

#### L I T E R A T Ü R

- Enriquez, R.E., Ciola, B. and Bahn, S.L. (1980), *Oral Surgery, Oral Medicine and Oral Pathology*, 49, 151.
- Gardner, A.F. (1975). *Journal of Canadian Dental Association*, 41, 161.
- Howell, R.M. and Burkes, E.J.Jr. (1977), *Oral Surgery, Oral Medicine and Oral Pathology*, 43, 391.
- Jaffe, H.L. (1968). *Tumors and Tumorous Conditions of the Bones and Joints*, 5th edition, Philadelphia : Lea and Febiger.
- Leider, A.S., Nelson, J.F. and Trodahl, J.N. (1972). *Oral Surgery, Oral Medicine and Oral Pathology*, 33, 559.
- Singleton, J.McL. (1970). *British Journal of Oral Surgery*, 8, 154.
- Sugimura, M., Yamauchi, T., Yashikawa, K., Takeda, N., Sakita, M. and Miyazaki, T. (1969). *Journal of Oral Surgery*, 27, 350.
- Tahsinoğlu, M. (1980) *Journal of Faculty of the Dentistry (Istanbul)*, 14, 87.
- Tahsinoğlu, M. and Özmerzifonlu, S. (1969) *Odonto-Stomatoloji Dergisi*, 3, 14.
- Willis, R.A. (1960). *Pathology of Tumours*, 3rd edition, London : Butterworths.