

Prosthetic Treatment of Patients After Maxillectomy With Spring Coils ()**

Atila USER (*)

The surgical treatment of malignant tumors will consist of resection of part of the maxilla. Sometimes even surrounding tissues may be removed. The extent of the resection depends on the localization and size of the tumor.

The defects may be grouped as follows :

1. Palatal defects (in the hard or in the hard and the soft palate)
2. Defects in the alveolar ridge.
3. Defects in the buccal surface of the maxilla (in the event of tumors in the maxillary sinus).
4. Actual maxillary defects (marginal resections, retaining the (unilateral or bilateral) nasal structures (subtotal resections, retaining the orbital floor) (total resection with removal of the orbital floor, too).

(*) Associate Professor, University of Izmir, Faculty of Dentistry, Department Prosthodontics.

(**) This article presented in the II nd International Week of Dentistry, Istanbul, 1976.

The Troubles of the Patient After Maxillary Resection :

The maxillary defects will often be of considerable nuisance to the patient.

This is due to the abnormal connection between the mouth and nasal cavity, or between the mouth and the maxillary sinus.

Speech becomes inarticulate and nasal.

Eating becomes difficult, because liquid nourishment will run into the nasal cavity and out through the nostrils.

If a greater part of the buccal surface of the maxilla is removed the cheek will lose its bony support, and this involves a disfiguration of the face. The extent of disfiguration depends on whether any shrinkage of the scar tissue occurs in the soft tissue during the healing period.

By total maxillary resections where the floor of the orbit is removed the eyeball will be displaced downwards, which will often result in double vision.

The purpose of the prosthodontic treatment is to remedy the inconvenience of the patient. It has many years been discussed whether, prior to maxillary resection, some kind of apparatus to be placed in the mouth of the patient immediately after operation should be constructed.

As far back as 1875, the Frenchman Claude MARTIN (6) gave an account of the construction of immediate resection dentures, which were placed in the cavity immediately after the resection, and which to the greatest possible extent corresponded in shape and size with the piece of jaw resected.

The purpose was above all to counteract shrinkage of the scars, thereby also counteracting disfiguration of the face. This kind of prosthesis fell into discredit, however, as it increased the risk of infection and irritated the surfaces of the wound, causing a delay of the healing process.

Today it is preferable to use a simple template :

This template may be shaped as an acrylic base that supports the tamponade, or in cases where the surfaces of the resection cavity are covered with skin graft, it may be provided with an obturator of thermoplastic impression material that keeps the graft

in position. If there are any teeth left in the healthy side of the jaw, the template is retained by means of clasps or a capsplint. With edentulous patients, the templated may be wired to the alveolar ridge in the healthy side and to the zygomatic arch in the side operated on.

As dentures made after maxillectomy are often insufficiently supported in the operated area, the result is poor stability, which again may influence the remaining teeth. As protection against the damaging lever action against the remaining teeth, these may be provided with crowns inlays that are soldered together. In cases where such bridge constructions are soldered together. In cases where such bridge constructions are not made it is advisable to use continuous clasps, thereby distributing the load on all the teeth. It would be advisable also to reduce the clinical crowns.

Particular Obturator Dentures can be constructed as rigid or stressbroken dentures.

Rigid Constructions :

By palatal resections and minor resections of the alveolar ridge the saddle has a bony support, and a rigid construction will therefore be indicated. In such cases the denture can be retained by means of precision attachments, telescopic crowns or cast clasps.

The Austrians TRAUNER and PLISCHKA (7) have in particular been advocates of the application of telescopic crowns in the construction of surgical prostheses. Telescopic crowns will give denture a good retention and afford an effective dental support. In order to stabilize the remaining teeth, the inner telescopic crowns may be connected, either by direct soldering or by insertion of bar connectors.

The telescopic crown has a retaining effect between of the surfaces of the outer and inner crown (1-2). The constant insertion and removal of the prosthesis will unfortunately reduce the friction, and it is often an advantage to incorporate some special device in the telescopic crowns in order to increase the retention.

Stress-broken Constructions :

By unilateral maxillary resections the denture will be badly supported on the operated side, and functional load in this region

will be badly supported on the operated side, and functional load in this region will therefore cause a lever action on the remaining teeth. To avoid this, stress-broken dentures are used.

Full Dentures :

When constructing full dentures, efforts must be made to provide sufficient retention for the denture, either by making use of the undercut of the cavity or by applying special intermaxillary stabilizers.

OBTURATORS :

Obturator have various functions. The principal function is to form a closure between mouth and nasal cavity, thereby enabling the patient to talk and eat. Besides, it must support the muscles of the cheek to counteract disfiguration of the face. Furthermore it must assist in retaining and stabilizing the denture by extending into the undercuts of the cavity.

The closed, hollow obturator that fills out the whole cavity is sometimes so big that, it has to be constructed in two parts. A more handy construction is the closed, hollow obturator that fills out only the lower part of the cavity and to utilize the existing undercuts, if any for the retention of the denture.

The open, bowl-shaped obturator has for many years been used at the Royal Dental College of Copenhagen (4). It is shaped as a «cuff» that extends 2 or 3 cm into the cavity. In 1944 the Finnish prosthodontist YLPPÖ recommended this type on the basis of phonetic research, and from a practical point of view, it has the advantage that is easier to construct and correct than the closed type. From a hygienic point of view, it is a drawback that secretion will collect in the bowl. This, however, may be remedied by frequent cleaning.

Construction of Obturators for Patients with Large Defects

Austrian prosthodontist WIRTH constructed a stabilizer which revolves on an axis placed transversically to the lower denture and kept in contact with upper denture by means of a rubber band.

Magnets have also been applied and placed opposite each other in the upper and lower dentures (3, 5).

The spring coil was previously the most applied intermaxillary stabilizer, the spring was fixed to the upper and the lower denture by means of two hinges working a sagittal plane. The hinges were placed buccal to the bicuspid. However, the springs had several drawbacks. BANGER pointed out that the elastic force is uncontrollable, and that it may cause a certain transformation of the remaining part of the jaw, which is weakened as a consequence of the resection. Besides the spring coils often irritate the mucosa of the cheeks. In such a case like this it is advisable to put a rubber tube over the spring coil. Radical cancer surgery often results in large defects which creates great difficulty to the prosthodontist. In case of large defect we have used spring coils for a better retention. Prior to the operation a template was made for the patient.

An impression of the denture base is taken in alginate material, and the impression tray is constructed by pouring cold cure acrylic material into the alginate impression.

Using clear acrylic material it helps to observe if there were any material into the alginate impression.

Using clear acrylic material it helps to observe if there were any anaemic spots (in the surrounding tissues caused by too much pressure).

After four weeks period final denture was made for the patient, this time we have used the obturator as an impression tray and took the final impression by using tissue conditioner (Co-Soft) or black guttae percha.

After bilateral resection, the prosthodontic treatment is extremely difficult, and only in close co-operation with the surgeon will the prosthodontist succeed in obtaining an acceptable result. In such cases, it is the task of the surgeon to create grafted osseous surfaces that are able to withstand the masticatory load transmitted through the denture (4).

Besides he can assist the prosthodontist in keeping the lower part of the soft palate, which after some months tends to shrink along the line of resection and become a stiff band which can be used to stabilize the denture.

Case No. 1 The picture shows such a denture which is supported and partly retained in the upper vault of the antrum. The most

dorsal part of the obturator is suspended from the remaining part of the soft palate. (Figure 1)

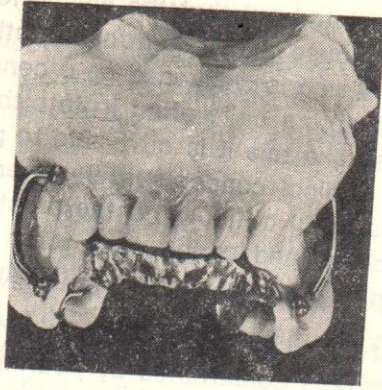

Fig : 1 — Dentures Contracted for Case 1

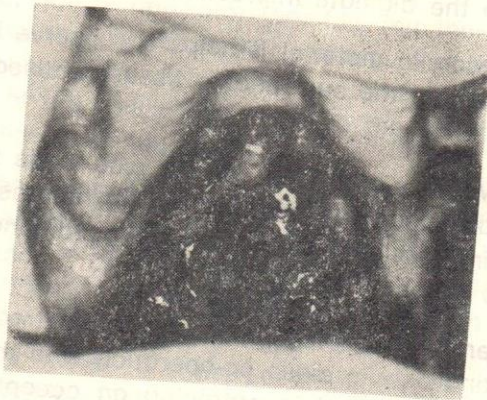


Fig : 2 — Resected areas

Spring coil has been used a stabilizer in this cas.

Case No : 2 Shows a case rights sided subtotal resection (Figure 2) is combined with resection of the hard as well as the soft palate. In this case full denture with a closed hollow obturator was made (Fig. 3). The frontal part of the obturator is shaped so that it rests on the remaining bone in the lateral cranial part of the cavity, while it is not in contact with the epithelium on the nasal septum.

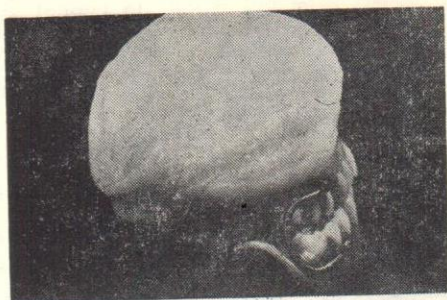

Fig : 3 — Dentures constructed for case 2

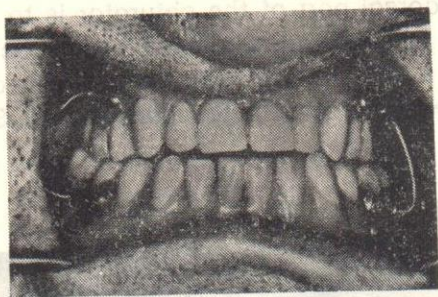


Fig : 4 — Inserted prosthesis in closed position

Case No : 3 A patient on whom a resection of soft palate and the dorsal part of hard palate have been performed (Fig 5).

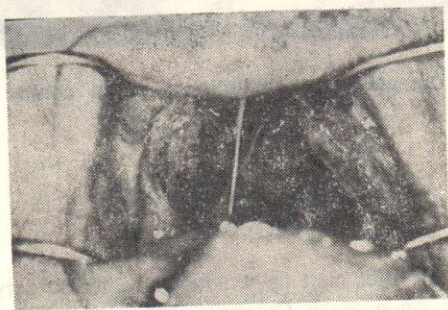


Fig : 5 — Resected soft palate and the dorsal part of the hard palate

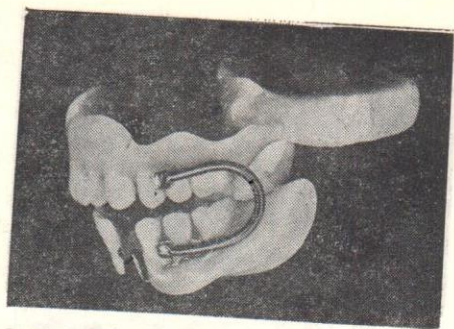


Fig : 6 — Dentures constructed for case 3

The task the dorsal part of the obturator is to replace the soft plate (Fig 6), and it is therefore shaped as a functional obturator, which means that it is in contact with the pharyngeal muscles when the patient swallows and articulated consonants. Spring coil used as stabilizer too.

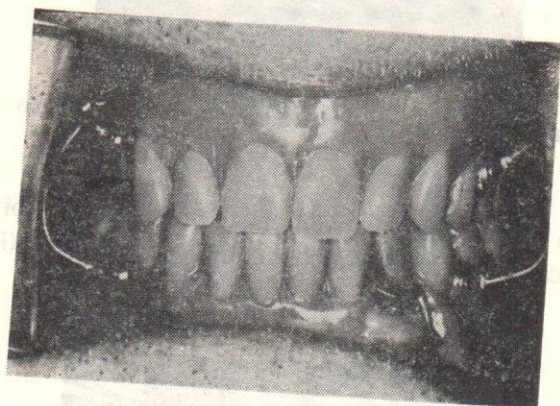


Fig : 7 — Completed rehabilitation seen in centric relation.

L I T E R A T Ü R

- 1 — Böttger, H. : Status after cleft lip, Palate and Jaw Surgery. pseudopognatism Quintessence Int, page 25-28 October, 1970.
- 2 — Böttger, H. : Prosthetic Treatment with a telescoping denture restoration after surgery. Quintessence Int, page 35-37 March, 1971.

- 3 — **Griffiths, N. A.** : Detachable obturaor with magnetic stabilizer for acquired palatal defects. Journal of district Columbia Dental Society Vol : 38 page 7-10 February, 1963.
- 4 — **Hildestad, P.** : Personnal Communication. Royal Dental College of Copenhagen.
- 5 — **Isabelle, M. T.** : Magnetism as an aid to a prosthetic problem. British Journal of Oral Surgery Vol : 2 Page : 44-46, 1965.
- 6 — **Martin-Claude** : De La Prothèse appliquée à la resection des maxillaires rhinoplastie sur appareil prothetique permanent, restauration de la face, lèvres, nez, langue voute et voile du palais, Paris 1889 G. Masson.
- 7 — **Trauner** : R Die Behandlung der malignen tumoren des oberkiefers Fortschr. d. Kiefer - u - Gesichtschirurgie, Bd. 3, 1957.

Çeşitli Ağız Üzeratli İstyonlarinda
 Kültürlerin Lactobacillus Acidophilus
 İhtiva eden İlaçlar

Dr. Mehmet ERMAN (*)

Son vaktlerde çeşitli ağız üze-
 ratli istyonlar tedavisi için
 kullanılmakta ve bu tedavilerde
 Lactobacillus Acidophilus
 kültürleri kullanılmaktadır.
 Bu kültürlerin ağız üzerat-
 leri üzeratli istyonlar için
 kullanılması ve bu istyon-
 ların tedavisi için kullanılması
 hakkında bu çalışmada detay-
 lı olarak bilgi verilmektedir.
 Ayrıca bu çalışmada Lactobacillus
 Acidophilus kültürlerinin ağız
 üzeratli istyonlar için kullanılması
 ve bu istyonların tedavisi için
 kullanılması hakkında detaylı
 bilgi verilmektedir.