

# *Is Ultrasound-Guided Steroid Injection With Pulsed Radiofrequency Lesioning of The Median Nerve Effective For Treatment of Carpal Tunnel Syndrome?*

*Serpil ŞEHİRLİOĞLU<sup>1\*</sup>, Onat AKYOL<sup>2</sup>,  
Alican AÇIKGÖZ<sup>3</sup>, Emine Nur TOZAN<sup>4</sup>*

## **ABSTRACT**

Carpal tunnel syndrome (CTS), a condition occurring in 0.1% of the general population, develops as the result of median nerve compression in the carpal tunnel of the wrist, usually because of tenosynovitis of the flexor tendons. We aimed to compare pulsed-mode radiofrequency lesioning of the median nerve to repetitive local steroid injections under ultrasound guidance (USG) for the treatment of CTS. Two groups were treated, each of 25 patients with a diagnosis of moderate CTS, referred to in this study as Group Steroid (Group S) and Group Radiofrequency (Group S+RF). Both groups received an injection of 1 ml 0.5% levobupivacaine mixed with 1 ml betamethasone into the carpal tunnel under USG. Four weeks later, Group S received a local steroid injection together with the same initial dose, and Group S+RF received pulsed-mode radiofrequency. All procedures were applied under the USG (Esaote® MyLab Five, Netherlands) by the same doctor (Dr Şehirlioglu) Boston Carpal Tunnel Questionnaire (BCTQ) and electromyographic evaluation were applied to all patients on their first visit and 12 weeks later. At the 12<sup>th</sup> week, changes of the electrophysiological parameters of the median nerve were recorded for both groups, including motor and sensorial conduction velocity, functional capacity and symptom

<sup>1\*</sup> Sağlık Bilimleri Üniversitesi, İstanbul EAH, Anesteziyoloji ve Yoğun Bakım Kliniği, Sorumlu Yazar /Corresponding author: serpilsahin@gmail.com, ORCID: <https://orcid.org/0000-0003-1471-1340>

<sup>2</sup> Sağlık Bilimleri Üniversitesi, İstanbul EAH, Anesteziyoloji ve Yoğun Bakım Kliniği, ORCID: <https://orcid.org/0000-0003-1316-7160>

<sup>3</sup> Sağlık Bilimleri Üniversitesi, İstanbul EAH, Anesteziyoloji ve Yoğun Bakım Kliniği, ORCID: <https://orcid.org/0000-0002-5488-3399>

<sup>4</sup> Sağlık Bilimleri Üniversitesi, İstanbul EAH, Anesteziyoloji ve Yoğun Bakım Kliniği, ORCID: <https://orcid.org/0000-0002-6480-5356>

Makale Geliş Tarihi / Received: 25.9.2019 – Makale Kabul Tarihi / Accepted: 5.10.2019

severity as determined by the Boston Carpal Tunnel Questionnaire (BCTQ). Our results indicate that although there was no significant difference at 12<sup>th</sup> week between the groups according to electromyographic (EMG) findings, the functional status and symptom severity as measured by the BCTQ were worse in Group S+RF than in Group S.

**Keywords:** *Carpal tunnel, pain, radiofrequency, median nerve, usg*

### **Karpal Tünel Sendromu Tedavisinde Median Sinirin Darbeli Radyofrekans Lezyonuyla Birlikte Ultrason Eşliğinde Steroid Enjeksiyonu Etkili Mi?**

#### **ÖZ**

Karpal tünel sendromu (KTS) toplumda %0,1 sıklıkla görülür. Genellikle flexor tendonların tenosinovitine bağlı medyan sinirin, el bileğinde karpal tünel içinde sıkışması sonucu meydana gelir. Bizim amacımız KTS tedavisinde USG eşliğinde tekrarlayan steroid enjeksiyonları ile pulse-mod radyofrekans tedavisini karşılaştırmaktı. Hastalar her grupta 25 hasta olmak üzere Grup S ve Grup S+RF olmak üzere iki gruba ayrıldı. Her iki gruba da 1 ml levobupivacain + ve 1 ml betametazon USG eşliğinde karpal tünel içine verildi. 4 hafta sonra Grup S'ye aynı doz tekrar edildi. Grup S+RF'ye ise yine USG eşliğinde ve aynı doktor tarafından pulse-mod radyofrekans uygulandı. Tüm hastalara ilk ziyaretlerinde ve 12 hafta sonra Boston Karpal Tünel Skalası (BKTS) ve elektromiyelografi yapıldı. 12. haftada her iki grupta da medyan sinirin elektrofizyolojik parametreleri, motor ve duyuşal ileti hızları, BKTS semptom şiddeti ve fonksiyonel durumu kayıt altına alındı. Bizim sonuçlarımız 12. haftada gruplar arasında elektromiyelografi bulguları açısından anlamlı bir fark olmadığını, fonksiyonel durum ve semptom şiddeti açısından BKTS'nin Grup S+RF'de Grup S'den daha kötü olduğunu göstermiştir.

**Anahtar Kelimeler:** *Karpal tünel, ağrı, radyofrekans, medyan sinir, usg*

## Introduction

Carpal tunnel syndrome (CTS) is a condition occurring in 0.1% of the general population that develops as the result of median nerve compression in the carpal tunnel. It is the most common entrapment neuropathy <sup>[1]</sup>. The entrapment occurs when there is compression of the median nerve, which passes through the carpal tunnel under the transverse carpal ligament together with the flexor tendons, due to increased pressure within the tunnel <sup>[2]</sup>. The most common etiologic cause is tenosynovitis of the flexor tendons due to hand overuse.<sup>[3]</sup>

Treatment options include operative carpal tunnel release, wrist splints and local corticosteroid injections <sup>[4]</sup>. Non-surgical treatment options have been offered to patients with mild to moderate symptoms of CTS. It is essential to identify the severity and neurophysiologic type of CTS in treatment planning and follow-up, since treatment failure and complications are encountered in 1% to 25% of all surgical carpal tunnel releases <sup>[5]</sup>.

Pulsed radiofrequency (PRF) neuromodulation is a non-neurodestructive treatment method used to manage chronic pain. Achieving analgesia without causing the destruction of neural tissue is the aim of pain treatment and functional improvement <sup>[6]</sup>. Haider *et al*<sup>[7]</sup> reported a case involving PRF lesioning in the median nerve after CTS surgery which achieved 70% pain relief .

Ultrasonography provides a simple, non-invasive visualization of peripheral nerves and is quite useful in the evaluation of entrapment neuropathies such as CTS <sup>[8,9]</sup>.

The purpose of this prospective randomised single-blinded study was to compare the effectiveness of repetitive local steroid injection to pulsed-mode radiofrequency lesioning plus local steroid injection under ultrasound guidance (USG) for the treatment of CTS. Our outcomes were as follows: electromyographic (EMG) imaging of the median nerve and Boston Carpal Tunnel Questionnaire (BCTQ) assessment of symptom severity and functional status.

The Boston Carpal Tunnel Questionnaire (BCTQ), also referred to as the Levine scale, Brigham and Womens' Carpal Tunnel Questionnaire and Carpal Tunnel Syndrome Instrument <sup>[10]</sup>, is a patient-based outcome measure that has been developed specifically for patients with CTS. It has two distinct scales, the Symptom Severity Scale (SSS) which has 11 questions and uses a five-point rating scale and the Functional Status Scale (FSS) containing 8 items which have to be rated for degree of difficulty on a five-point scale. Each scale generates a final score (sum of individual scores divided by number of items) which ranges from 1 to 5, with a higher score indicating greater disability (Fig 1 and Fig 2).

**Boston Carpal Tunnel Syndrome Questionnaire (BCTQ)**

**(-) Symptom severity scale (11 items)**

	1	2	3	4	5
1. How severe is the hand or wrist pain that you have at night?	Normal	Slight	Medium	Severe	Very serious
2. How often did hand or wrist pain wake you up during a typical night in the past two weeks?	Normal	Once	2 to 3 times	4 to 5 times	More than 5 times
3. Do you typically have pain in your hand or wrist during the daytime?	No pain	Slight	Medium	Severe	Very serious
4. How often do you have hand or wrist pain during daytime?	Normal	1-2 times / day	3-5 times / day	More than 5 times	Continued
5. How long on average does an episode of pain last during the daytime?	Normal	< 10minutes	10-60 Continued	> 60minutes	Continued
6. Do you have numbness (loss of sensation) in your hand?	Normal	Slight	Medium	Severe	Very serious
7. Do you have weakness in your hand or wrist?	Normal	Slight	Medium	Severe	Very serious
8. Do you have tingling sensations in your hand?	Normal	Slight	Medium	Severe	Very serious
9. How severe is numbness (loss of sensation) or tingling at night?	Normal	Slight	Medium	Severe	Very serious
10. How often did hand numbness or tingling wake you up during a typical night during the past two weeks?	Normal	Once	2 to 3 times	4 to 5 times	More than 5 times
11. Do you have difficulty with the grasping and use of small objects such as keys or pens?	Without difficulty	Little difficulty	Moderately difficulty	Very difficulty	Very difficult

**Figure 1: BCTQ Symptom severity scala**

(二) Functional status scale (8 items) :

	No difficulty	Little difficulty	Moderate difficulty	Intense difficulty	Cannot perform the activity at all due to hands and wrists symptoms
Writing	1	2	3	4	5
Buttoning of clothes	1	2	3	4	5
Holding a book while reading	1	2	3	4	5
Gripping of a telephone handle	1	2	3	4	5
Opening of jars	1	2	3	4	5
Household chores	1	2	3	4	5
Carrying of grocery basket	1	2	3	4	5
Bathing and dressing	1	2	3	4	5

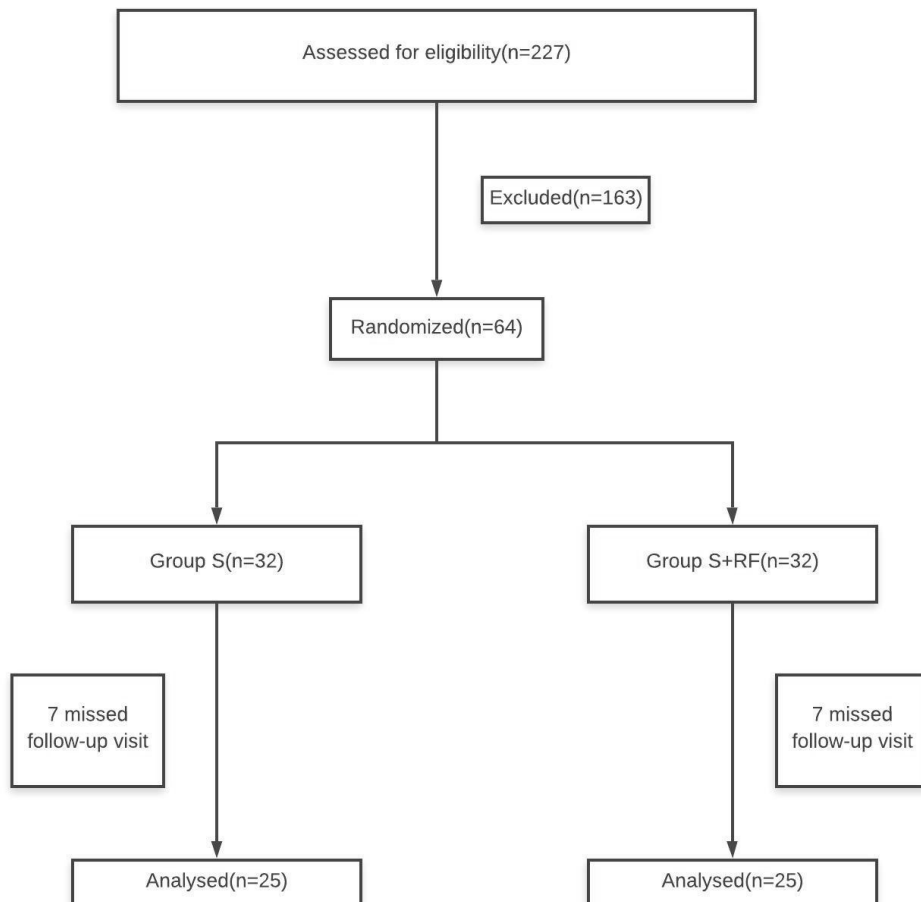
**Figure 2: BCTQ Functional status scala**

## Methods

The study comprised 50 ASA I and II patients admitted to the Pain Clinic of the Istanbul Training and Research Hospital between September 2010 and April 2011 and diagnosed with moderate CTS based on EMG studies.

Patient exclusion criteria for this study were as follows: ages under 18 and over 75; cervical disc hernia; pregnancy; systemic diseases such as diabetes mellitus, rheumatoid arthritis and hypothyroidism; polyneuropathy confirmed by EMG; conditions affecting shoulders, elbows, hands and wrists (impingement syndrome, epicondylitis, previous wrist break, Dupuytren's contracture or De Quervain's tenosynovitis); previous surgeries and local steroid injections due to CTS; and B12 and folate deficiency.

227 patients diagnosed with CTS were assessed for eligibility and 64 were enrolled in the study. The patients randomized in to two groups (n= 32). First group (group S) is treated with steroid injection and on the 4<sup>th</sup> week of their follow up another steroid injection is applied. Second group (group S+ RF) is also treated with steroid injection on the first visit and on 4<sup>th</sup> week of their follow up PRF is applied. (see fig 3 for the follow diagram of enrolment) Written informed consent was obtained from all participants. Power was calculated as 75%.



**Figure 3: Study flow diagram**

Group S received an injection of 1 ml 0.5% levobupivacaine (Chirocaine®) mixed with 1 ml betamethasone (Celestone®) into the carpal tunnel using a 22 G spinal needle. Two follow-up visits were planned after steroid injection, the first visit at the 4<sup>th</sup> week and the second at the 12<sup>th</sup> week.

On the second follow-up visit at the 12<sup>th</sup> week, changes were recorded in the electrophysiological parameters of the median nerve, including motor and sensorial conduction velocity, as well as in functional capacity and symptom severity as measured by the BCTQ. These findings were then compared in order to evaluate the effectiveness of the two treatment regimes. All the nerve conduction studies were performed by the same neurophysiologist,

and BCTQ assessments were made by the same anaesthesiologist; both practitioners were unaware of individuals' membership in the treatment groups. All injections were applied by the same pain specialist.

For the treatment of Group RF, a Neurotherm® NT500 Radiofrequency Generator and a 50 mm Neurotherm® RF cannula with a 5 mm active tip were used. The cannula was inserted into the carpal tunnel under USG, and an assistant attached the cautery plate to the patient. Sensory stimulation was performed at 50 Hz, 0.3 mA with 1 msec pulse intervals. With the patient's hand in the position causing paraesthesia, a thermocouple RF electrode was placed in the cannula and PRF was delivered for 120 sec at 45 V, 2 Hz and no higher than 42°C, with 20 msec wave width. Following the procedure, patients were observed at the Pain Unit for 30 minutes.

All injection procedures were performed using USG, with the patient seated and with his or her hand on a Mayo table with the wrist in dorsiflexion. The USG probe (Esaote® MyLab Five linear probe, 10–18 MHz, Netherlands) was placed on the volar aspect of the hand at the level of the first metacarpophalangeal joint in a transverse plane. The probe was tilted until the optimal view of the carpal tunnel was obtained. The needle was inserted by the USG operator at the level of the distal wrist crease at a 30 degree angle to the forearm and advanced into the carpal tunnel between the Musculus palmaris longus and Musculus flexor carpi radialis tendons.

The Epi Info 3.5.1 software was used for the analysis of the data. In addition to descriptive statistical methods such as calculating the average and standard deviation, the chi-square test and Fisher's exact test were used for comparison of qualitative variables; the Mann-Whitney U test was used for comparisons between groups where parametric test conditions were not met; the Wilcoxon signed-rank test was used for comparisons prior to and after the procedure within groups where parametric test conditions were not met; and Spearman's rank correlation coefficient was used to evaluate correlation where parametric test conditions were not met. A p value of <0.05 was considered significant.

## **Results**

There was no significant difference between groups with respect to median nerve motor velocity values before treatment and 12 weeks after application ( $p>0.05$ ) (Table 1). Nor was there a significant difference between groups with respect to median nerve sensorial velocity values before treatment and 12 weeks after application ( $p>0.05$ ) (Table 2).

At 12 weeks, the BCTQ symptom severity scale measurements in Group S+RF were significantly higher than those of Group S ( $p<0.05$ ). In both Group RF and Group S, the 12<sup>th</sup> week BCTQ symptom severity scale measurements were significantly lower than those taken prior to application ( $p<0.001$ ) (Table 3).

At the 12<sup>th</sup> week, the BCTQ functional status scale measurements in Group S+RF were significantly higher than those of Group S ( $p<0.01$ ). In both Group S+SRF and Group S, the 12<sup>th</sup> week BCTQ functional status scale measurements were significantly lower than the measurements taken prior to treatment ( $p<0.001$ ) (Table 4).

**Table 1: Comparison of median nerve motor velocity values before application and 12 weeks after application.**

Median nerve motor velocity	Group S+RF ( n:25)		Group S ( n:25)		P
	Mean(msec)	SD	Mean(msec)	SD	
Before application	54.18	4.27	53.53	5.94	.884
At 12 <sup>th</sup> week	58.50	4.95	58.42	6.01	.239
<b>P</b>	<b>.000***</b>		<b>.000***</b>		

**Table 2: Comparison of median nerve sensorial velocity values before application and 12 weeks after application**

Median nerve sensorial velocity	Group S+ RF (n:25)		Group S(n:25)		P
	Mean(msec)	SD	Mean(msec)	SD	
Before application	43.13	7.11	40.68	10.44	.485
At 12 <sup>th</sup> week	46.86	7.53	43.71	9.43	.419
<b>P</b>	<b>.001***</b>		<b>.024***</b>		



**Table 3: Comparison of BCTQ symptom severity scale measures before application and 12 weeks after application.**

BCTQ symptom severity	Group S+RF (n:25)		Group S(n:25)		p
	Mean	SD	Mean	SD	
Before application	32.72	8.78	32.36	7,11	,874
At 12 <sup>th</sup> week	<b>17.40</b>	<b>7.88</b>	13.44	3,42	<b>,026*</b>
<b>P</b>	<b>.000***</b>		<b>.000***</b>		

**Table 4: Comparison of BCTQ functional status scale measures before application and 12 weeks after application.**

BCTQ functional status	Group S+RF (n:25)		Group S(n:25)		p
	Mean	Sd	Mean	Sd	
Before application	22.32	7.02	20.32	5,51	,268
At 12 <sup>th</sup> week	<b>14.20</b>	<b>6.65</b>	10.20	2,52	<b>,007**</b>
<b>P</b>	<b>.000***</b>		<b>.000***</b>		

## Discussion

Our results indicate that, while there was no significant difference between the two treatment regimens according to EMG findings; the functional status and symptom severity scores of Group RF according to the BCTQ were significantly higher than those of Group S at 12<sup>th</sup> week.

While there is no golden diagnostic standard for CTS, current best practise would support the use of history, examination and EMG. There may also be a role for targeted questionnaires. In this study we used the BCTQ for assessment of symptom severity and functional status. The BCTQ is a patient-based measurement for CTS which has been shown to have significant effectivity. The psychometric properties of the BCTQ have been described in a systematic review <sup>[11]</sup>.

Berger *et al* <sup>[12]</sup>. showed in a prospective long-term follow-up study that a good response to the first local corticosteroid injection is predictive of long-term benefit and of a good response to multiple injections if those are necessary. By virtue of this result, we planned repetitive injections for those patients who reported moderate satisfaction after their first injection. Reports on the effectiveness of local steroid injections are inconsistent. Clinical and electrophysiological parameters generally improve over the short term after steroid injections. Lee *et al* <sup>[13]</sup> proposed the important conclusion that, although clinical improvements appear to be more evident than electrophysiological improvements, these progressively decrease as the severity of CTS increases. On the other hand, Cartwright *et al* <sup>[14]</sup>. reported in an ultrasound study that significant improvements in nerve cross-sectional area, mobility, and vascularity in the median nerve followed steroid injection for CTS.

The local injections of corticosteroids into the carpal tunnel is a commonly used and well-accepted treatment modality in carpal tunnel syndrome.

A Cochrane review investigating of local corticosteroid injection for CTS showed that steroid injection provides greater improvement in symptoms one month after injection than placebo injection, but that significant symptom relief from steroid injection beyond one month could not be demonstrated <sup>[15]</sup>). Another Cochrane review concluded that surgical treatment of CTS relieves symptoms significantly better than splinting <sup>[16]</sup>. However, there is not so much published prospective randomised study comparing pulsed-mode radiofrequency lesioning to local steroid injection or surgery.

This study concluded that treatment with steroids alone and combined steroid and PRF treatment of CTS are similar in terms of electrophysiological improvement rates at the end of 12 weeks. Both methods result in considerable improvement as compared to the patients' initial condition. However, an important aspect that should be considered in this research is the ineffectiveness of PRF lesioning of the median nerve 4 weeks after steroid injection compared to repetitive steroid injection. Nevertheless Haider *et al* <sup>[7]</sup> reported a case involving PRF lesioning in the median nerve after CTS surgery that achieved 70% pain relief.

Chen et al [17] compared ultrasound-guided PRF and knight wrist splint in patients with CTS and found that ultrasound-guided PRF leads to a more rapid and effective pain alleviation compared to knight wrist splint.

In recent years, PRF has been used to manage a wide spectrum of chronic pain modalities clinical models in treatment such as myofascial trigger points, phantom limb pain, occipital neuralgia, meralgia paraesthetica and radicular pain[18]. PRF produces fewer histopathological changes than conventional RF and has the advantage of a significant reduction in complications or side effects [19]. Corticosteroid injection therapy provides around one month painless period to the patients. After one or two months, patients require another injection. In this study, we aimed that PRF could increase the duration of painless activity of the corticosteroid therapy. We have applied PRF to the median nerve for 4 weeks after steroid injection because local steroid injection is one of the treatment options for pain relief for moderate CTS; on the other hand, pain relief effect of PRF on median nerve has been shown only by just a few studies.

The present study does have some possible limitations, including the relatively small number of subjects, the lack of follow-up beyond 12 weeks, and the absence of double-blind design. A potential bias could have ensued due to the fact that the physician who performed the injections was not blinded.

This clinical study concludes that PRF lesioning of the median nerve with local steroid injection is not a superior pain relief method when compared to repetitive steroid injection in moderate CTS. However, both methods do provide effective pain relief and functional improvement when compared with the condition prior to treatment.

## **REFERENCES**

- [1] Stevens JC, Sun S, Beard CM, O'Fallon WM, Kurland LT. Carpal tunnel syndrome in Rochester Minnesota, 1961 to 1980. *Neurology*. 1988; 38: 134–138.
- [2] Gerritsen AA, de Krom MC, Struijs MA, Scolten RJ, de Vet HC, Bouter LM. Conservative treatment options for carpal tunnel syndrome: a systematic review of randomised controlled trials. *J Neurol*. 2002; 249: 272–280.
- [3] Graham B. Nonsurgical treatment of carpal tunnel syndrome. *J Hand Surg Am*. 2009; 34: 531–534.
- [4] Dammers JW, Veering MM, Vermeulen M. Injection with methylprednisolone proximal to the carpal tunnel: randomised double blind trial. *BMJ*. 1999; 319: 884–886.
- [5] Verdugo RJ, Salinas RA, Castillo JL, Cea JG. Surgical versus non-surgical treatment for carpal tunnel syndrome. *Cochrane Database Syst Rev*. 2008. p. CD001552.
- [6] Munglani R. The longer term effect of pulsed radiofrequency for neuropathic pain. *Pain*. 1999; 80: 437–439.
- [7] Haider N, Mekasha D, Chiravuri S, Wasserman R. Pulsed radiofrequency of the median nerve under ultrasound guidance. *Pain Physician*. 2007; 10: 765–770.
- [8] Marhofer P, Chan VW. Ultrasound-guided regional anesthesia: current concepts and future trends. *Anaesth Analg*. 2007; 104: 1265–1269.
- [9] Wong SM, Griffith JF, Hui AC, Lo SK, Fu M, Wong KS. Carpal tunnel syndrome: diagnostic usefulness of sonography. *Radiology*. 2004; 232: 93–99.
- [10] Levine DW, Simmons BP, Koris MJ, Daltroy LH, Hohl GG, Fossel AH, Katz JN. A self-administered questionnaire for the assessment of severity of symptoms and functional status in carpal tunnel syndrome. *Journal of Bone & Joint Surgery - American Volume*. 1993;75:1585–1592.

[11] Leite JC, Jerosch-Herold C, Song F. A systematic review of the psychometric properties of the Boston Carpal Tunnel Questionnaire. *BMC Musculoskelet Disord.* 2006 Oct 20; 7: 78.

[12] Berger M, Vermeulen M, Koelman JH, van Schaik IN, Roos YB. The long-term follow-up of treatment with corticosteroid injections in patients with carpal tunnel syndrome. When are multiple injections indicated? *J Hand Surg Eur.* 2012 Vol. 6

[13] Lee JH, An JH, Lee SH, Hwang EY. Effectiveness of steroid injection in treating patients with moderate and severe degree of carpal tunnel syndrome measured by clinical and electrodiagnostic assessment. *Clin J Pain.* 2009 Feb; 25(2):111–115.

[14] Cartwright MS, Hobson-Webb LD, Boon AJ, Alter KE, Hunt CH, Flores VH, Werner RA, Shook SJ, Thomas TD, Primack SJ, Walker F. Evidence-based guideline: neuromuscular ultrasound for the diagnosis of carpal tunnel syndrome. *Muscle Nerve.* 2012 Aug; 46(2): 287–293.

[15] Marshall S, Tardif G, Ashworth N. Local corticosteroid injection for carpal tunnel syndrome. *Cochrane Database Syst Rev.* 2009; (2): CD001554.

[16] O'Connor D, Marshall S, Massy-Westropp N. Non-surgical treatment (other than steroid injection) for carpal tunnel syndrome. *Cochrane Database Syst Rev.* 2003; 1: CD003219.

[17] Chen LC, Ho CW, Sun CH, Lee JT, Li TY, Shih FM, Wu YT. Ultrasound-Guided Pulsed Radiofrequency for Carpal Tunnel Syndrome: A Single-Blinded Randomized Controlled Study. *PLoS One.* 2015 Jun 12 ;10(6):e0129918

[18] Malik K, Benzon HT. Pulsed radiofrequency: a critical review of its efficacy. *Anaesth Intensive Care.* 2007 Dec; 35(6): 863–873.

[19] Byrd S, Mackey S. Pulsed radiofrequency for chronic pain. *Curr Pain Headache Rep.* 2008 January; 12(1): 37–41.