

Ameloblastic Sarcoma : A Case Report

Melih TAHSİNOĞLU (*) — Kaya ÇİLİNGİROĞLU (**) — Gülçin ERSEVEN (***)
and A. Sedat ÇÖLOĞLU (***)

The ameloblastic sarcoma is a rare tumour composed of ameloblastoma-like tissue intermixed with sarcomatous mesenchymal tissue. There are 26 reported instances of ameloblastic sarcoma in the literature. The first case was reported in 1887 by Heath, as a «Spindle cell sarcoma». Eve (1907), Krompecher (1917), Papadimitriou (1928), Kegel (1932), Hauenstein (1937), Emminger (1945), Hertz (1952), Villa (1955), Pindborg (1960), Cina et al (1961), Cataldo et al (1963), Mori et al (1972), Leiden et al (1972), Forman and Garrett (1972), Hatzifotiadis and Economou (1973), and Goldstein et al (1976) added their cases to the literature.

Nevertheless, the incidence of the progression of an ameloblastic fibroma to an ameloblastic sarcoma is much less (Cina et al, 1962; Cataldo et al, 1963; Mori et al, 1972; Goldstein et al, 1976).

CASE REPORT

The patient, a woman aged 22 years, attended her dentist for a swelling in the molar area of the left mandible, in June 1971. An attempt to remove the swelling was made but three months later

(*) Department of Morphology, Faculty of Medicine-Edirne, University of Istanbul.

(**) Department of Surgery, Faculty of Medicine-Istanbul, University of Istanbul.

(***) Department of Pathology, Faculty of Dentistry, University of Istanbul.

following the operation, a new swelling developed in the same area. Radiological examination revealed an osteolytic lesion in the ramus of the left mandible, with a track to the lower border (Fig. 1).

A biopsy was performed under local anaesthesia. In the sections, a tumour composed of odontogenic epithelium and highly cellular mesenchymal tissue was seen. A diagnosis of Ameloblastic fibroma was made (Fig. 2). The tumour was curetted under general anaesthesia, in September, 1971.

Nine months after surgery, the patient came back with a painful swelling in the same area. Intraoral examination revealed a solid, ulcerated and bleeding tumour in the molar area. A new radiograph was taken, and the persistence of the radiolucent lesion was seen. Loss of the cortical bone and irregular resorption was seen in the affected part of the ramus (Fig. 3). An incisional biopsy was performed from the intraoral part of the tumour.

The new biopsy sections showed a mesenchymal tissue with malignancy and numerous mitoses. Near the one pole of the tissue there was a single island of odontogenic epithelial cells. A diagnosis of a meloblastic sarcoma was made (Fig. 4 and 5). The patient accepted neither hemimandibulectomy nor chemotherapy, and unfortunately has not been seen again.

DISCUSSION

The ameloblastic fibroma and the ameloblastic sarcoma are tumours found almost exclusively in the mandible (Leider et al, 1972, Mori et al, 1972). The average age of the patients with ameloblastic sarcoma was 30.8 years, and the age range was 3.5 (Mori et al, 1972) to 78 (Cataldo et al, 1963). Thirteen of the twenty-six cases were seen in female patients. Clinically, pain is the most outstanding finding (Leider et al, 1972). Radiologically, it was described as discrete bone destruction with expansion of the affected cortex. The recurrence rate was low in the patients treated with radical resections. Chemotherapy was used only by Goldstein et al (1976).

It is easy to recognise the ameloblastic fibroma consequent to the presence of abundant odontogenic epithelium dispersed within a mesenchymal tissue (Trodahl, 1972). There may be some difficulties in the diagnosis of ameloblastic sarcoma due to the diminishing of the odontogenic epithelium. On the other hand, it is necessary

to make a differential diagnosis by seeking for odontogenic epithelium in serial sections, when a fibrosarcoma is seen in the jaws.

Odontogenic origin of the ameloblastic sarcoma is first described by Eve in 1907, the author used the name of «Sarcomatous mixed odontomes». The histogenesis of the progression of an ameloblastic fibroma to an ameloblastic sarcoma resembles the sarcomatous changes in Cystosarcoma phyllodes of the breast. The epithelial components in the ameloblastic fibroma and cystosarcoma phyllodes tend to disappear when sarcomatous progression occurs. In the present case, we only found a small island of odontogenic epithelium after sarcomatous progression, while the epithelial components were abundant in the stage of ameloblastic fibroma.

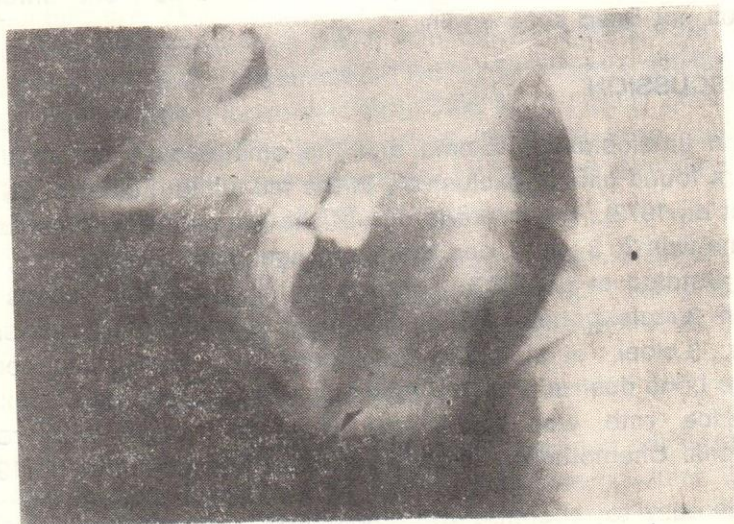

Figure 1. Radiograph of the left side of the mandible demonstrates radiolucent area behind the first molar. Note the track leading to the lower border (arrow).

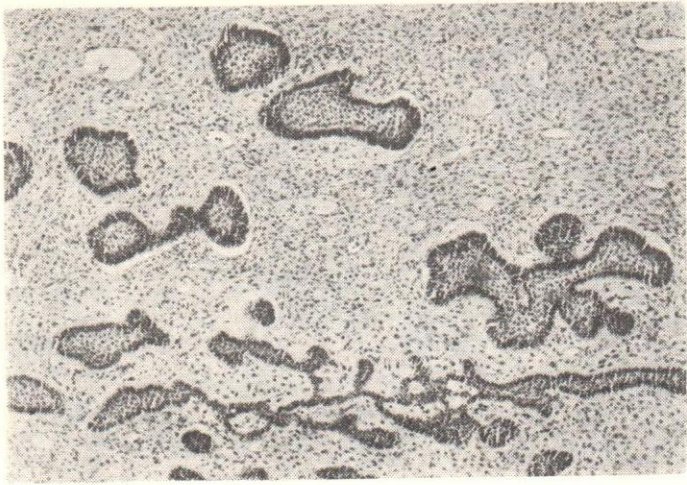


Figure 2. Photomicrograph demonstrates islands and cords of odontogenic epithelium scattered in highly cellular mesenchymal tissue closely resembling dental papilla of the developing tooth bud, H-E, X 63. (d.190/72).

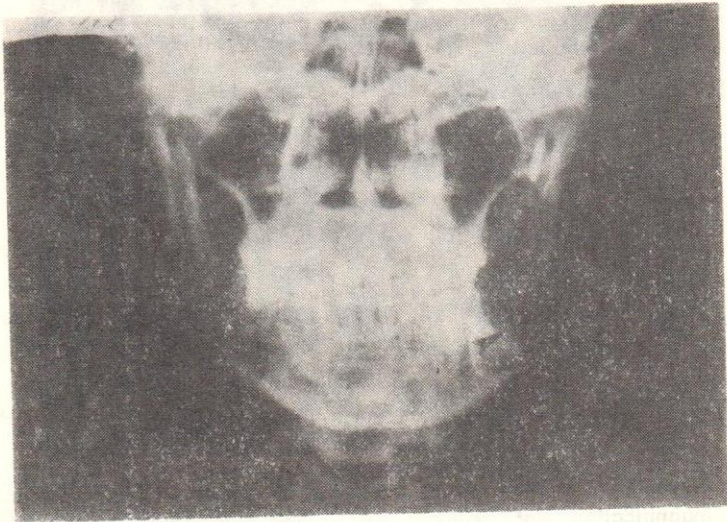


Figure 3. Radiograph taken after recurrence shows irregular osteolytic lesion and loss of the bone in both sides of the ramus (arrows).

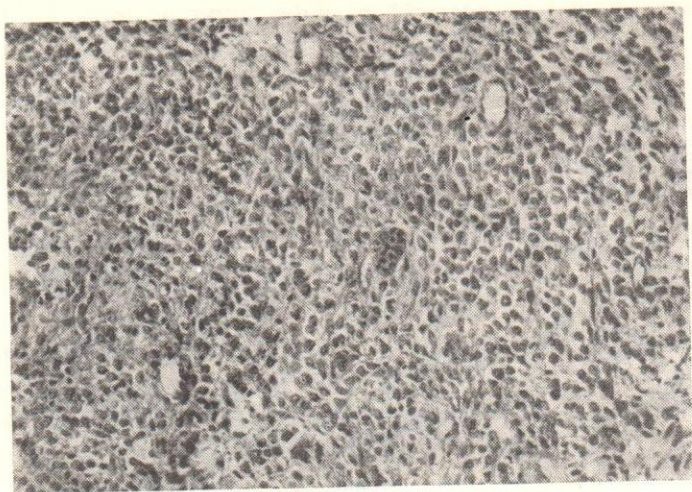


Figure 4. Photomicrograph of a section of the tumour demonstrates island of odontogenic epithelium within the sarcomatous mesenchymal tissue, H—E, X 200. (d.564/72).

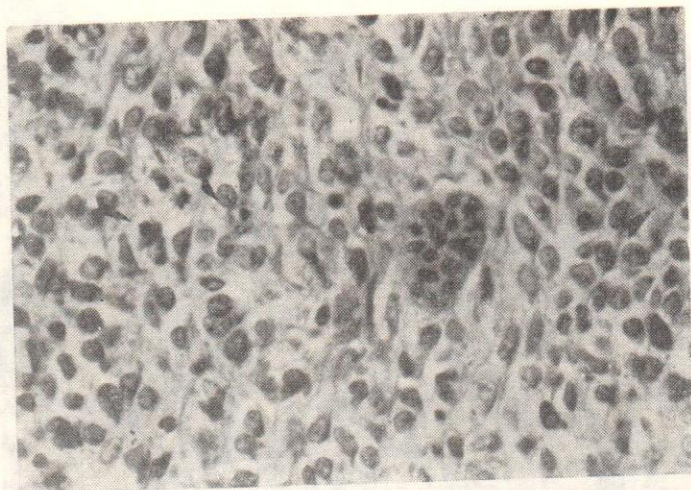


Figure 5. Histological section of same tumour as shown in Fig. 4 under higher magnification. Note mitoses (arrow) and pleomorphic bizarre malignant mesenchymal tissue adjacent to odontogenic epithelium, H—E, X 500. (d.564/72).

Ö Z E T

Ameloblastik fibroma, epitelyal ve mezenkimal komponentlerin bir arada bulunduğu selim bir odontogen tümördür. Ameloblastik fibroma'nın ameloblastik sarkoma'ya dönüşmesi oldukça nadir bulgulardandır. Bu tür olguları da içeren ameloblastik sarkoma ile ilgili literatür gözden geçirilerek lezyonun klinik, radyolojik ve patolojik özellikleri üzerinde duruldu. Ayrıca, literatüre yeni bir olgu ekledik. Hastamız 22 yaşında kadındı. İlk yakınması şişlik ve bir dişhekimi burada saptadığı fistülü tedavi etmişti. Yine altçene sol molar dişler alanında ortaya çıkan ikinci bir şişlik üzerine yapılan radyolojik incelemede, sınırları düzenli bir litik lezyon saptandı. Yapılan biopsi tanısının ameloblastik fibroma olması üzerine lezyon kürete edildi. Ancak, 9 ay sonra gelen hastada şişliğin eskisinden daha büyük bir biçimde geliştiği izlendi. Ağızıcı kitlesinden yapılan biopsinin tanısı ameloblastik sarkoma idi. Teklif edilen radikal cerrahi ya da kemoterapi kabul edilince hasta evine gönderildi. Burada bildirdiğimiz olgu, sarkoma dönüşen bir ameloblastik fibroma'yı göstermesi nedeniyle oldukça ilginçtir.

S U M M A R Y

A very rare tumour in a young female demonstrates the progression of an ameloblastic fibroma to an ameloblastic sarcoma due to the recurrences.

R E F E R E N C E S

- Cataldo, E., Nathanson, N. and Shklar, G. (1963). *Oral Surgery, Oral Medicine, Oral Pathology*, 16, 953.
- Cina, M.T., Dahlin, D.C. and Gores, R.S. (1962). *Oral Surgery, Oral Medicine, Oral Pathology*, 15, 696.
- Emminger, E. (1946). *Österreichische Zeitschrift für Stomatologie*, 43, 356.
- Eve, F. (1907). *British Medical Journal*, 1, 1525.
- Forman, G. and Garrett, J. (1972) *Journal of Oral Surgery*, 30, 50.
- Goldstein, J.A., Parker, F.B. and Hugh, S.F. (1976). *Cancer*, 37, 1673.
- Hatzifotitiadis, D. and Economou, A. (1973). *Journal of Maxillofacial Surgery*, 1, 62.
- Hauenstein, K. (1937). *Deutsche Zahn Mund und Kieferheilkunde*, 4, 387.
- Heath, C. (1887). *British Medical Journal*, 1, 777.
- Hertz, J. (1952). *Acta Medica Scandinavica*, (Supp. 266) 142, 529.
- Kegel, R.F.G. (1932). *Archives of Surgery*, 25, 498.
- Krompecher, E. (1918). *Beitrage zur Pathologischen Anatomie*, 64, 165.
- Leider, A.S., Nelson, J.F. and Trodahl, J.N. (1972). *Oral Surgery, Oral Medicine, Oral Pathology*, 33, 559.
- Mori, M., Shimozato, T., Kawano, S., Takeda, N. and Kawakatsu, K. (1972). *Journal of Osaka Univ. Dental School*, 12, 91.
- Papadimitrou, B. (1928). *Beitrage zur Klinischen Chirurgie*, 144, 556.
- Pindborg, J.J. (1960). *Cancer*, 13, 1074.
- Trodahl, J.N. (1972). *Oral Surgery, Oral Medicine, Oral Pathology*, 33, 547.
- Villa, V.G. (1955). *Oral Surgery, Oral Medicine, Oral Pathology*, 8, 123.