

## MANAGEMENT OF DENS INVAGINATUS TYPE II WITH PERIAPICAL LESION: CASE REPORT\*

### *Periapikal Lezyon Gösteren Tip II Dens Invaginatusun Tedavisi: Olgu Sunumu*

İsmail UZUN, Cangül KESKİN, Buğra GÜLER, Özgür ÖZDEMİR

Received: 23/09/2014

Accepted: 22/12/2014

#### ABSTRACT

*Dens invaginatus is a developmental anomaly resulting from epithelial invagination of the tooth crown before calcification. Endodontic treatment of teeth affected by dens invaginatus may be difficult and complex due to aberrant anatomy. Combined orthograde and surgical approaches for successful treatment of dens invaginatus are effective. This report describes the successful treatment and results at the 12-month follow-up of a maxillary lateral incisor showing dens invaginatus type II, a large periapical lesion and an open apex by using combined surgical and endodontic treatment.*

#### ÖZ

*Dens invaginatus diş kronunun kalsifikasyonundan önce epitelyal invajinasyonu ile meydana gelen gelişimsel bir anomalidir. Dens invaginatus tan etkilenen dişlerin endodontik tedavileri atipik anatomileri nedeniyle zor ve karmaşık olabilir. Ortograd ve cerrahi yaklaşımların kombine edilmesi bu vakaların başarılı tedavisinde etkili olmaktadır. Bu olgu sunumunun amacı tip II dens invaginatus, geniş periapikal lezyon ve açık apeksli dişin başarılı kombine cerrahi ve endodontik tedavisi ile 12 aylık takibini sunmaktır.*

**Keywords:** Endodontics; dens in dente

**Anahtar kelimeler:** Endodonti; dens in dente



## Introduction

Dens invaginatus is a developmental anomaly resulting from epithelial invagination into the dental papilla (1). Dens in dente, invaginated odontoma, tooth inclusion and dentoid dente are other terms to describe this anomaly (2). The aetiology of dens invaginatus is not clear; however, trauma, infection, inhibition of specific cells and regulatory factors that promote enamel organ formation have been related to this anomaly (1-3). The prevalence of dens invaginatus ranges between 0.04% and 10% (1, 4); it might affect both deciduous and permanent teeth and occurs most commonly in maxillary lateral teeth. Bilateral occurrence is not an uncommon finding (2). Oehlers classified dens invaginatus into three forms according to the extent of invagination (5). Type I is an enamel-lined minor form occurring within the confines of the crown, not extending beyond the amelocemental junction. In Type II, invagination invades the root but remains confined as a blind sac. Type III is the form in which invagination penetrates through the root, perforating at the apical area and showing a second foramen in the apical or in the periodontal area. Invagination allows entry of irritants into pulp space through a thin hypo-mineralised enamel and dentin layer (6). This irritant penetration causes pulp necrosis, abscess formation, cyst formation, tooth displacement or internal resorption (7). Endodontic therapy of teeth with dens invaginatus may be highly complex due to anatomical challenges. Treatment options include nonsurgical treatment of the main canal and invagination, endodontic surgery, a combination of these techniques, intentional replantation and extraction. This case report describes a successful combined endodontic and surgical treatment of teeth with type II dens invaginatus, immature apex and wide periapical radiolucent lesion along with the clinical and radiological findings at the 12-month follow-up.

## Case report

A 15-year-old female patient, whose medical history was non-contributory, was referred to the OndokuzMayis University Endodontics Department for treatment of her maxillary right lateral incisor. The patient was asymptomatic and her history did not reveal any trauma. Extraoral examination revealed normal soft tissue structures, while the intraoral clinical examination revealed a peg-shaped maxillary right lateral incisor with no discoloration (Figure 1). The tooth was not tender to percussion and palpation tests, exhibited Miller class I mobility and did not respond to electric vitality

(Electric Pulp Tester; Parkell, Farmingdale, NY, USA) and cold tests.

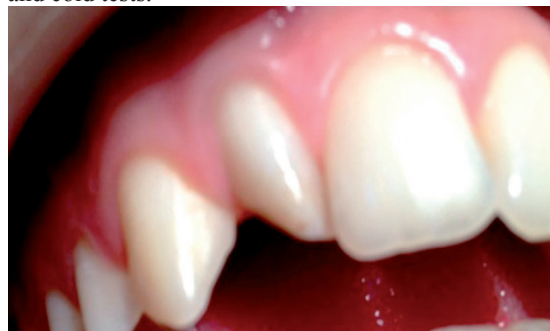
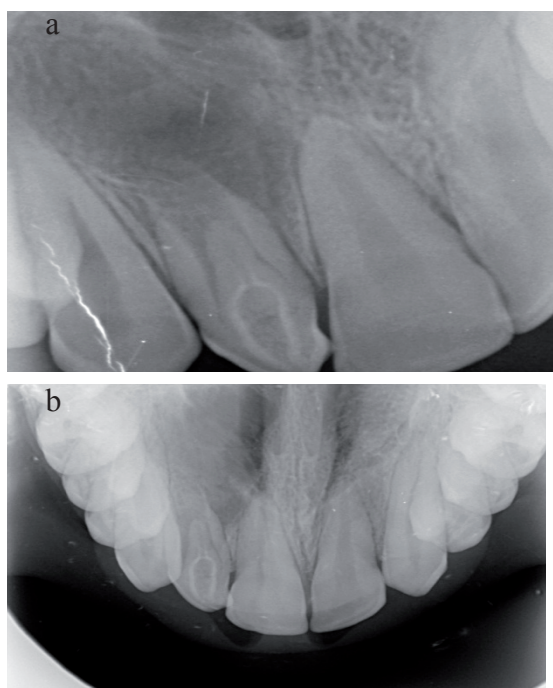


Figure 1. Preoperative clinical appearance of teeth.

Probing depths were within normal limits. Occlusal and periapical radiographs revealed type II dens invaginatus and an immature apex (Figure 2a, 2b). A wide, radiolucent, uniform periapical lesion was also detected. Based on these findings, the patient was diagnosed to have type II dens invaginatus and chronic apical periodontitis with immature apex. Following informed consent, conventional root canal treatment was initiated. An endodontic access cavity was prepared after a rubber dam was applied. Root canal of the invaginated root was detected under magnification (4X). The main canal was explored with a size 10 K-file (DentsplyMaillefer, Baillaigues, Switzerland) through the buccal and palatal sides of the invaginated root. The working length of the invaginated root was determined with a radiological technique. The invaginated canal was prepared to a master apical file size 35 with hand files under copious irrigation with 5.25% NaOCl. Following preparation, the main and invaginated root canals were irrigated with 5.25% NaOCl, distilled water, 17% EDTA, distilled water and 2% chlorhexidine, sequentially. Irrigation solutions was activated with EndoActivator (Dentsply Tulsa Dental Specialties, Tulsa, Oklahoma, USA) using size 15/02 polymer tips for 60 s. Following drying with sterile paper points, the invaginated root canal was obturated with AHPlus (DentsplyDeTrey, Konstanz, Germany) and gutta-percha by the cold lateral compaction technique. Surgical management of the immature apex in a single session was planned, and the access cavity was sealed with temporary filling material (Cavit G;3M ESPE, Germany). Following disinfection of the operation site and administration of local anaesthesia (4% articaine with epinephrine 1/100,000), the full-thickness mucoperiosteal flap was raised. The granulomatous lesion was removed by curettage after apical osteotomy to visualize the lesion (Figure 3).



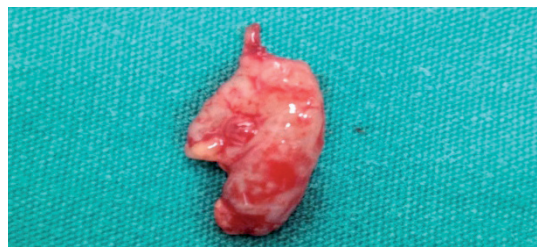**Figure 2.** *a-Periapical radiographic appearance of dens invaginatus, b-Occlusal radiographic appearance of dens invaginatus.*

The main root canal was debrided with 2.5% NaOCl solution and ultrasonic tips (Piezon Endodontic System 401; EMS SA, Switzerland). Retrograde filling was made with an intermediate restorative material (IRM) (DentsplyCaulk, Milford, DE, USA). The position of the IRM was confirmed with periapical radiographs. One week later, the suture was removed. There was no discomfort, and tissue healing had been achieved. The temporary filling material was removed, and the main canal was obturated with Obtura II (Obtura Spartan, Fenton, USA) using the thermoplastic injection technique. The heat setting was adjusted to 200°C, and a 25-gauge needle was used to deliver gutta-percha into the main root canal under stable pressure. The tooth was restored with bulkfill and composite resins (Figure 4). At 12-month follow-up, the patient had no discomfort and the tooth was asymptomatic and functional. Radiographic examination showed healing of the periapical lesion (Figure 5).

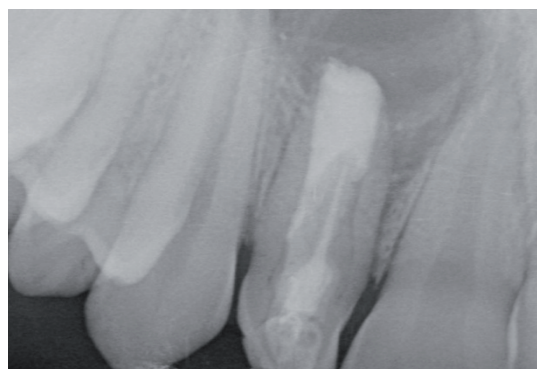### Discussion

Morphological and anatomical variations of the root canal system often complicate diagnosis and treatment procedures (8). It is essential in these cases that clinicians have knowledge about these variations and can develop a treatment plan for successful endodontic treatment.

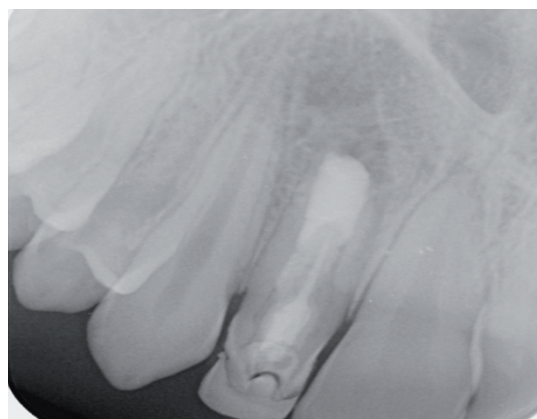Teeth with dens invaginatus are more susceptible to caries due to deep pits and surface irregularities that enable microorganism adhesion and colonization (6).



**Figure 3.** *Appearance of removed granulomatous lesion.*



**Figure 4.** *Postoperative radiographic appearance after root canal filling.*



**Figure 5.** *12-month follow-up radiograph.*

Endodontic treatment of teeth with invagination might be difficult because of residual infected debris and microorganisms that cannot be eliminated by conventional methods.

Dens invaginatus is often diagnosed by distinctive radiographic features in radiological examination. Clinical examination might reveal that the crown has a peg, dilated or conical shape (9). Dens invaginatus might occur bilaterally or in more than two teeth (2).

The present case report of tooth #12 has a peg-shaped crown morphology. Because the patient had extracted her teeth 22 years ago and her old dental records were not found, there is no information about whether the anomaly was unilateral or bilateral. Treatment of teeth with dens invaginatus and a periapical pathology might require alternative treatment planning depending on the anatomical complexity. In the present case report, a surgical single-visit apexification was planned after orthograde root canal treatment of the invaginated root was unable to clean the main root canal through the access cavity. Surgical management also provided curettage of the periapical lesion. Single-visit apexification allowed a hermetic seal of the main root canal system. Teeth with open apex and thin root canal walls complicate conventional endodontic treatment because of an unfavourable crown/root ratio and thin dentinal walls that are susceptible to fractures. Single-visit apexification is used due to the disadvantages of conventional apexification, such as long treatment intervals, risk of re-infection of the root canal system between visits and the negative effects of long-term calcium hydroxide treatment on the fracture resistance of roots (10-12).

In the present case report, an apical barrier was created by a retrograde filling with IRM. Filling of the main root canal with Obtura II was preferred because thermoplastic injection techniques have been shown to be efficient in the obturation of canal irregularities in teeth with dens invaginatus (13).

### Conclusion

Based on the successful findings of the 12-month clinical and radiological follow-up, combined endodontic and surgical management and the use of thermoplastic root canal filling techniques are favourable for the treatment of teeth with dens invaginatus, an immature apex and a wide periapical lesion.

### Source of funding

None declared

### Conflict of interest

None declared

### References

- Alani A, Bishop K. Dens invaginatus. Part I: classification, prevalence and aetiology. *Int Endod J* 2008;41(12):1123-1136.
- Hülsmann M. Dens invaginatus: aetiology, classification, prevalence, diagnosis, and treatment considerations. *Int Endod J* 1997;30(2):79-90.
- Hosey MT, Bedi R. Multiple dens invaginatus in two brothers. *Endod Dent Traumatol* 1996;12(1):44-47.
- Hovland EJ, Block RM. Nonrecognition and subsequent endodontic treatment of dens invaginatus. *J Endod* 1977;3(9):360-362.
- Oehlers FA. Dens invaginatus (dilated composite odontome). I. Variations of the invagination process and associated anterior crown forms. *Oral Surg Oral Med Oral Pathol* 1957;10(11):1204-1218.
- Sauveur G, Roth F, Sobel M, Boucher Y. Surgical treatment of a periradicular lesion on an invaginated maxillary lateral incisor (dens in dente). *Int Endod J* 1997;30(2):145-149.
- Gonçalves A, Gonçalves M, Oliveira DP, Gonçalves N. Dens invaginatus type III: report of a case and 10-year radiographic follow-up. *Int Endod J* 2002;35(10):873-879.
- Wong M. Treatment considerations in a geminated maxillary lateral incisor. *J Endod* 1991;17(4):179-181.
- Subbiya A, Geethapriya N, Pradeepkumar AR, Vivekanandhan P. An unusual type II dens invaginatus with calcified canals in a maxillary lateral incisor- a case report. *J Clin Diagn Res* 2013;7(9):2084-2085.
- D'Arcangelo C, D'Amario M. Use of MTA for orthograde obturation of nonvital teeth with open apices: report of two cases. *Oral Surg Oral Med Oral Pathol Oral Radiol Endod* 2007;104(4):e98-101.
- Andreasen JO, Farik B, Munksgaard EC. Long-term calcium hydroxide as a root canal dressing may increase risk of root fracture. *Dent Traumatol* 2002;18(3):134-137.
- Morse DR, O'Larnic J, Yesilsoy C. Apexification: review of the literature. *Quintessence Int* 1990;21(7):589-598.
- Gutmann JL, Rakusin H. Perspectives on root canal obturation with thermoplasticized injectable gutta-percha. *Int Endod J* 1987;20(6):261-270.

### Corresponding Author:

**İsmail UZUN**

Department of Endodontics

Faculty of Dentistry Ondokuz Mayıs University  
55139-Kurupelit-Samsun/ TURKEY

Phone: +90 362 312 19 19

e-mail: ismail.uzun@omu.edu.tr