

# Rapid spontaneous resolution of traumatic acute subdural hematoma

## Travmatik akut subdural hematomun hızlı spontan rezolüsyonu

Aziz Yıldırım, MD, Specialist in Neurosurgery / Department of Neurosurgery, Bingol State Hospital, Bingol, Turkey;

Veysel Burulday, MD, Specialist in Radiology / Department of Radiology, Bingol State Hospital, Bingol, Turkey;

Alper Karaoğlan, MD, Assistant Professor in Neurosurgery / Department of Neurosurgery, Maltepe University, School of Medicine, Istanbul, Turkey;

Bilal Kelten, MD, Assistant Professor in Neurosurgery / Department of Neurosurgery, Maltepe University, School of Medicine, Istanbul, Turkey;

### ÖZET

Travmatik akut subdural hematoma yaşamı tehdit eden bir durumdur. Akut subdural hematomun birkaç saat içinde spontan rezolüsyonu nadir görülür. Bu olguda travmatik akut subdural hematomun 5 saat içerisinde hızlı rezolüsyonunu ilişkili mekanizmalar eşliğinde tartışarak sunduk.

**Anahtar kelimeler:** akut subdural hematoma, bilgisayarlı tomografi, hızlı rezolüsyon

### ABSTRACT

Traumatic acute subdural hematoma is a life threatening situation. Spontaneous resolution of acute subdural hematoma within a few hours is seen rarely. We present a case of rapid resolution of traumatic acute subdural hematoma with resolution in 5 hours and we discuss the mechanisms related to the resolution of acute subdural hematoma.

**Key words:** acute subdural hematoma, computed tomography, rapid resolution

### INTRODUCTION

Posttraumatic acute subdural hematoma is a neurosurgical emergency condition characterized by % from 60 to 80 mortality rates. Acute subdural hematomas (ASDH) seem to result either from large angular acceleration-deceleration forces that result in rupture of bridging veins over the cerebral surface or from impact, with distortion and failure of deep draining veins (1). According to the thickness of hematoma and the patient's neurological status of acute subdural hematomas can be treated conservatively and followed by serial computed tomography (CT) scanning.

Rapid spontaneous resolution of the hematoma treated conservatively has been reported in the few cases (2-7). In the literature the earliest resolution was reported within 3 hours (5).

A case of spontaneous rapid resolution of ASDH which the CT scan 5 hours after admission showing resolution of subdural hematoma was reported in this study.

### CASE REPORT

An 17 year old male suffered a traumatic head injury

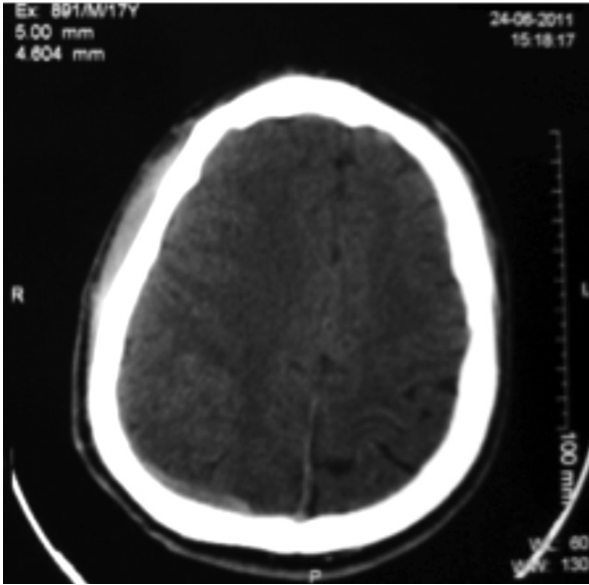
in a traffic accident was transferred to our hospital. On admission, he was lethargic, had a Glasgow Coma Score (GCS) score of 14, pupils were isocoric and reacted normally to light. The CT scan revealed a subdural hematoma with a thickness of 6 mm in the right posterior parietal region (Figure 1). There was no cranial fracture.

The follow-up CT was performed 5 hours after the initial CT. The follow-up CT scan showed complete resolution of acute subdural hematoma (Figure 2).

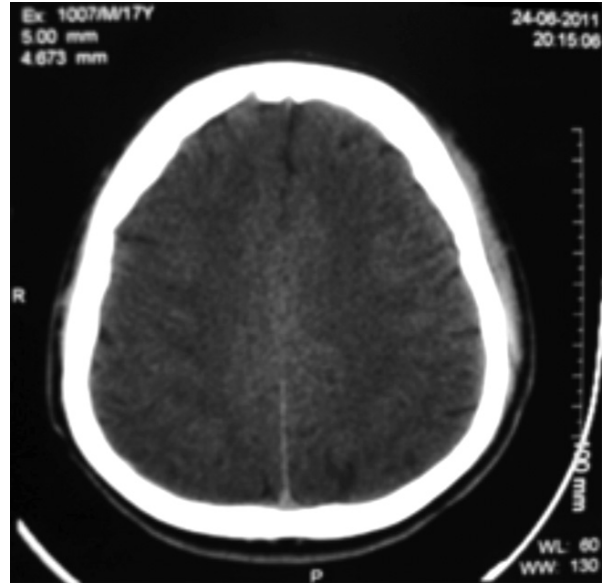
### DISCUSSION

Traumatic acute subdural hematoma is life threatening condition that requires immediate therapeutic intervention (4,8). Spontaneous resolution of traumatic acute subdural hematoma is seen rarely. Because these patients usually undergo an operation on an emergency basis (8).

Several possible mechanisms for the spontaneous resolution of hematoma have been proposed (8,9). Dilution and wash out of the hematoma by cerebrospinal fluid due to tearing of the arachnoid membrane (7,10,11), extracranial redistribution of the hematoma through skull fractures (12), compression and redistribution of the



**Figure 1:** Initial computed tomography (CT) scan showing acute subdural hematoma in the right posteriorparietal region



**Figure 2:** Second CT scan 5 hours after admission showing resolution of subdural hematoma in the right posteriorparietal region

hematoma by acute brain swelling (13), redistribution of the subdural hematoma to the spinal subdural space (14). In addition, the HIV virus that causes acute subdural hematoma due to cerebral atrophy and hematoma with spontaneous resolution has also been reported (15).

Matsuyama et al. reported total disappearance of an acute subdural hematoma with a thickness of a 1.5 cm. They speculated, the absence of cerebral contusion is necessary for spontaneous resolution of ASDH (5). Lee et al. reported the thickness of subdural hematoma above 2.5 cm is an obstacle to total spontaneous resolution of ASDH (8). In our case the thickness of subdural hematoma was 6 mm and we observed complete rapid spontaneous resolution of hematoma.

Several studies have been presented with an even more rapid resolution of ASDH in recent years. Resolution of traumatic acute subdural hematoma showing an earliest resolution was reported within 3 hours (5). In our case, we present this time (time between two CT) within 5 hours.

Case of ASDH (Glasgow Coma Scale (GCS) 11-15, a thin hematoma <1 cm, no focal neurologic deficits) can be safely managed non-surgically with close observation and serial scans (3). These cases should be carefully monitored clinically and radiologically. As we have shown in our study, early spontaneous resolution of traumatic acute subdural hematomas can be seen.

## REFERENCES

- Huang SH, Lee HM, Lin CK, Kwan AL, Hwong SL, Loh JK. Rapid resolution of infantile acute subdural hematoma: a case report. *Kaohsiung J Med Sci* 2005; 21: 291-294.
- Tsui EY, Fai Ma K, Cheung YK, Chan JH, Yuen MK. Rapid spontaneous resolution and redistribution of acute subdural hematoma in a patient with chronic alcoholism: a case report. *Eur J Radiol* 2000;36: 53-57.
- Kırs T, Atabey R, Toplamaoglu H. Rapid resolution of acute subdural hematoma. *Turkish Neurosurgery* 1997; 7: 24-27.
- Mirzai H, Yaldiz C, Eminoglu M, Orguc S. Neurological Picture. Ultra fast resolution of acute post traumatic subdural hematoma. *J Neurol Neurosurg Psychiatry* 2005; 76: 1738.
- Matsuyama T, Shimomura T, Okumura Y, Sakaki T. Rapid resolution of symptomatic acute subdural hematoma: case report. *Surg Neurol* 1997; 48: 193-196.
- Niikawa S, Sugimoto S, Hattori T, Ohkuma A, Kimura T, Shinoda J, et al. Rapid resolution of acute subdural hematoma: report of four cases. *Neurol Med Chir (Tokyo)* 1989; 29: 820-824.
- Duman H, Ziyal İM, Turkmenoglu O, Musluman M, Aydın Y. Early spontaneous resolution of symptomatic acute subdural hematoma: A childhood case. *Türk Nöroşirürji Dergisi* 2001; 11: 222-225.
- Lee CH, Kang DH, Hwang SH, Park IS, Jung JM, Han JW. spontaneous rapid reduction of a large acute subdural hematoma. *J Korean Med Sci* 2009; 24: 1224-1226.
- Watanabe A, Omata T, Kinouchi H. Rapid reduction of acute subdural hematoma and redistribution of hematoma. *Neurol Med Chir (Tokyo)* 2010; 50: 924-927.

10. Inamasu J, Nakamura Y, Saito R, Kuroshima Y, Mayanagi K, Ohba S, Ichikizaki K. Rapid resolution of traumatic acute subdural hematoma by redistribution. *Am J Emerg Med* 2002; 20: 376-377.
11. Polman CH, Gijsbers CJ, Heimans JJ, Ponsen H, Valk J. Rapid spontaneous resolution of an acute subdural hematoma. *Neurosurgery* 1986; 19: 446-448.
12. Kundra S, Kundra R. Extracranial redistribution causing rapid spontaneous resolution of acute subdural hematoma. *Neurol India* 2005; 53: 124.
13. Nagao T, Aoki N, Mizutani H, Kitamura K. Acute subdural hematoma with rapid resolution in infancy: case report. *Neurosurgery* 1986; 19: 465-467.
14. Bartolotti C, Wang H, Fraser K, Lanzino G. Subacute spinal subdural hematoma after spontaneous resolution of cranial subdural hematoma: causal relationship or coincidence?: case report. *J Neurosurg* 2004; 100: 372-374.
15. Cohen JE, Eger K, Montero A, Israel Z. Rapid spontaneous resolution of acute subdural hematoma and HIV related cerebral atrophy: case report. *Surg Neurol* 1998; 50(3): 241-244.