

COMPARISON OF RETROSTERNAL METAL SUPPORT AND ABSORBABLE PLAQUE IN CORRECTION OF PECTUS DEFORMITIES

PEKTUS DEFORMİTELERİNİN DÜZELTİLMESİNDE RETROSTERNAL METAL DESTEK İLE ABSORBABL PLAK KARŞILAŞTIRMASI

Rauf GÖRÜR*, Turgut İŞİTMANGİL*, Akın YILDIZHAN*,
Ali KUTLU**, Kunter BALKANLI***

ABSTRACT

Objective: The most common types of congenital anterior chest wall deformities are pectus excavatum and pectus carinatum. In this paper, we tried to compare correction operations of pectus deformities by using retrosternal metal support and absorbable plaque for sternal fixation.

Materials and Methods: Surgical correction was performed in 38 patients by applying classical Ravitch technique. Twenty nine of these patients had pectus excavatum and 9 of them had pectus carinatum deformity. All patients were male and the mean age was 23.3 (21-28). For sternal fixation, retrosternal metallic support was used in 26 patients and the resorbable copolymer plaque and polymer screw (The Lactosorb™ material) for 12 patients were used with Balkanlı technique.

Results: There was no mortality and morbidity. Retrosternal bar was removed after 3-6 months. Patients were followed up for 24-37 months and no complication was observed except a minimal relapse.

Conclusion: Both of the two techniques can be applied with confidence in the surgical correction of pectus deformities. Retrosternal bar usage is a cheaper technique, however needs closer follow-up for its published complications in the literature and requires sometimes a second operation. Absorbable plaque has the same efficacy. Although more reliable, it is more expensive when compared with the retrosternal bar usage.

Key words: Pectus excavatum, pectus carinatum, retrosternal support, pectus correction

ÖZET

Amaç: Doğumsal anterior göğüs duvarı deformitelerinin en sık görülenleri pektus ekskavatum ve pektus karinatumdur. Bu yazıda pektus deformitelerini düzeltme operasyonlarında sternal tespit amacıyla sternum arkasına metal destek uygulaması ve emilebilir plak kullanımının karşılaştırılmasını yapmayı amaçladık.

Gereç ve Yöntem: Otuz sekiz hastada cerrahi düzeltme klasik Ravitch tekniği kullanılarak yapıldı. Bu hastaların 29'unda pektus ekskavatum ve 9'unda da pektus karinatum deformitesi mevcuttu. Sternum tespiti amacıyla 26 hastada sternum arkasına metalik destek ve 12 hastada ise Balkanlı Tekniği kullanılarak emilebilir ko-polimer plak ve vida (LaktoSorb) kullanıldı.

Bulgular: Mortalite veya morbidite gözlenmedi. Sternum arkasındaki bar 3-6 ay sonra çıkarıldı. Hastalar 24-37 ay izlendi ve hafif dereceli bir nüks dışında hiçbir komplikasyon gözlenmedi.

Sonuç: Pektus deformitelerinin cerrahi düzeltilmesinde her iki teknik de güvenli bir şekilde uygulanabilir. Sternum arkasına bar konulması daha ucuz bir tekniktir, fakat literatürde belirtilen komplikasyonlar açısından daha yakın izlemi ve ikinci bir operasyonu gerektirir. Emilebilir plak aynı etkiye sahiptir. Bunun yanında daha güvenli olmasına rağmen sternum arkasına bar uygulaması ile kıyaslandığında daha pahalı bir yöntemdir.

Anahtar kelimeler: Pektus deformiteleri, retrosternal bar, kopolimer plak

Dergiye geldiği tarih/ Date received: 04.02.2008 - Dergiye kabul edildiği tarih: 07.10.2008

* GATA Haydarpaşa Eğitim Hastanesi, Göğüs Cerrahisi Kliniği, İstanbul
(İletişim kurulacak yazar: araufg@yahoo.com)

** GATA Haydarpaşa Eğitim Hastanesi, Göğüs Hastalıkları Kliniği, İstanbul

*** Gülhane Askeri Tıp Akademisi, Göğüs Cerrahisi Anabilim Dalı, Ankara

INTRODUCTION

Pectus excavatum and pectus carinatum are the most common forms of chest deformities. The characteristic findings of pectus excavatum (funnel chest) are formed by the posterior depression of the sternum and costal cartilages. The first and second ribs and the manubrium are usually in their normal positions, but the lower costal cartilages and the body of the sternum are depressed. Pectus excavatum may occur as frequently as 1 in 300 to 400 live births and it occurs more frequently in boys than girls, by almost a 4:1 ratio (17). Chin (1957) proposed a classification of pectus excavatum deformities. Type I is a localized symmetrical depression with steep walls and angulation of the costal cartilages medial the mamillary line. Type II is a symmetrical but diffuse depression with sloping walls and angulation on, or lateral, to the mamillary line. Type III is an asymmetrical deformity, diffuse or localized, with rotation of the sternum, usually to the left, resulting in depression on none side and protrusion on one side (6).

Pectus carinatum (chicken chest) is anterior protrusion of the sternum and is less frequent than pectus excavatum (17). Lester (1953) divided pectus carinatum into midline and lateral protrusions (6). Midline (chondrosternal) protrusion is a keel-shaped deformity of the sternum and adjacent costal cartilages (6). Lateral (chondrocostal) protrusion is a keel-shaped deformity of the chondrocostal junction of a number of ribs, unilateral or bilateral (6).

Surgical correction should be applied for pectus deformities because of cosmetically and orthopedic, physiological, and psychological problems. In this study it was aimed to compare correction operations of pectus deformities by using retrosternal metal support and absorbable plaque for sternal fixation.

MATERIALS and METHODS

Surgical repair operations were performed in 38 patients with pectus deformities during 4 years in our department between January 2000 and December 2003. Due to the fact that our institution is a military hospital, all of the patients were male with an average age of 23.3 years (21-28). There were pectus excavatum deformities in 29 patients and pectus carinatum deformities in 9 patients. Surgical correction was performed in all patients by applying classical Ravitch technique.

Four (10.5%) out of 38 patients were asymptomatic; 23 patients (60.5%) were psychologically disturbed by the abnormal shape of the chest (feelings of shame, efforts to hide the deformity); 20 patients (52.6%) had exercise limitations; four patients (10.5%) had electrocardiographic changes. In electrocardiographic examination, there were right axis deviation in 2 patients; depressed ST-T segments in 1 patient, and right bundle branch block in 1 patient. In pulmonary function studies, mean vital capacity was 82% (56-104%). The degree of pectus excavatum deformities was graded according to the Hollow index. This is the ratio between the amount of water contained in the chest depression and the body surface area. An index of greater than 50 mL/m² indicates the presence of pectus deformity (2). Severities of pectus excavatum deformities were mild (pectus index <1.2) in four patients, moderate

(1.2£ pectus index £1.3) in 11 patients, and severe (pectus index >1.3) in 14 patients. In this method, deformities were classified as grade I in three patients, grade II in eight patients, grade III in twelve patients, and grade IV in six patients. Types of deformities of all patients were localized and symmetrical in eight patients, diffuse and symmetrical in 19 patients, and asymmetrical in 11 patients.

Following a midline vertical skin incision in front of the sternum, the pectoralis major muscles were separated from the sternum along with portions of the pectoralis minor and serratus anterior bundles in all patients. Deformed costal cartilages were exposed and subperichondrial resection of the deformed involved costal cartilages was achieved by incising the perichondrium. Third through seventh costal cartilages were resected in all patients and the second costal cartilages were removed in six patients. Deformed osseous parts of the ribs were cut and the ribs were reshaped. Then deformed cartilages were reshaped and replaced in the bed of cartilages, and then the perichondrial edges were reapproximated. The attachments of the rectus muscle and intercostals muscle bundles were divided from the sternum with an electrocautery. Sternum was dissected from mediastinum and pleura. One or two anterior wedge osteotomy to sternum was performed above the level of the highest deformed cartilage (generally third cartilage or second cartilage) and the posterior angulation of the sternum, depending on the type of deformity. In patients with carinatum deformities, wedge-shaped cartilagenos fragment which was removed from the deformed cartilage was placed into the osteotomy line of the sternum in order to restore the normal shape of the sternum .

We used retrosternal metallic support (retrosternal bar) in 26 out of 38 patients for sternal fixation since January 1998. Sternum was reshaped and osteotomy line was sutured by vicryl and sternum was supported by metallic bar under the sternum. Retrosternal bar was secured with pericostal non-absorbable

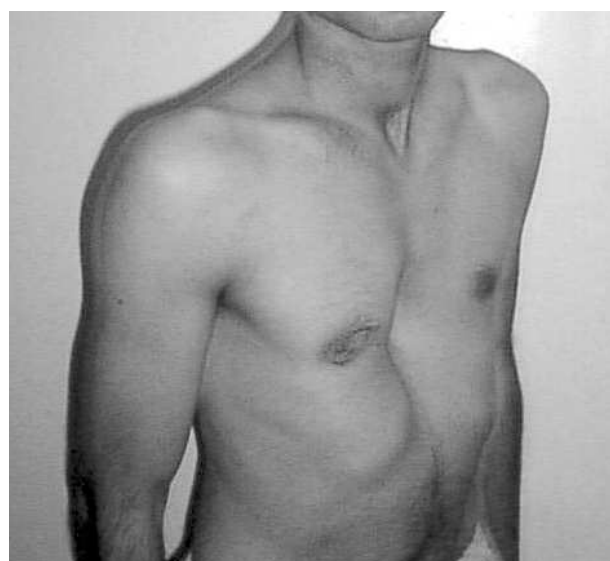

Figure 1: Preoperative photo of a patient with pectus excavatum

Table 1. Clinical characteristics of the patients during operation and in early postoperative period.

	Metallic Support	Absorbable Material
Mean operation time	205 min.	232 min.
Mean drainage time	37 hours	35 hours
Mean drainage amount	560 ml.	580 ml.
Mean hospitalization time	10.1 days	7.8 days
Mean intensive care unit time	2.2 days	2.4 days
Cosmetic result		
unsatisfactory	2	-
good	7	4
excellent	17	8
Mean total cost (approximately)	700 \$	1500 \$

sutures laterally to prevent migration. The retrosternal metal strut was removed by local anaesthesia after 3-6 months. The resorbable copolymer plaque and polymer screw (LactoSorb®) with Balkanlı technique (4) were used in 12 out of 38 patients for sternal fixation since March 2000. Bioab-

sorbable material, which we used, was unique copolymer of poly-L-lactic acid (82%) and poly glycolic acid (18%) and it completely resorbs within one year. In Balkanlı technique, after the osteotomy was carried out, new corrected position was given to the sternum and then copolymer plaque was placed over the sternum on the line of osteotomy. Fixation of copolymer plaque was established with resorbable polymer screws (Figure 1).

In the either technique, a pliable, closed suction drain (Hemo-vacs) was left in the substernal space in all patients and single chest tube was inserted in 8 patients since the parietal pleura had been opened.

RESULTS

There was no perioperative death. Early postoperative complication did not occur in any patients. There was no superficial wound infection or no necrosis because of insufficient sternal vascularisation. No patient required blood transfusion. Pe-

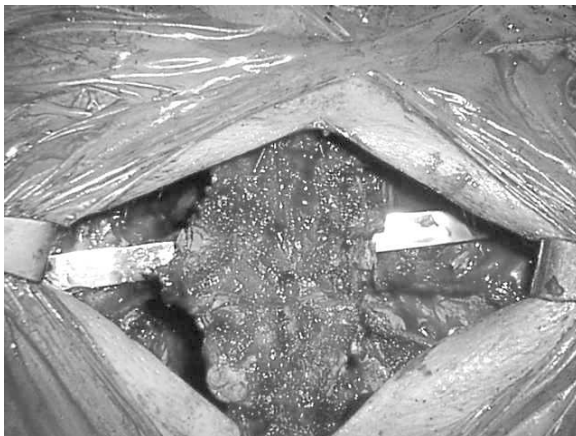

Figure 2: Intraoperative view demonstrating the usage of classical pectus bar during the repair of pectus excavatum deformity

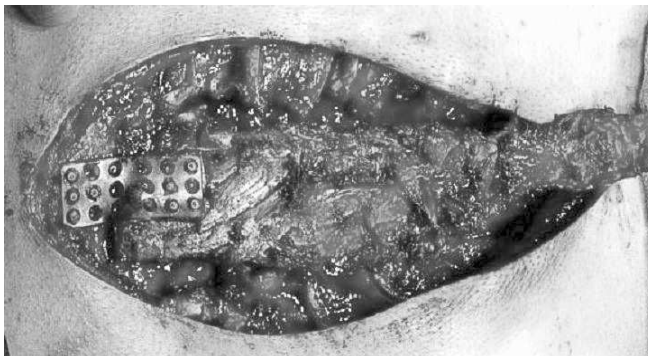


Figure 3: Copolymer plaque was placed over the sternum on the line of osteotomy and fixation of copolymer plaque was established with resorbable polymer screws

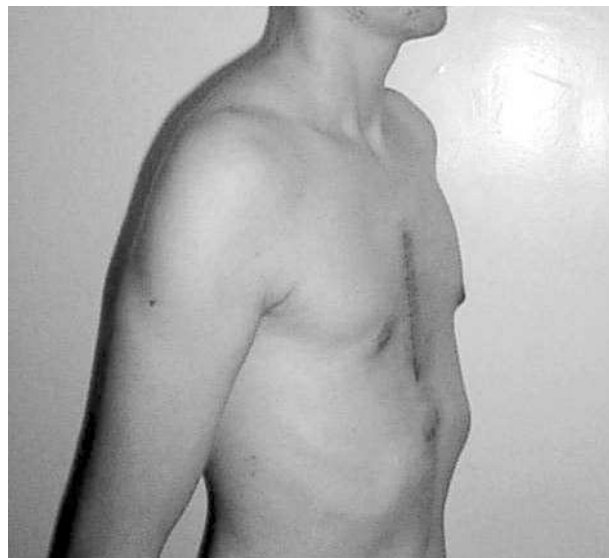


Figure 4: Postoperative photo of a patient with pectus excavatum deformity underwent correction with using lactosorb.

rioperative and postoperative clinical characteristics of the patients are presented in Table 1.

The cosmetic result was unsatisfactory in two patient, good in eleven patients, and excellent in 25 patients. There were no changes in electrocardiographic abnormalities at 6 months after operation. Postoperatively patients were followed up for 24-37 months and no complication was observed except a minimal recurrence of sternal depression which was seen in 3 patients all of whom classical Ravitch technique was performed.

DISCUSSION

The ideal age for pectus repair remains controversial (18). Haller et al. suggested that ideal age for repair was 4 to 6 years, but Lacoquet et al. reported that the optimal age for correction was around the age of 10 years (6,12). All our patients with pectus deformities were male and their ages were 21 to 28 years, because we were working in a military hospital.

A number of different methods for surgical correction of pectus deformities have been reported since the beginning of twentieth century (10). Milder pectus excavatum deformities without symptoms of cardiopulmonary compromise may be reconstructed with solid silicone implants for cosmetic reasons only (7). But most investigators believe that sternal and rib reconstruction in patients with pectus excavatum relieves structural compression of the chest, allows normal growth of the thorax, and prevents pulmonary and cardiac dysfunction (3,10). These methods may be classified into two types: sternal elevation and sternal turnover (10). Sternal elevation technique is more popular than sternal turnover technique (10). To hold the mobilized and elevated sternum in position during healing and to avoid recurrence of the sternal depression after the repair, most surgeons reported some methods of sternal fixation. These methods were Kirschner's wires, sewing of sternum with steel sutures, metal (stainless steel) struts, resin strut, seagull wing prosthesis, Steinman pins, Rehbein splint, a vascularised rib strut, Marlex mesh, bioabsorbable polydioxanone weave and bioabsorbable poly-L-lactide plaque (1,4,5,6,13,14,16,18). We compared the results of these two methods, which we consider to be the safest and the most efficient methods.

Surgical correction of pectus excavatum with the use of a metal pectus bar is a popular method of reconstruction of the anterior thoracic wall, offering excellent cosmetic result (8). Metal bars are cheap, easy to find, and easy to place and extract, but they have some complications (15). These complications are local infection, atelectasis, migration of bar, and bar fracture (8, 15). Our results were very good and there was not any complication in the patients.

Matsui et al. (1994) reported first to use bioabsorbable struts made from poly-L-lactide for the treatment of chest deformity (13). Authors used poly-L-lactide plate for sternal elevation in 33 patients with pectus excavatum deformities and they suggested that this bioabsorbable strut is a promising material for surgical treatment of chest deformities (13). Also Gurkok et al. (2001) proposed to use absorbable copolymer plaque with a new surgical technique (Balkanli) in correction of pectus de-

formities (4). We were using this technique in our department since March 2000. Our results are very good and there is not any complication in the patients.

The most important disadvantage of metal struts is that a second operation usually necessary for removing of metal supports. They may impair the growth of the chest wall if not extracted (13). Bioabsorbable plaque does not impair the growth of the chest wall and do not need to be extracted because is completely absorbed at the end of the first year (4,13). The most important disadvantage of bioabsorbable plaque is that they are more expensive.

Pectus deformities may be repaired with very good cosmetic and physiologic results in both children and adults (19). Similar with other series, 60.5 % of the patients underwent correction due to the evidence of psychological and social doubts in our series. Of these patients, only 7.8 % of them were not fully satisfied from the results due to minimal sternal depression. As our results confirmed once again, cosmetic problems may constitute a major indication for repair of pectus deformity and surgical correction yields favorable results.

CONCLUSION

Sternal fixation methods using retrosternal bar or absorbable plaque are two techniques that can be applied with confidence in the surgical correction of pectus deformities. The results of two techniques were found to be comparable. Retrosternal bar usage is a cheaper technique. However it requires closer follow-up for its published complications as well as a second operation to remove the bar. Absorbable plaque is relatively safer with similar efficacy but it is a more expensive technique. Surgical correction of pectus deformities yields favorable results.

REFERENCES

1. Brooks JP, Tripp HF. Bioabsorbable weave technique for repair of pectus excavatum. *J Thorac Cardiovasc Surg* 2000; 119: 176-178.
2. Dato GMA, Paulis RD, Dato AA, Bassano C, Pepe N, Borioni R, Panero GB. Correction of pectus excavatum with a self-retaining seagull wing prosthesis. *Chest* 1995; 107: 303-306.
3. Fonkalsrud EW, Salman T, Guo W, Gregg JP. Repair of pectus deformities with sternal support. *J Thorac Cardiovasc Surg* 1994; 107: 37-42.
4. Gurkok S, Genc O, Dakak M, Balkanli K. The use of absorbable material in correction of pectus deformities. *Eur J Cardiothorac Surg* 2001; 19: 711-712.
5. Haller JA, Colombani PM, Humphries CT, Azizkhan RG, Loughlin GM. Chest wall constriction after too extensive and too early operations for pectus excavatum. *Ann Thorac Surg* 1996; 61: 1618-1624.
6. Haller JA, Scherer LR, Turner CS, Colombani PM. Evolving management of pectus excavatum based on a single institutional experience of 664 patients. *Ann Surg* 1989; 209: 578-582.
7. Johnson PE. Refining silicone implant correction of pectus excavatum through computed tomography. *Plast Reconstr Surg* 1996; 9: 445-449.

8. Kanegaonkar RG, Dussek JE. Removal of migrating pectus bars by video-assisted thoracoscopy. *Eur J Cardiothorac Surg* 2001; 19: 713-715.
9. Kotoulas C, Papoutsis D, Tsolakis K, Laoutidis G. Surgical repair of pectus excavatum in young adults using the DualMesh 2-mm Gore-Tex. *Interact Cardiovasc Thorac Surg* 2003; 2: 565-568.
10. Kowalewski J, Brocki M, Zoly_ski K. Long term observation in 68 patients operated on for pectus excavatum: Surgical repair of funnel chest. *Ann Thorac Surg* 1999; 67: 821-824.
11. Kubiak R, Habelt S, Hammer J, Häcker FM, Mayr J, Bielek J. Pulmonary function following completion of minimally invasive repair for pectus excavatum (MIRPE). *Eur J Pediatr Surg* 2007;17: 255-260.
12. Lacquet LK, Morshuis WJ, Folgering HT. Long-term results after correction of anterior chest wall deformities. *J Cardiovasc Surg* 1998; 39: 683-688.
13. Matsui T, Kitano M, Nakamura T, Shimizu Y, Hyon SH, Ikada Y. Bioabsorbable struts made from poly-L-lactide and their application for treatment of chest deformity. *J Thorac Cardiovasc Surg* 1994; 108: 162-168.
14. Nakanishi Y, Nakajima T, Sakakibara A, Nishiyama T. A vascularised rib strut technique for funnel chest correction. *Br J Plast Surg* 1992; 45: 364-366.
15. Onursal E, Toker A, Bostanci K, Alpagut U, Tireli E. A complication of pectus excavatum operation: Endomyocardial steel strut. *Ann Thorac Surg* 1999; 68: 1082-1083.
16. Robicsek F. Surgical treatment of pectus excavatum. *Chest Surg Clin N Am* 2000; 10: 277-296.
17. Shamberger RC. Chest wall deformities. In: Shields TW, LoCicero III J, Ponn RB, editors. *General Thoracic Surgery*, 5th ed. Philadelphia: Lippincott Williams and Wilkins, 2000: 535-562.
18. Willekes CL, Backer CL, Mavroudis C. A 26-year review of pectus deformity repairs, including simultaneous intracardiac repair. *Ann Thorac Surg* 1999; 67: 511-518.
19. Fonkalsrud EW, DeUgarte D, Choi E. Repair of pectus excavatum and carinatum deformities in 116 adults. *Ann Surg* 2002; 236: 304-312.