

SIROLIMUS ASSOCIATED INTERSTITIAL PNEUMONITIS IN A RENAL TRANSPLANT PATIENT: IS IT A HYPERSENSITIVITY RESPONSE?

RENAL TRANSPLANTASYON SONRASI SİROLİMUS İLE İLİŞKİLİ İNTERSTİSYEL PNÖMONİ: BİR AŞIRI DUYARLILIK CEVABI MI?

Yaşar ÇALIŞKAN, Sabahat ALIŞIR ECDER, Dilek GÜVEN, Oktay ÖZKAN,
Tevfik ECDER, Aydın TÜRKMEN, Mehmet Şükrü SEVER*

ABSTRACT

Sirolimus is a maintenance immunosuppressive agent after renal transplantation. Interstitial pneumonitis due to sirolimus which had no identified infectious etiology has been recently reported. We describe a case of recurrent sirolimus associated interstitial pneumonitis after renal transplantation, on the basis of its mechanism of action. The diagnosis of sirolimus-associated pulmonary toxicity was made after an exhaustive work-up to exclude infectious causes and other pulmonary disease. Sirolimus discontinuation resulted in clinical and radiologic improvement of interstitial pneumonitis within 2 weeks. The precise etiology underlying sirolimus-induced pneumonitis remains unknown. However, observations in animals and humans indicate that this agent may cause lung injury in selected cases via differential regulation of the Th1/Th2 lymphocyte balance. We thought that bronchoalveolar lavage cell counts may provide some information about the mechanism of sirolimus-induced pneumonitis.

Key words: Interstitial pneumonitis, sirolimus, renal transplantation, immunosuppressive drugs

ÖZET

Sirolimus renal transplantasyon sonrasında idame tedavide kullanılmakta olan bir immunsüpresif ajandır. Herhangi bir infeksiyöz etyolojinin saptanmadığı sirolimusa bağlı interstisyel pnömoni yakın zamanda bildirilmiştir. Renal transplantasyon sonrası sirolimus ile ilişkili rekürren interstisyel pnömoni geçiren bir olguyu, etki mekanizmasını temel alarak tanımladık. Bu vakada, sirolimus ile ilişkili interstisyel pulmoner toksisite tanısı, infeksiyöz nedenleri ve diğer pulmoner hastalıkları dışlamak için yapılan ayrıntılı değerlendirme sonrasında konulmuştur. Sirolimus tedavisinin kesilmesi iki hafta içerisinde interstisyel pnömonide klinik ve radyolojik düzelmeye ile sonuçlanmıştır. Sirolimus ile ilişkili olarak ortaya çıkan interstisyel pnömoninin kesin etyolojisi bilinmemektedir. Bununla birlikte, hayvan ve insanlarda yapılan araştırmalar bu ajanın seçilmiş vakalarda Th1/Th2 lenfosit oranında değişiklikler meydana getirilerek akciğer hasarına neden olabileceğini göstermektedir. Bronkoalveolar lavaj hücre sayımlarının, sirolimus ile ilişkili interstisyel pnömoninin mekanizması ile ilgili bilgi sağlayabileceğine düşünmekteyiz.

Anahtar kelimeler: İnterstisyel pnömoni, sirolimus, renal transplantasyon, immunsüpresif ilaçlar

INTRODUCTION

Sirolimus is a very promising immunosuppressive drug for the maintenance of immunosuppression in the field of organ transplantation that has proved its effectivity to reduce the incidence of acute rejection in renal transplantation recipients (5, 9). Sirolimus interrupts the signal from the IL-2 receptor and the receptors for other cytokines and growth factors (5, 9). It blocks the signal transduction pathway required for the progression of cytokine-stimulated T cells from the G1 into the S phase, thus suppressing interleukin-driven T-cell proliferation (5, 9). However, so-

me instances of interstitial pneumonitis associated with its use have been recently reported (7, 12, 17). In previous reports, the potential pulmonary toxicity of sirolimus due to a capillary leak syndrome was suggested (11,15). In this report, we present a clinical case related to this rare but already confirmed adverse side-effect, which could be overlooked and/or misdiagnosed in immunosuppressed patients. This review aims at defining the sirolimus associated interstitial pneumonitis which had no identified infectious etiology after renal transplantation, on the basis of its mechanism of action.

Date received/Dergiye geldiği tarih: 15.01.2006

* İstanbul University, İstanbul Faculty of Medicine, Department of Intestinal Medicine, İstanbul, Turkey
(Correspondence to: ykcaliskan@yahoo.com)

CASE

A 31-year-old-male kidney transplant patient was transplanted in 1999 with a diagnosis of immunoglobulin A (IgA) nephropathy related end stage renal disease. He was started immunosuppression with cyclosporine, azathioprine, and prednisolone. Because of a slow progressive rise in serum creatinine concentration and daily proteinuria, cyclosporine was switched to sirolimus (6 mg loading followed by 2 mg once daily) on September 2004. The targeted therapeutic blood sirolimus level was 4-12 ng/mL. His other medications were mycophenolate mofetil (MMF), losartan, hydrochlorothiazide and prednisolone 7.5 mg/day. On the 20th day of sirolimus treatment, the patient developed acute nonproductive cough, malaise, fever, and shortness of breath. On examination, body temperature was 38.5°C, blood pressure was 130/80 mmHg, and the heart rate was 92 beats per minute. The physical examination revealed no abnormalities except for pretibial edema. Routine laboratory tests showed marked evidence of inflammation (erythrocyte sedimentation rate (ESR), 91 mm/hour and hsCRP 32.5 mg/L (0-5 mg/L). However, peripheral blood counts indicated normal leukocyte count (6 800 leukocytes per ml) and normocytic anemia, hemoglobin at 10.2 g/dL. The patient had chronic hepatitis B and C, and laboratory tests of liver function were normal except for a modest increment of serum transaminase levels (AST: 55 IU/L, ALT: 62 IU/L). Serum creatinine was 2.4 mg/dL, and proteinuria was 7.2 g/day. Urinalysis revealed no pyuria or hematuria. Diffuse bilateral infiltrates especially involving left lower lobe were seen on the chest radiograph. High resolution computed tomography (HRCT) of the thorax showed consolidation in the left lower lobe and bilateral compression atelectasis in both lower lobes (Fig. 1). Because of suspected pneumonia, ampicillin+sulbactam three times a day was started. At the same time, blood sirolimus level was 7.4 ng/mL. Sirolimus treatment was stopped and the prednisolone dose was increased to 20 mg/day with MMF at a dose of 2 g/day. Within three days, the patient's symptoms improved dramatically. Chest X-ray also showed clearing of the previously described infiltrates and he was given ampicillin+sulbactam treatment for 15 days. Inflammation markers in laboratory tests also improved. Sirolimus treatment (6 mg loading followed by 2 mg once daily) was started again. Two weeks later, he developed a second episode of acute nonproductive cough and shortness of breath with a fever of up to 38°C. Chest X-ray showed infiltrates involving left upper lobe (Fig. 2A). A HRCT of the chest revealed bilateral pleural effusion, compression atelectasis involving both lower lobes and extensive consolidation in the left lower lobe (Fig. 2B). Routine laboratory tests showed marked evidence of inflammation (ESR, 101 mm/hour and hsCRP 106.2 mg/L (0-5 mg/L). However, peripheral blood counts indicated normal leukocyte count (8 100 leukocytes per ml) and hemoglobin level at 12.7 g/dL. Meanwhile, blood sirolimus level was found to be 7.2 ng/mL. A full course of levofloxacin treatment was initiated but clinical deterioration persisted. Gram stain and Ziehl-Nielsen stain for acid-fast bacilli of sputum were found negative. Cultures of sputum were negative for an infection and tuberculin skin test was also negative. The

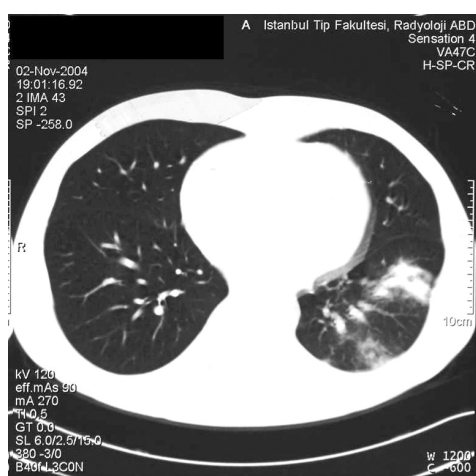


Figure 1. A high resolution computed tomography (HRCT) of thorax showed consolidation in the left lower lobe and bilateral compression atelectasis in both lower lobes.

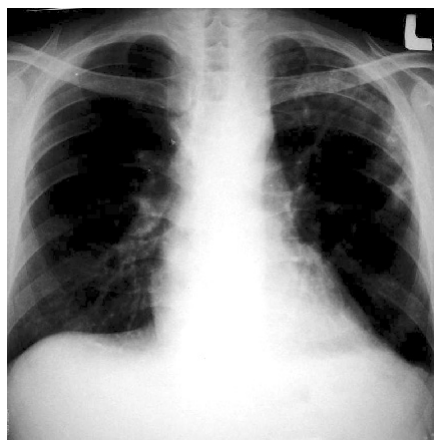


Figure 2A. A chest X-ray showed infiltrates especially involving left upper lobe during the second episode of pneumonitis.

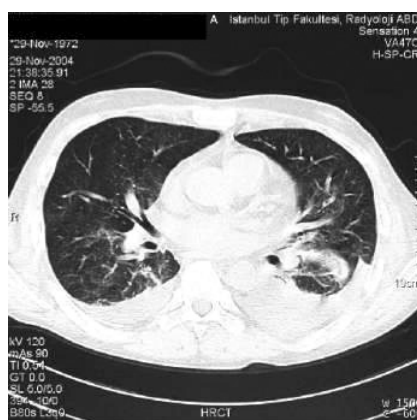

Figure 2B. A HRCT of the chest revealed bilateral pleural effusion, compression atelectasis involving both lower lobes and extensive consolidation in the left lower lobe.

patient refused the performance of bronchoalveolar lavage (BAL) examination. No evidence of an infection that could explain fever and respiratory distress could be found. Finally sirolimus was ceased and in view of the patient's condition, the prednisolone dose was increased to 20 mg/day. Clinical symptoms and laboratory tests started to improve within a couple of days. The chest X-ray 2 weeks later revealed completely clear lung fields.

DISCUSSION

There are several reported cases of interstitial pneumonitis which had no identified infectious etiology and may have been due to sirolimus treatment (7,11,12,15,17). Sirolimus associated interstitial pneumonitis manifests itself usually as a pneumonic illness with symptoms of dyspnea, cough, fatigue, and sometimes fever (7,11,12,15,17). The presentation of our patient seemed to be pneumonia. Although the first episode of pulmonary symptoms may resolve with antimicrobial therapy, we could not find any evidence of an infection in any episodes. Previous reports suggest that sirolimus-induced lung toxicity might be dose-dependent (10). In these reports, blood levels of sirolimus before pneumonitis ranged from 12 to 30 ng/mL (median, 20 ng/mL). Additionally, in contrast to previous reports, the blood sirolimus levels in our patient were not excessive during the episodes of pulmonary symptoms. The patient was not exposed to any other drug that may cause interstitial pneumonitis. Sirolimus discontinuation resulted in clinical and radiological improvement in our patient within 2 weeks. Sirolimus associated interstitial pneumonitis may cause a wide spectrum of plain chest radiographic appearances which can be either transient or permanent. However, in our patient, the infiltrates on chest X-ray appeared and disappeared at the same and in different sites in the lung.

The precise etiology underlying sirolimus-induced pneumonitis remains unknown. However, it has been speculated that sirolimus might expose cryptic pulmonary antigens, triggering a lymphocytic alveolitis and interstitial pneumonitis (10). Recent reports suggested that hypersensitive pneumonitis which is a kind of interstitial pneumonitis in humans, as has been reported in animal models, is a Th1-mediated disease, similar to sarcoidosis, and that development of this disease may be associated with changes in interleukin (IL)-10 production and IL-12R expression by T cell recruited to the lung (19). Therefore, we thought that BAL cell counts may provide some information about the mechanism of sirolimus-induced pneumonitis. However, the performance BAL examination. We felt that it was unethical to force our patient to BAL examination to demonstrate the interstitial pneumonitis and cell counts. Interstitial pneumonitis lesions in patients with sirolimus-induced pneumonitis are characterized by an increased number of CD4+ cells (10, 11). In the literature, BAL was performed in eight patients and most of them were characterized by an increased number of CD4+ cells (11,12,15,17). Flow cytometry performed in 3 cases revealed a 2 to 3:1 ratio of CD4:CD8 T cells (17). In combination with the results of the BAL, Morelon et al (10) concluded that these findings were consistent with a hypersensitivity response.

Sirolimus or another antigen may exaggerate cellular immune response in which the process of T lymphocyte triggering, proliferation, and activation is skewed in the direction of CD4+ Th1 lymphocyte process. Exaggerated Th1 lymphocyte response may result in the accumulation of large numbers activated Th1 cells in the lungs and releasing of mediators. However, if there is any exaggerated Th1 cell response or the trigger for this response in sirolimus associated pneumonitis is still unknown.

In previous reports, sirolimus administration was found to inhibit CD8+ and T cell receptor (TCR) + T more than CD4+ T cells in allogeneic hematopoietic cell transplantation recipients (1, 18). Sirolimus has also been shown to inhibit proliferation of asthmatics' peripheral blood T lymphocytes and also to inhibit allergen-induced proliferation and IL-5 production by peripheral blood mononuclear cells in patients with asthma, suggesting that in patients with asthma, sirolimus might prove efficacious in downregulating the Th2 response (6, 13). A sirolimus analogue named SAR 943 has also been found to have an inhibitory effect on the Th2 cytokines production (4). Conversely, in a graft-versus-host murine model, sirolimus inhibited the production of Th1 but not Th2 cytokines (2). On the other hand, combination therapy with IL-2 and sirolimus has been reported to prevent diabetes development in nonobese diabetic (NOD) mice and this was associated with a decrease in the number of Th1 cells and an increase in Th2 cells (14). This differential regulation of the Th1/Th2 balance by sirolimus probably reflects different effects on different disease mechanisms. However, there are some reports suggesting its intrinsic immunosuppressive potency, its synergistic effect in association with calcineurin inhibitors, and its antiproliferative actions make it of special interest for the prevention and treatment of bronchiolitis obliterans (3, 8). Among a group of 23 lung transplant recipients, Snell et al (16) reported that 4 of 5 patients treated with sirolimus for bronchiolitis obliterans showed stabilization of pulmonary function.

The mechanism underlying sirolimus associated interstitial pneumonitis is still an unknown issue for the transplantation society. However, observations in animals and humans indicate that this agent may cause lung injury in selected cases via differential regulation of the Th1/Th2 balance. Evidence showing the exact effect of sirolimus on cellular immune response and cytokine production is needed. The studies about the effects of sirolimus on pulmonary functions included small sample sizes and suggested different results that limited our ability to draw conclusions. Studies performed with a great number of patients are needed to clarify this issue.

REFERENCES

1. Blenito AI, Furlong T, Martin PJ, Anasetti C, Appelbaum FR, Doney K, Nash RA, Papayannopoulou T, Storb R, Sullivan KM, Witherspoon R, Deeg HJ. Sirolimus (rapamycin) for the treatment of steroid-refractory acute graft-versus-host disease. *Transplantation* 2001; 72: 1924-1929.
2. Blazar BR, Taylor PA, Panoskaltis-Mortari A, Vallera DA. Rapamycin inhibits the generation of graft-versus-host disease and graft-versus-leukemia-causing T cells by interfering with the

- production of Th1 or Th1 cytotoxic cytokines. *J Immunol* 1998; 160: 5355-5365.
3. Cahill BC, Somerville KT, Crompton JA, Parker ST, O'Rourke MK, Stringham JC, Karwande SV. Early experience with sirolimus in lung transplant recipients with chronic allograft rejection. *J Heart Lung Transplant* 2003; 22: 169-176.
 4. Fujitani Y, Trifilieff A. In vivo and in vitro effects of SAR 943, a rapamycin analogue, on airway inflammation and remodeling. *Am J Respir Crit Care Med* 2003; 167: 193-198.
 5. Groth CG, Backman L, Morales JM, Calne R, Kreis H, Lang P, Touraine JL, Claesson K, Campistol JM, Durand D, Wramner L, Brattstrom C, Charpentier B. Sirolimus (rapamycin)-based therapy in human renal transplantation: similar efficacy and different toxicity compared with cyclosporine. Sirolimus European Renal Transplant Study Group. *Transplantation* 1999; 67: 1036-1042.
 6. Haczku A, Alexander A, Brown P, Assoufi B, Li B, Kay AB, Corrigan C. The effect of dexamethasone, cyclosporine, and rapamycin on T-lymphocyte proliferation in vitro: comparison of cells from patients with glucocorticoid-sensitive and glucocorticoid-resistant chronic asthma. *J Allergy Clin Immunol* 1994; 93: 510-519.
 7. Haydar AA, Denton M, West A, Rees J, Goldsmith DJ. Sirolimus-induced pneumonitis: three cases and a review of the literature. *Am J Transplant* 2004; 4: 137-139.
 8. McWilliams TJ, Levvey BJ, Russell PA, Milne DG, Snell GI. Interstitial pneumonitis associated with sirolimus: a dilemma for lung transplantation. *J Heart Lung Transplant* 2003; 22: 210-213.
 9. Morelon E, Mamzer-Bruneel MF, Peraldi MN, Kreis H. Sirolimus: a new promising immunosuppressive drug. Towards a rationale for its use in renal transplantation. *Nephrol Dial Transplant* 2001; 16: 18-20.
 10. Morelon E, Stern M, Israel-Biet D, Correas JM, Danel C, Mamzer-Bruneel MF, Peraldi MN, Kreis H. Characteristics of sirolimus-associated interstitial pneumonitis in renal transplant patients. *Transplantation* 2001; 72: 787-790.
 11. Morelon E, Stern M, Kreis H. Interstitial pneumonitis associated with sirolimus therapy in renal-transplant recipients. *N Engl J Med* 2000; 343: 225-226.
 12. Pham PT, Pham PC, Danovitch GM, Ross DJ, Gritsch HA, Kendrick EA, Singer J, Shah T, Wilkinson AH. Sirolimus-associated pulmonary toxicity. *Transplantation* 2004; 77: 1215-1220.
 13. Powell N, Till S, Bungre J, Corrigan C. The immunomodulatory drugs cyclosporin A, mycophenolate mofetil, and sirolimus (rapamycin) inhibit allergen-induced proliferation and IL-5 production by PBMCs from atopic asthmatic patients. *J Allergy Clin Immunol* 2001; 108: 915-917.
 14. Rabinovitch A, Suarez-Pinzon WL, Shapiro AM, Rajotte RV, Power R. Combination therapy with sirolimus and interleukin-2 prevents spontaneous and recurrent autoimmune diabetes in NOD mice. *Diabetes* 2002; 51: 638-645.
 15. Singer SJ, Tieman R, Sullivan EJ. Interstitial pneumonitis associated with sirolimus therapy in renal-transplant recipients. *N Engl J Med* 2000; 343: 1815-1816.
 16. Snell GI, Levvey BJ, Chin W, Kotsimbos T, Whitford H, Waters KN, Richardson M, Williams TJ. Sirolimus allows renal recovery in lung and heart transplant recipients with chronic renal impairment. *J Heart Lung Transplant* 2002; 21: 540-546.
 17. Vlahakis NE, Rickman OB, Morgenthaler T. Sirolimus-associated diffuse alveolar hemorrhage. *Mayo Clin Proc* 2004; 79: 541-545.
 18. Wu T, Sozen H, Luo B, Heuss N, Kalscheuer H, Lan P, Sutherland DE, Hering BJ, Guo Z. Rapamycin and T cell costimulatory blockade as post-transplant treatment promote fully MHC-mismatched allogeneic bone marrow engraftment under irradiation-free conditioning therapy. *Bone Marrow Transplant* 2002; 29: 949-956.
 19. Yamasaki H, Ando M, Brazer W, Center DM, Cruikshank WW. Polarized type 1 cytokine profile in bronchoalveolar lavage T cells of patients with hypersensitivity pneumonitis. *J Immunol* 1999; 163: 3516-3523.
-