

## The contribution of power Doppler mode of endobronchial ultrasound (EBUS) used in mediastinal and hilar lymphadenopathies in the differentiation of benign and malignant lymph nodes

Mediastinal ve hiler lenfadenopatilerde endobronşiyal ultrason eşliğinde kullanılan power Doppler modunun benign ve malign lenf nodu ayırımına katkısı

Ruşen Uzun<sup>1\*</sup>, Canan Sadullahoğlu<sup>2</sup>

<sup>1</sup> Health Sciences University, Antalya Education and Research Hospital, Department of Pulmonology Antalya, Turkey.

<sup>2</sup> Health Sciences University, Antalya Education and Research Hospital, Department of Pathology, Antalya, Turkey.

### ABSTRACT

**Aim:** The aim of this study was to investigate the contribution of power Doppler mode used in the differentiation of malignant and benign lymph nodes in patients with mediastinal and hilar lymphadenopathies undergoing diagnostic fine needle aspiration under the guidance of convex probe endoscopic ultrasound (EBUS).

**Material and Methods:** Medical files of patients who underwent EBUS between March 2018 and February 2019 were retrospectively analyzed. A total of 143 lymph nodes of 85 patients were included in the study. The demographic characteristics of the patients with a definite diagnosis and EBUS radiological and sonographic characteristics of the sampled lymph nodes were recorded. As a result of the evaluation of mediastinal lymph nodes with EBUS, the sensitivity, specificity, negative and positive predictive values were calculated for power Doppler mode in the detection of malignant lymph nodes.

**Results:** Of a total of 85 patients, 62 (73%) were males and 23 (27%) were females with a mean age of 62±10.4 (range, 37 to 80) years. In the vascular pattern evaluation, 87 (60.8%) lymph nodes were negative and 56 (39.2%) were positive for malignancy. Comparing final diagnoses and vascular pattern analysis results revealed a statistically significant difference between benign and malignant lymph nodes in favor of power Doppler mode under the guidance of EBUS ( $p < 0.01$ ).

**Conclusion:** Convex probe EBUS can identify the first lymph node to be sampled based on sonographic characteristics of lymph nodes and allow simultaneous imaging and transbronchial fine needle aspiration procedures. Therefore, it may shorten the procedural time and reduce the amount of anesthesia to be used.

**Keywords:** Mediastinal lymph node; mediastinal staging; power doppler ultrasonography.

### ÖZ

**Amaç:** Bu çalışma ile konveks prob endobronşiyal ultrasonografi (EBUS) eşliğinde tanısal amaçlı ince iğne aspirasyon yapılan olgularda, power Doppler modunun mediastinal ve hiler lenfadenopatilerde malign ve benign ayırımına katkısı araştırıldı.

**Gereç ve Yöntemler:** Mart 2018 ile Şubat 2019 tarihleri arasında EBUS yapılan olguların tıbbi dosyaları retrospektif olarak incelendi. Toplam 85 olguya ait 143 lenf nodunun örnekleme sonuçları çalışmaya dahil edildi. Kesin tanısı olan olguların demografik özellikleri, örneklenen lenf bezlerinin EBUS'daki radyolojik ve sonografik özellikleri kayıt edildi. Mediastinal lenf nodlarının EBUS ile değerlendirilmesi sonucunda power Doppler modunun malign lenf nodu belirlemedeki duyarlılığı, özgülüğü, negatif ve pozitif prediktif değeri hesaplandı.

**Bulgular:** Çalışmaya dahil edilen 85 hastanın 62'si (%73) erkek ve 23'ü (%27) kadın olup, yaş ortalaması 62±10,4 (dağılım: 37-80) yıl idi. Vasküler patern değerlendirilmesi sonucunda malignite açısından negatif lenf nodu sayısı 87 (%60,8) iken, pozitif olarak değerlendirilen lenf nodu sayısı 56 (%39,2) olarak saptandı. Kesin tanılar ile vasküler patern analizi karşılaştırıldığında, EBUS eşliğinde kullanılan power Doppler modunun benign ve malign lenf nodu ayırımına katkısı istatistiksel olarak anlamlı bulundu ( $p < 0,01$ ).

**Sonuç:** Konveks prob EBUS, eş zamanlı görüntülemeye ve transbronşiyal ince iğne aspirasyon uygulamalarına olanak sağlamasının yanı sıra, lenf nodlarının sonografik özelliklerini tanımlayarak ilk örneklenecek lenf nodunu tespit edebilir. Bu da, işlem süresinin kısalmasını ve hastanın alacağı anestezi miktarının azalmasını sağlayabilir.

**Anahtar Kelimeler:** Mediastinal lenf nodu; mediastinal evreleme; power Doppler ultrasonografi.

Received: 13:10.2019 Accepted: 03.01.2020 Published (Online):02.03.2020

\***Corresponding Authors:** Ruşen Uzun. Health Sciences University, Antalya Education and Research Hospital, Department of Pulmonology Antalya, Turkey. Phone: +905306066070 e-mail: uzunrusen07@gmail.com

ORCID: 0000-0001-6575-5066

**To cited:** Uzun R, Sadullahoğlu C. The contribution of power Doppler mode of endobronchial ultrasound (EBUS) used in mediastinal and hilar lymphadenopathies in the differentiation of benign and malignant lymph nodes. Acta Med. Alanya 2020;4(1):37-42. doi:10.30565/medalanya.632623

## INTRODUCTION

**T**ransbronchial needle aspiration under the endobronchial ultrasound guidance (EBUS-TBNA) is a safe, minimally invasive procedure which can be applied under local anesthesia with a high diagnostic rate in the diagnosis and/or grading of lung cancer (1). Materials for histological and cytological evaluation can be obtained from mediastinal and hilar lymph nodes with EBUS-TBNA (2). In addition to lung cancer, the effectiveness of this modality has been shown in the diagnosis of sarcoidosis, tuberculosis, and lymphoma (3, 4).

During the EBUS procedure, the sonographic characteristics of lymph nodes can be evaluated using B mode. The lymph node diameter, shape, borders, echogenicity, central hilar structure, and necrosis can be evaluated using this mode (1). The pathological lymph node can be identified and selected initially, and a sample can be, then, taken. Therefore, EBUS-TBNA is expected to shorten the procedural time (5).

Ultrasonography (USG) is an examination made on the basis of the difference in the amplitude of sound waves. Doppler USG is an imaging modality which uses high-frequency sound waves. When a high frequency sound wave encounters a moving structure such as blood flow within a vessel, the reflected sound wave returns at a different frequency. The returning sound waves can be transformed to an audible signal, which is known as the Doppler effect (6).

There are two types of EBUS device, namely radial and convex probe. Radial probe EBUS (RP-EBUS) using high frequency (20 MHz) can be used to guide transbronchial needle aspiration to determine the depth of bronchial wall invasion in early stage bronchial cancers, to visualize tumor invasion, and to facilitate the diagnosis of lesions with peripheral localization. Convex probe EBUS (CP-EBUS) is used at low frequency (7.5 MHz) for the diagnosis of granulomatous diseases such as sarcoidosis and tuberculosis, for mediastinal grading in lung cancer, and to identify mediastinal masses and diseases (7).

With the effect of angiogenetic factors in neovascularization, a peripheral or mixed

bleeding pattern (central and peripheral) occurs in malignant lymph nodes. These flows, which are elevated compared to benign lymph nodes, can be determined using power Doppler mode (8). By measuring the vascularity of lymph nodes in various organs with power Doppler mode, it can be used in the differentiation of metastatic and non-metastatic lymph nodes (9).

In the present study, we aimed to investigate the contribution of power Doppler mode in the differentiation of mediastinal and hilar lymph nodes in patients undergoing CP-EBUS for diagnostic purposes.

## MATERIAL and METHODS

### Study Population

This retrospective study was conducted at thoracic diseases outpatient clinic of xxx Training and Research Hospital between 1st March, 2018 and 28th February, 2019. Approval for this study was granted by the Clinical Research Ethics Committee of Antalya University Training and Research Hospital (No. 9/13, Date: 14.03.2019). A written informed consent was obtained from each patient. The study was conducted in accordance with the principles of the Declaration of Helsinki.

Medical files of patients who underwent CP-EBUS procedure for diagnosis and/or grading were retrospectively analyzed. Throughout the study period, 160 lymph nodes were sampled from 96 patients. A total of 17 lymph nodes of 11 patients were excluded from the study due to the following reasons: lost-to-follow-up, having a non-diagnostic cytology diagnosis, or having lymphoma and malignant tumor metastasis other than the lungs based on the clinical and pathology examination results. Finally, a total of 143 lymph node samples from 85 patients were included in the study. Demographic data including age and sex were collected from the patient records, and the mediastinal distribution of the lymph nodes taken for biopsy and the pathological final diagnoses were noted.

In addition, the lymph node dimensions were determined on computed tomography (CT), and the sonographic characteristics of the lymph nodes and vascular pattern distribution from video

recordings of the procedure. According to the pathological final diagnosis, the effectiveness of the power Doppler USG in the differentiation of benign and malignant lesions was evaluated.

#### Radiological evaluation

Contrast-enhanced thoracic CT was performed in all patients. The EBUS-TBNA procedure was applied to the patients with a short axis of  $\geq 10$  mm in mediastinal-hilar lymph nodes on CT.

#### EBUS-TBNA procedure

All EBUS-TBNA procedures were performed in the operating theatre under conscious sedation (midazolam+propofol), using a Fujinon EBUS device (7.5mhz EB-530US/Sonart SU-1, Tokyo, Japan). Systematic inspection of mediastinal, hilar, and interlobar lymph nodes (2R, 4R, 10R, 11R, 7, 11L, 10L, 4L, 2L, etc.) was performed using EBUS. Nodal sampling from N3 to N2 and then to N1 was performed. (10,11). Identification of mediastinal lymph nodes was made according to the International Association for the Study of Lung Cancer (IASLC) criteria (12). At least two lymph node stations of all cases were sampled and at least three samples were taken for each lymph node.

#### Lymph node evaluation

The EBUS video images of the patients were retrospectively examined by two experienced thoracic diseases specialists. During the evaluation, the size of the lymph node, shape, borders, echogenicity, central hilar structure, and presence of necrosis were examined. Vascularity of the lymph node from the power Doppler mode recording was graded as defined in the literature (13). Accordingly, the grading was as follows: Grade 0, no blood flow; Grade 1, vascularity toward the center of the lymph node; Grade 2, visualization of two or three blood vessels in the form of a point, rod or long line; Grade 3, visualization of more than four blood vessels in point, rod, or line form (Figure 1). Lymph nodes with a vascular pattern of Grade 0-1 were considered negative and those of Grade 2-3 positive for malignancy.

#### Pathological evaluation

The part of the cytological material obtained

was prepared by the cytopathologist as smear preparations stained with the Diff-Quik for rapid evaluation of each patient. The remaining material was placed in a box containing cell protective solution (10% formaldehyde) for the formation of cell block. As a result of the cytopathological evaluation, the diagnoses of the patients were reported as i) non-diagnostic cytology, ii) benign cytology, and iii) malignant cytology (a-adenocarcinoma [Figure 2], b-squamous cell carcinoma [SCC], c-carcinoma other than small cell, unclassified, d-small cell carcinoma).

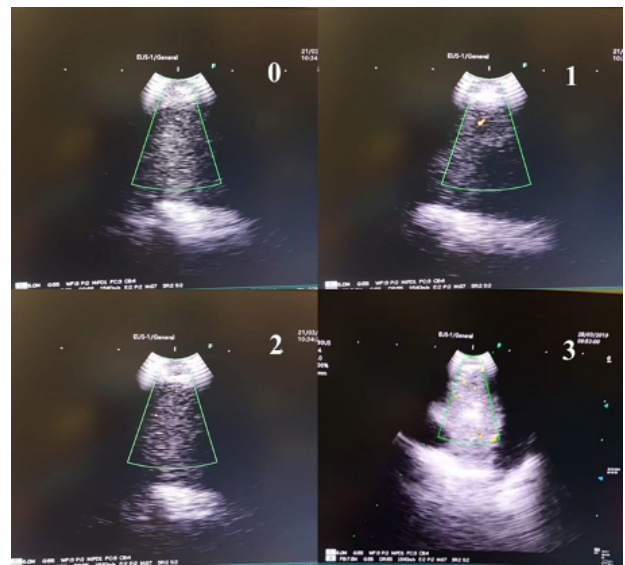


Figure 1. Grading according to vascularity of the lymph node.

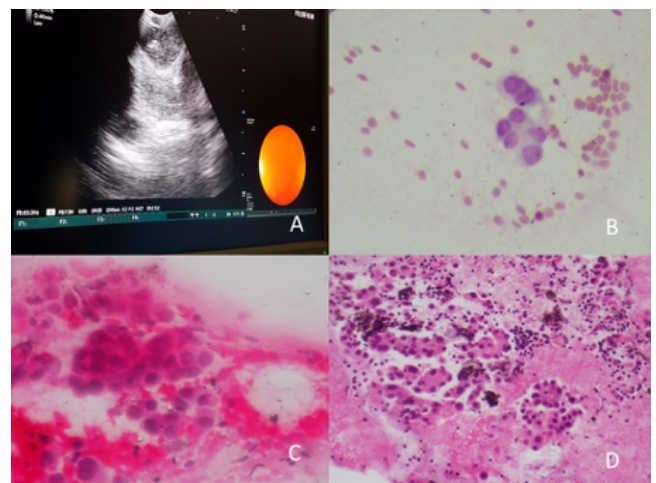


Figure 2. Lung adenocarcinoma: A-Vascular pattern is grade 0. B-C-Tumor cells with nuclear contour irregularity in smear preparations.(Giemsa, x400 and H&E, x400). D-Tumor cells forming adenoid structures in cell block (H&E, x200).

#### Patient follow-up

Lymph nodes were considered benign in cases where tumoral cells were not detected on EBUS-TBNA and confirmed histopathologically with lymph node dissection, or where no disease progression was observed clinically and radiologically within the past six months of clinical follow-up at least. Lymph nodes were considered malignant based on the visualization of the presence of tumoral cells on EBUS-TBNA or based on histological results with surgical excision.

### Statistical Analysis

Statistical analysis was performed using the SPSS version 22.0 software (IBM Corp., Armonk, NY, USA). Descriptive data were expressed in mean ± standard deviation, median (min-max), or number and percentage. For the comparison of definitive diagnostic rates of the groups with vascular pattern analysis, the chi-square test was used. To analyze the differences in the measurement values according to the groups of definitive diagnoses and to examine the vascular pattern analysis of the lymph node diameter measurements, the t-test was applied. Sensitivity, specificity, negative predictive value (NPV), positive predictive value (PPV), and accuracy were calculated with standard methods. A p value of <0.05 was considered statistically significant.

### RESULTS

Of a total of 85 patients, 62 (73%) were males and 23 (27%) were females with a mean age of 62±10.4 (range, 37 to 80) years. Of 143 lymph nodes sampled, 75 (52.4%) were benign and 68 (47.6%) were malignant. The diagnosis of seven of benign lymph nodes was confirmed with mediastinoscopy, while the others were accepted as benign after a six-month clinical and radiological follow-up.

The sampling frequency of the lymph node stations was 3.5% from right upper paratracheal (2R), 0.7% from retrotracheal (3P), 37.8% from right lower paratracheal (4R), 4.2% from left lower paratracheal (4L), 30.8% from subcarinal (7), 8.4% from right hilar (10R), 5.6% from right interlobar (11R), and 9.1% from left interlobar (11L). The mean lymph node diameter was measured as 18.54±7.88 mm on CT and 19.52±7.89 mm sonographically. Lymph node diameters and pathological diagnoses of the sampled lymph

node stations are summarized in Table 1.

Table 1. The diameters and pathology diagnoses of sampled lymph node stations

		n	%
Lymph node stations	2R	5	3.5
	3P	1	0.7
	4R	54	37.8
	4L	6	4.2
	7	44	30.8
	10R	12	8.4
	11R	8	5.6
	11L	13	9.1
Lymph node diameter		BT	EBUS
Mean (mm)		18.54±7.88	19.52±7.89
Pathology diagnosis		n	%
Adenocarcinoma		30	21
SCC		12	8.4
NSCLC-unclassified		12	8.4
SCLC		14	9.8
Benign		75	52.4

Data are given in number and percentage, unless otherwise stated. SCC: squamous cell carcinoma; SCLC: small cell lung carcinoma; NSCLC: non-small cell lung carcinoma; CT: computed tomography; EBUS: endobronchial ultrasonography

In the grading of the lymph nodes, 32 (22.4%) were reported as Grade 0, 55 (38.4%) as Grade 1, 44 (30.7%) as Grade 2, and 12 (8.5%) as Grade 3. In the vascular pattern evaluation, 84% of the lymph nodes diagnosed as benign were determined with a negative (Grade 0-1) vascular pattern, while 64.7% of the malignant lymph nodes were determined with a positive vascular pattern (Grade 2-3) (Table 2). The differentiation of the benign and malignant lymph nodes with vascular pattern analysis was found to be statistically significant (p<0.01). As a result of the evaluation of the mediastinal lymph nodes with CP-EBUS using the power Doppler mode, the sensitivity, specificity, NPV, PPV, and diagnostic accuracy rates of the identification of malignant lymph nodes were 64.7%, 84.0%, 72.4%, 78.6%, and 74.8%, respectively.

There was a significant correlation between the vascular pattern analysis of the patients and the EBUS diagnosis subgroups. Among the patients with a benign diagnosis, the vascular pattern was Grade 0-1 in 84% and Grade 2 in 16%. In the patients with a malignant diagnosis, subtype analysis revealed Grade 2-3 lung adenocarcinoma

in 50%, Grade 2-3 small-cell lung cancer (SCLC) in 71.4%, and Grade 2-3 SCC in 83.3% of the patients. A total of 75% of lymph nodes were Grade 2-3 histological subtype of unclassified non-small cell lung cancer (NSCLC, unclassified) (chi-square: 64.20, p=0.01, p<0.05) (Table 3).

Table 2. Grading of vascular patterns and definitive diagnoses

		Definitive diagnosis		X <sup>2</sup>	p
Vascular pattern		Benign (n=75)	Malignant (n=68)		
Grade 0-1 (n=87)	n	63	24	35.51	0.01
	%	84.0%	35.3%		
Grade 2-3 (n=56)	n	12	44		
	%	16.0%	64.7%		

Data are given in number and percentage, unless otherwise stated.

Table 3. Correlation analysis results

VP		Tumor subtypes				X <sup>2</sup>	p
		LA (n=30)	NSCLC unclassified (n=12)	SCLC (n=14)	SCC (n=12)		
Grade 0-1	n	15	3	4	2	15.29	0.01
	%	50%	25%	28.6%	16.7%		
Grade 2-3	n	15	9	10	10		
	%	50%	75%	71.4%	83.3%		

Data are given in number and percentage, unless otherwise stated. VP: vascular pattern; LA: lung adenocarcinoma; SCC: squamous cell carcinoma; SCLC: small cell lung carcinoma; NSCLC: non-small cell lung carcinoma.

## DISCUSSION

In the present study, we evaluated the diagnostic value of power Doppler mode in the differentiation of mediastinal and hilar lymph nodes in patients undergoing CP-EBUS. The results of the study showed that vascular pattern analysis with power Doppler mode was statistically significantly effective in the identification of malignant lymph nodes.

The advent of EBUS at the beginning of the 21st century has dramatically changed the field of thoracic medicine. Later on, EBUS-TBNA has rapidly become the mainstay for the staging of lung cancer and for the diagnosis of mediastinal and hilar lymphadenopathies (1). Owing to the properties of power Doppler mode integrated into the EBUS devices, the vascularity of lymph nodes can be evaluated during the procedure.

The USG Doppler mode findings of malignant

tumors are different from those of benign tumors (14) and it has been shown that these findings can be used to differentiate metastatic and non-metastatic lymph nodes in patients with malignant disease (15). In our study, 143 lymph nodes were sampled and 75 (52.4%) were found to be benign, while 68 (47.6%) were malignant. The most common mediastinal lymph node stations sampled were the right lower paratracheal (37.8%) and subcarinal (30.8%) lymph node stations. In a retrospective study of 1,061 lymph nodes, Fujiwara et al. (1) reported the frequency of sampling from the right lower paratracheal and subcarinal lymph node stations to be 31.5% and 27.1%, respectively. These results are consistent with our findings. More frequent sampling from the right lower paratracheal and subcarinal lymph node stations can be attributed to the ease of sampling from these locations with EBUS and that they are more often involved in benign diseases such as sarcoidosis and tuberculosis.

The lymph nodes in the current study were found to be Grade 0 in 32 (22.4%), Grade 1 in 55 (38.4%), Grade 2 in 44 (30.7%), and Grade 3 in 12 (8.5%) cases. According to the vascular pattern analysis, 84% of 75 lymph nodes diagnosed as benign were negative and 64.7% of 68 lymph nodes diagnosed as malignant were positive (p<0.01). In a study, Nakajima et al. (13) evaluated 173 lymph nodes and defined Grade 0-1 vascular pattern as negative and Grade 2-3 as positive for malignancy. In the CP-EBUS evaluation, sensitivity was found to be 87.7%, specificity to be 69.6%, NPV to be 71.7%, PPV to be 86.5%, and diagnostic accuracy to be 78% for the identification of malignant lymph nodes. In another study by Demirci et al. (16), sensitivity was 83.2%, specificity was 66.7%, NPV was 69.7%, PPV was 82.3%, and diagnostic accuracy was 74% for the identification of malignant lymph nodes. Based on the evaluation of 143 lymph nodes of 85 patients in the current study, we found a sensitivity of 64.7%, a specificity of 84%, a NPV of 72.4%, a PPV of 78.6%, and a diagnostic accuracy of 74.8%, consistent with previous findings. However, relatively low sensitivity rates in our study can be explained by the retrospective nature of the study and subjective analysis of video images which might have increased the assessment bias.

To the best of our knowledge, there is a very limited number of studies in the literature using the vascular pattern analysis with EBUS (13, 16). In the present study, beyond the scope of previous studies, we also examined the relationship between lung cancer tumor subtypes and vascular pattern analysis of lymph nodes diagnosed as malignant. The vascular pattern analysis was negative in 50% of malignant lymph nodes of adenocarcinoma subtype. In the other tumor subtypes, the vascular pattern analysis result was determined as positive in 71.4% of SCLC lymph nodes and in 83.3% of those diagnosed with SCC. Those with Grade 2-3 vascular pattern were considered positive in the current study, and this method was found to be more valuable in cases diagnosed with SCLC and SCC.

Nonetheless, there are some limitations to this study. The main limitations include its retrospective nature, relatively low number of lymph nodes sampled, and probability of subjective bias in the evaluation of the EBUS Doppler mode video images.

## CONCLUSION

In conclusion, the vascular pattern of lymph nodes can be accurately measured by EBUS using the Doppler mode in patients with lung malignancies. The sampling of lymph nodes with a greater vascularity pattern during the procedure would not only shorten the duration of procedures, but also reduce the amount of anesthesia to be administered. However, further large-scale, prospective studies are needed to establish a definite conclusion.

**Conflict of Interest:** The authors have no conflict of interest to declare.

**Financial Disclosure:** The authors declare that this study has received no financial support.

## REFERENCES

1. Fujiwara T, Yasufuku K, Nakajima T, Chiyo M, Yoshida S, Suzuki S, et al. The utility of sonographic features during endobronchial ultrasound-guided transbronchial needle aspiration for lymph node staging in patients with lung cancer: a standard endobronchial ultrasound image classification system. *Chest*. 2010;138(3):641-7. PMID: 20382710
2. Nakajima T, Yasufuku K, Iyoda A, Yoshida S, Suzuki M, Sekine Y, et al. The evaluation of lymph node metastasis by endobronchial ultrasound-guided transbronchial needle aspiration: crucial for selection of surgical candidates with metastatic lung tumors. *J Thorac Cardiovasc Surg*. 2007;134( 6 ):1485-90. PMID: 18023670
3. Vaidya PJ, Kate AH, Chhajed PN. Endobronchial ultrasound-guided transbronchial needle aspiration: the standard of care for evaluation of mediastinal and hilar lymphadenopathy. *J Cancer Res Ther*. 2013; 9(4):549-51. PMID: 24518694
4. Steinfurt DP, Conron M, Tsui A, Pasricha SR, Renwick WE, Antippa P, et al. Endobronchial ultrasound-guided transbronchial needle aspiration for the evaluation of suspected lymphoma. *J Thorac Oncol*. 2010;5(6):804-9. PMID: 20521347
5. Alici IO, Yılmaz DN, Yılmaz A, Karakaya J, Özyaydin E. The sonographic features of malignant mediastinal lymph nodes and a proposal for an algorithmic approach for sampling during endobronchial ultrasound. *Clin Respir J*. 2016;10(5):606-13. PMID: 25619495
6. Taş E, Çuhali D, Gürsel AO. The Comparison of the Diagnostic Values of Fine Needle Aspiration Biopsy and Color Doppler Ultrasonography in Neck Masses (Prospective Study). *KBB ve BBC Dergisi*. 2007;15(2):60-4.
7. Vaidya PJ, Kate AH, Yasufuku K, Chhajed PN. Endobronchial ultrasound-guided transbronchial needle aspiration in lung cancer diagnosis and staging. *Expert Rev Respir Med*. 2015;9(1):45-53. PMID: 25496515
8. Na DG, Lim HK, Byun HS, Kim HD, Ko YH, Baek JH. Differential diagnosis of cervical lymphadenopathy: usefulness of color Doppler sonography. *AJR Am J Roentgenol*. 1997;168(5):1311-6. PMID: 9129432
9. Ayata Z, Apaydın M, Varer M, Sarsılmaz A, Çallı Ç, Rezanko T. Differential diagnosis in cervical lymphadenopathies: efficacy of B-mode, color and power Doppler ultrasonography. *Kulak Burun Bogaz İhtis Derg* 2009;19(4):173-78.
10. Dettlerbeck F, Puchalski J, Rubinowitz A, Cheng D. Classification of the thoroughness of mediastinal staging of lung cancer. *Chest*. 2010;137(2):436-42.
11. Vilmann P, Clementsen PF, Colella S, Siemsen M, De Leyn P, Dumonceau JM et al. Combined endobronchial and oesophageal endoscopy for the diagnosis and staging of lung cancer. European Society of Gastrointestinal Endoscopy (ESGE) Guideline, in cooperation with the European Respiratory Society (ERS) and the European Society of Thoracic Surgeons (ESTS). *Eur Respir J*. 2015;46(1):40-60. PMID: 26034128
12. Goldstraw P, Chansky K, Crowley J, Rami-Porta R, Asamura H, Eberhardt WE et al. The IASLC Lung Cancer Staging Project: proposals for the revision of the TNM stage groupings in the forthcoming (eighth) edition of the TNM classification for lung cancer. *J Thorac Oncol*. 2016;11(1):39-51. PMID: 26762738
13. Nakajima T, Anayama T, Shingyoji M, Kimura H, Yoshino I, Yasufuku K. Vascular image patterns of lymph nodes for the prediction of metastatic disease during EBUS-TBNA for mediastinal staging of lung cancer. *J Thorac Oncol*. 2012;7(6):1009-14. PMID: 22525556
14. Zhou J, Zhu SY, Liu RC, Luo F, Shu DX. Vascularity index of laryngeal cancer derived from 3-D ultrasound: a predicting factor for the in vivo assessment of cervical lymph node status. *Ultrasound Med Biol*. 2009;35(10):1596-600. PMID: 19632759
15. Voit C, Van Akkooi AC, Schäfer-Hesterberg G, Schoengen A, Kowalczyk K, Roewert JC, et al. Ultrasound morphology criteria predict metastatic disease of the sentinel nodes in patients with melanoma. *J Clin Oncol*. 2010;28 (5):847-52. PMID: 20065175
16. Demirci NY, Öztürk C. The value of the vascular imaging pattern assessed by the doppler mode during EBUS-TBNA in differentiating between benign and malignant lymph nodes. *Izmir Göğüs Hastanesi Dergisi*, 2017;31(2):87-92.